

Vincent Walker and Roger Beadle\*

Royal Stoke Hospital, University Hospitals North Midlands NHS Trust, Newcastle Road, Stoke on Trent, ST4 6QG, United Kingdom

**Dates:** Received: January 05, 2015; Accepted: February 28, 2015; **Published:** March 01, 2015

\***Corresponding author:** Dr. Roger Beadle, MBBS, PhD, MRCP, Consultant Cardiologist, Royal Stoke Hospital, University Hospitals North Midlands NHS Trust, Newcastle Road, Stoke on Trent, ST4 6QG, United Kingdom, Tel: 0044+7766904516; E-mail: rogerbeadle@hotmail.com

[www.peertechz.com](http://www.peertechz.com)

**Keywords:** Implantable loop recorder; Cardiac pacing; Home monitoring

**ISSN:** 2455-2976

## Case Report

# Home Monitoring of Implantable Remote Loop Recorders Expedites Intervention

### Abstract

A 70 year old woman had a Reveal LINQ (Medtronic, Minneapolis, MN, USA) implantable loop recorder (ILR) implanted to investigate a cardiac cause of syncope. Due to the ability of this device to utilise home monitoring, early detection of a significant bradycardia allowed early intervention with permanent pacing before any further episodes of syncope occurred. This highlights the utility of home monitoring with newer generation ILRs.

## Case

A 70 year old woman was referred by her local medical practice with recurrent syncope. These episodes were infrequent (5 episodes over a 12 month period) and lasted only a few seconds with a prompt

recovery. There were no stigmata of fitting such as incontinence or tongue biting. She had no palpitations, chest pain or other cardiovascular symptoms associated with these. At other times she remained active with no chest pain, dyspnoea or palpitations.

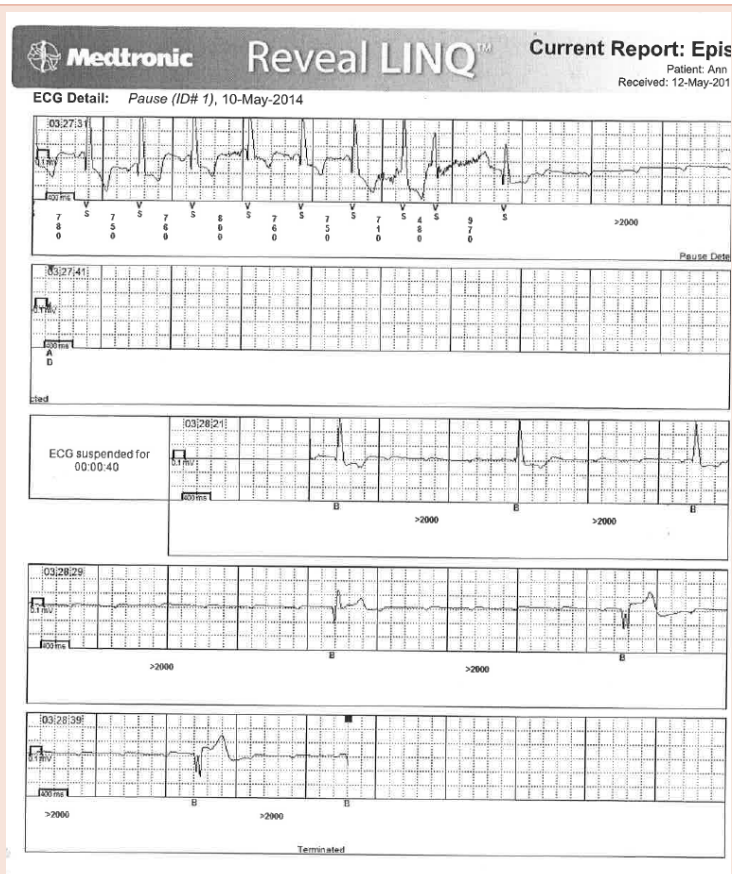


Figure 1: Recording uploaded from ILR.



12 lead electrocardiograms showed sinus rhythm with left bundle branch block (QRS 125ms). 24 hour ambulatory cardiac monitor, during which there were no symptoms, showed normal sinus rhythm throughout with no evidence of tachy- or brady- arrhythmia to explain a possible cause of syncope. A transthoracic echocardiogram demonstrated a structurally normal heart with good left ventricular function.

On the basis of these findings it was recommended that she be considered for an implantable loop recorder (ILR).

A Reveal LINQ (*Medtronic, Minneapolis, MN, USA*) ILR with home monitoring capability (*Medtronic CareLink*) was implanted under local anaesthetic, without complication. Approximately 72 hours post implant the device automatically uploaded an episode of nocturnal complete heart block and resultant significant bradycardia (**Figure 1**). The patient was promptly admitted for permanent pacing.

Home monitoring of implantable cardiac devices has been one of

the major innovations in pacing technology over the past five years improving the efficiency and effectiveness of pacing follow up clinics [1]. The utility for the use of implantable loop recorders ILR's in the investigation of syncope is well evidenced [2]. The additional facility of the automatic uploading of significant arrhythmias from ILR's is not only convenient for patients but as outlined here, allows more prompt intervention should an arrhythmia be detected. This early intervention in the setting of high grade AV block is also likely to translate into a reduced morbidity and mortality.

## References

1. Varma N, Epstein AE, Irimpen A, Schweikert R, Love C (2010) Efficacy and safety of automatic remote monitoring for implantable cardioverter-defibrillator follow-up: the Lumos-T Safely Reduces Routine Office Device Follow-up (TRUST) trial. *Circulation* 122:325-332.
2. Moya A, Sutton R, Ammirati F, Blanc JJ, Brignole M, et al. (2009) Guidelines for the diagnosis and management of syncope (version 2009). *Eur Heart J* 30:2631-2671.

**Copyright:** ©2015 Walker V, et al. This is an open-access article distributed under the terms of the Creative Commons Attribution License, which permits unrestricted use, distribution, and reproduction in any medium, provided the original author and source are credited.

**Citation:** Walker V, Beadle R (2015) Home Monitoring of Implantable Remote Loop Recorders Expedites Intervention. *J Cardiovasc Med Cardiol* 2(1): 003-004. DOI: 10.17352/2455-2976.000012