

Anurag Yadav*, TBS Buxi, Supraja Reddy, Samarjit Singh Ghuman, Kishan Singh Rawat, Savitha Srirama Jayamma

Department of CT and MRI, Sir Ganga Ram Hospital, New Delhi, -110060, India

Dates: Received: 09 October, 2015; Accepted: 18 November, 2015; Published: 20 November, 2015

*Corresponding author: Anurag Yadav, MBBS, DNB, Sir Ganga Ram Hospital, Old Rajinder Nagar, New Delhi – 110060, India, Fax: 011-42437440; Tel: +918800836830; E-mail: anu_nalin@hotmail.com

www.peertechz.com

ISSN: 2455-5282

Keywords: Vascular rings; Pulmonary slings; Airway compression; Congenital heart disease; Multi-detector computed tomography

Research Article

Clinico-Radiological Correlation in 7 Cases of Airway Compression by Vascular Anomalies on MDCT

Abstract

Compression of the airway by vascular anomalies is a co-morbidity occurring frequently in children with congenital heart diseases. Here we presented a cohort of 7 patients with respiratory distress who showed airway compression due to vascular anomalies on evaluated with multidetector computed tomography. The anomalies detected were double aortic arch, left sided aortic arch with aberrant right subclavian artery, right sided aortic arch with aberrant left subclavian artery, left pulmonary artery forming a pulmonary sling and dilated right pulmonary artery compressing the right main bronchus.

Keypoints

- Airway compression causes morbidity in children with congenital heart diseases.
- Aortic and pulmonary vessel anomalies are the main causes of airway compression.
- MDCT can delineate the vascular anatomy and the severity of resultant airway compression.

Introduction

Airway compression by vascular structures is a co-morbidity occurring in approximately 1–2% of children with congenital heart diseases (CHD) [1]. In children, airway compression by vascular structures is usually caused either by anomalous configuration of the great vessels or enlargement of normally formed vascular structures [2]. The common congenital vascular anomalies associated with compression of airway are vascular rings and slings. The term vascular ring refers to an encirclement of the trachea by a combination of derivatives of the aortic arches [3]. Pulmonary sling is commonly caused by an anomalous or aberrant left pulmonary artery. They encircle and/or compress the trachea and produce symptoms like respiratory distress, recurrent pneumonia [4]. Multi-detector computed tomography (MDCT) can delineate the vascular anatomy and degree of airway compression accurately due to the advancements like multi-planar reconstructions and post processing techniques like volume rendering, shaded surface display and minimum intensity projection.

Materials and Methods

This study presents a series of seven patients diagnosed with airway compression due to vascular anomalies out of 100 patients of CHD studied in our department over a three year period (2011-2014).

CT Angiography (CTA) of thorax was performed on Phillips Ingenuity 128 slice scanner. After pre-anesthetic check-up, the patients were scanned in supine position under sedation. Midazolam 0.1 mg/kg body weight was used for sedation. Non-contrast sections

were obtained, followed by injection of intra-venous contrast at a dose of 2 ml/kg body weight, at the rate of 2.5 ml per second at a pressure of 150 to 175 psi followed by 5ml saline flush using a dual head medrad pressure injector. The contrast used was iodixanol 270 mg/ml. Using bolus tracking method, arterial phase images were acquired when pulmonary attenuation crossed 120HU and venous phase following a delay of 20 seconds.

Results

Out of 100 patients with CHD, airway compression due to vascular anomalies was seen in 7 patients, which implies 7% of CHD had airway compression due to vascular anomalies. Out of these seven cases, six patients were females and one was a male. All the patients presented with respiratory distress and cyanosis except for one patient who presented with palpitation. Five patients had tracheal compression in whom mid and lower third was affected equally and upper third was affected by the innominate artery. None of these patients had grade IV compression. Bronchial compression was seen in three patients and all the patients had grade IV compression. In two patients, tracheal compression was due to double aortic arch, one of them had hypoplastic right arch and the other had two arches of same caliber. Two patients had tracheal compression due to aberrant subclavian artery, one of them with a left aortic arch and retroesophageal right subclavian artery and the other with a right aortic arch and retroesophageal left subclavian artery. Two patients showed compression of right main bronchus due to dilated right pulmonary artery. One patient showed compression of left main bronchus due to sling formed by left pulmonary artery. In this patient, there was also evidence of tracheal compression due to innominate artery (Figures 1-7, Table 1).

Discussion

Based on classification proposed by Freitag airway narrowing can be grouped under structural and dynamic causes [5]. Structural narrowing of airway may be due to intraluminal lesions, extrinsic compression or narrowing due to airway kinking or scarring. Dynamic or functional airway narrowing refers to triangular or tent

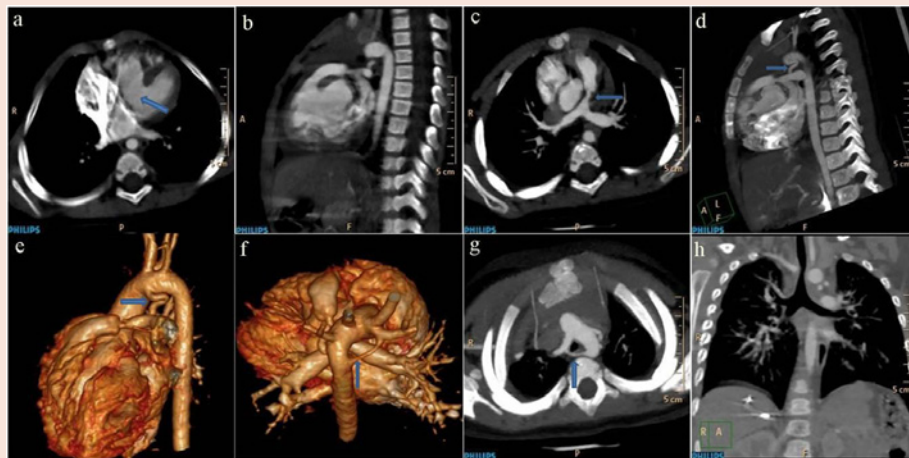


Figure 1: CTA a. axial & b. sagittal images showing a large defect in the inter-ventricular septum (blue arrow). c. axial image showing narrowing in the infundibular part of the main pulmonary artery (blue arrow). d. sagittal & e. VR image showing a communication between aortic arch and left pulmonary artery (blue arrows). f. VR & g. axial images showing left sided aortic arch and a hypoplastic right arch (blue arrows) forming a complete vascular ring. h. MIP image showing vascular ring compressing the trachea.

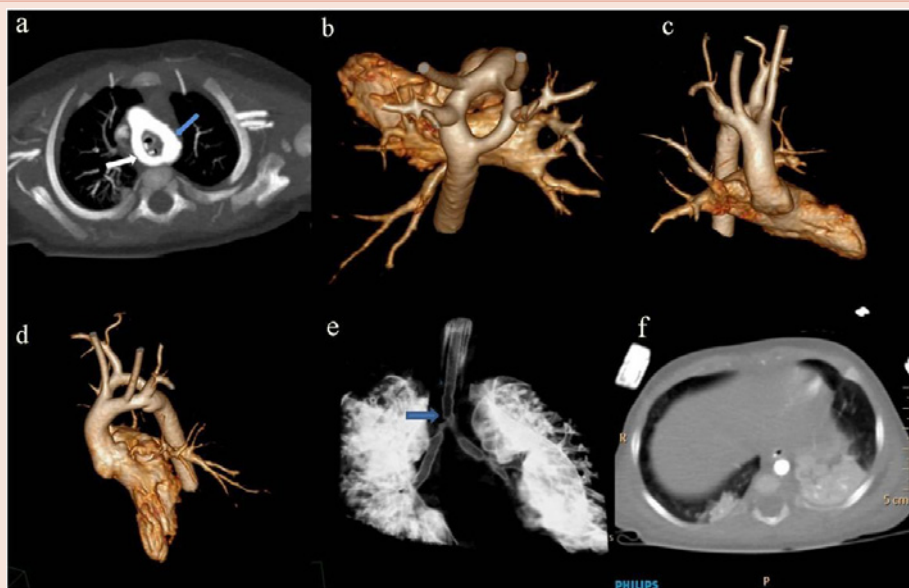


Figure 2: CTA a. axial & b. VR images showing right sided (blue arrow) and left sided (white arrow) aortic arches joining together to form a complete vascular ring. c. & d. VR images showing the right subclavian and right common carotid arteries originating from right sided aortic arch and left subclavian and left common carotid artery originating from the left sided aortic arch. e. VR image showing the vascular ring compressing the trachea (blue arrow) and associated narrowing of right and left main bronchi in their proximal part. f. axial image showing consolidation lower lobes of both lungs.

shaped airway due to damaged cartilage and inward bulging of the floppy posterior membrane.

The degree of airway narrowing is graded as grade 0 when there is no narrowing, grade I when there is less than 25% narrowing, grade II when there is 26 – 50% narrowing, grade III when there is 51 – 75% narrowing, grade IV when there is 76 – 90% narrowing and grade V when there is 91 – 100% narrowing.

The location of the airway narrowing may be in upper, middle and lower thirds of trachea or in right or left main bronchus.

Symptoms of airway compression are variable and may range from dysphagia, recurrent respiratory infections and stridor to acute respiratory distress to death [6]. In older children symptoms such as discomfort in chest, dyspnoea, cough and wheezing are often wrongly diagnosed as asthma [7]. Affected children may require mechanical ventilation and some may remain ventilator dependent even after surgery.

During embryonic development, six pairs of aortic arches connect the two primitive ventral and dorsal aortae [8]. The first,

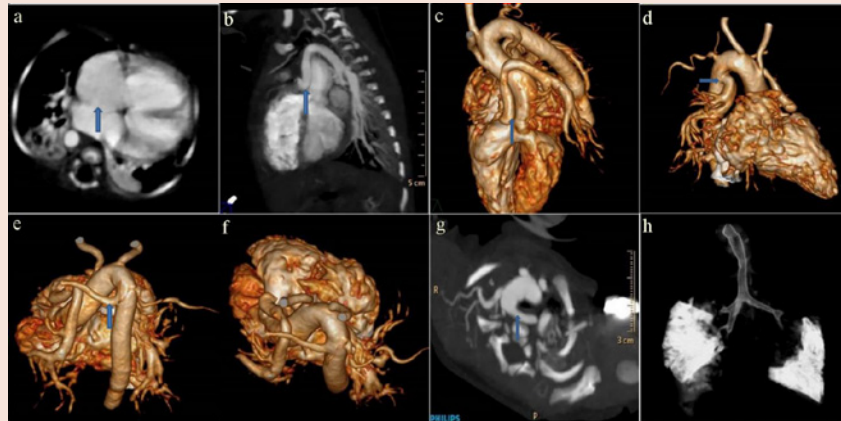


Figure 3: CTA a. axial image showing a defect in inter-atrial septum (blue arrow). b. sagittal & c. VR image showing common origin of aorta and left pulmonary artery (blue arrows). d. VR image showing the duct dependent origin of the right pulmonary artery (blue arrow) and aortic arch on the right side of the trachea. e., f. VR & g. axial images showing left subclavian artery (blue arrows) arising as the last branch of right sided aortic arch and taking a retroesophageal course and forming an incomplete vascular ring. h. VR image showing the left subclavian artery causing mild tracheal compression.

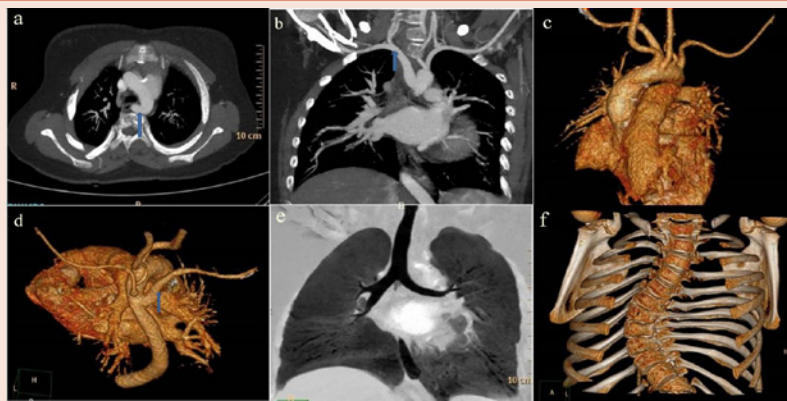


Figure 4: CTA a. axial, b. coronal c. & d. VR images showing right subclavian artery (blue arrows) which is arising as a last branch of left sided aortic arch and taking a retroesophageal course. The left vertebral and left subclavian arteries are seen to originate separately from arch of aorta. e. MIP image showing minimally compressed trachea. f. VR image showing associated congenital scoliosis.

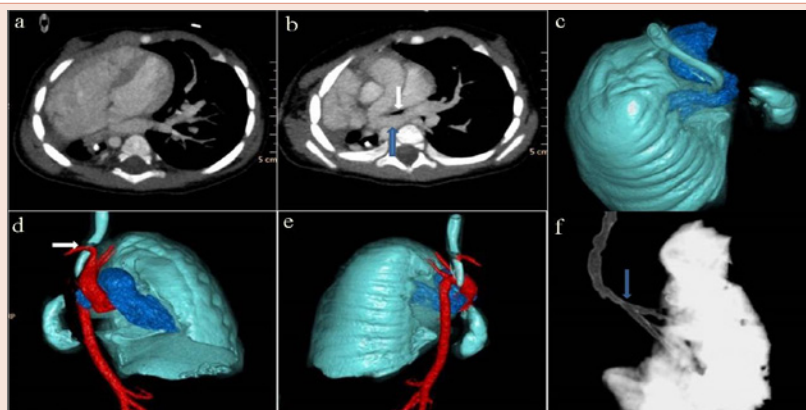


Figure 5: CTA a. axial image showing mediastinal shift towards right with hypertrophy of right atrium and right ventricle and non- visualization of right sided pulmonary vasculature. b. axial & c. VR images showing left pulmonary artery (blue arrow) forming a sling around the trachea (white arrow). d. & e. VR images showing right sided aortic arch and descending aorta with right brachiocephalic artery (white arrow) causing compression of trachea. f. VR image showing tracheal narrowing (blue arrow).

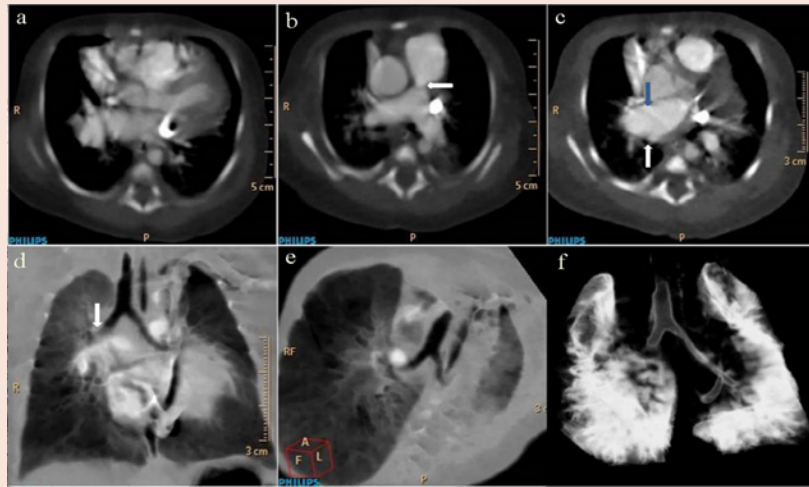


Figure 6: CTA a. axial image showing a defect in inter-ventricular septum b. axial image showing stenosis of main pulmonary artery (white arrow). c. axial image showing dilated right pulmonary artery (blue arrow) compressing the right main bronchus (white arrow). d., e. MIP & f. VR images showing compression of right main bronchus by dilated right pulmonary artery (white arrow).

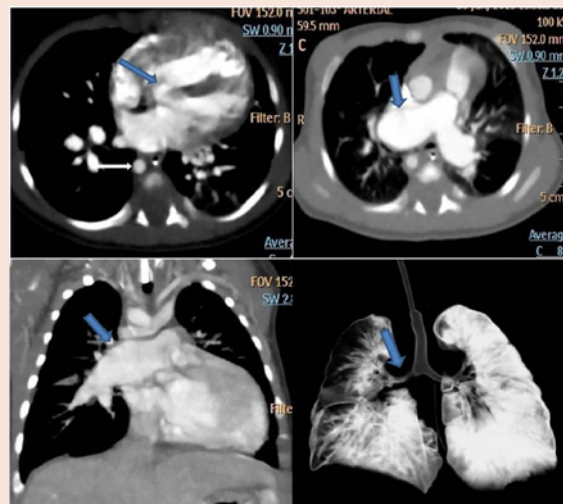


Figure 7: CTA a. axial image showing VSD. b & c. axial and coronal images showing aneurismal dilatation of right pulmonary artery. d. coronal VR image showing narrowing of right main bronchus.

Table 1: Demographic, imaging and treatment data of the patients who were included in the study.

N	Age	Sex	Symptoms	Level of airway compression	Grade of compression	Cause of compression	Cardiovascular anomalies	Other findings	Management
1	1 y	F	Cyanosis, Respiratory distress	Mid 3 rd trachea	II	DAA	VSD, Infundibular PS, PDA, DAA with hypoplastic RAA(Figure 1)	None	Resection of minor arch
2	2 m	M	Respiratory distress	Lower 3 rd trachea	III	DAA	DAA with mirror image branching (Figure 2)	Consolidation	Division of right arch
3	11 d	F	Cyanosis	Mid 3 rd trachea	II	RAA and aberrant LSCA	ASD,TA,PDA,RAA, aberrant LSCA (Figure 3)	Consolidation	Correction of underlying CHD
4	10 y	F	Palpitation	Lower 3 rd trachea	I	Aberrant RSCA	Aberrant RSCA (Figure 4)	Scoliosis	Conservative management.
5	5 m	F	Respiratory distress	LMB and upper 3 rd trachea	IV, I	LPA sling, innominate artery	RAA and absent pulmonary vessels on the right (Figure 5)	Rt lung hypogenesis	Trachea- left bronchial repair & reanastomosis.

6	3 d	F	Cyanosis, Respiratory distress	RMB	IV	Dilated RPA	Tetralogy of Fallot (Figure 6)	None	Correction of underlying CHD
7	1m	F	Cyanosis, Respiratory distress	RMB	IV	Dilated RPA	ASD,VSD, retroaortic left brachiocephalic vein (Figure 7)	None	Correction of underlying CHD

ABBREVIATIONS : ASD- atrial septal defect; DAA- double aortic arch; LMB- left main bronchus; LPA- left pulmonary artery; LSCA- left subclavian artery; PDA- patent ductus arteriosus; PS- pulmonic stenosis; RAA- right aortic arch; RMB- right main bronchus; RPA- right pulmonary artery; RSCA- right subclavian artery; TA- truncus arteriosus; VSD- ventricular septal defect.

second, and fifth arches regress. The third arches become the carotid arteries. A branch from the ventral bud of the sixth arch meets the lung bud to form the pulmonary artery. On the right side, the dorsal contribution to the sixth arch disappears; on the left, it persists as the ductus arteriosus. The seventh intersegmental arteries arise from the dorsal aorta and form the subclavian arteries. Normally, a portion of the right fourth arch regresses, leaving the usual left aortic arch.

Airway compression by aorta and its branches

A vascular ring refers to an encirclement of the trachea by an abnormal combination of derivatives of the aortic arches. The common vascular rings are double aortic arch, right arch with aberrant left subclavian artery [9]. A left arch with aberrant right subclavian artery is a less common cause of tracheal compression. Aberrant right subclavian artery sometimes takes origin from a diverticulum arising from the descending aorta, called the Kommerell diverticulum. Rarely aneurysms can be seen in Kommerell diverticulum [10]. Persistence of both right and left fourth arches leads to a double aortic arch formation. One of the arches may be atretic or both the arches may be patent. The trachea is encircled and compressed by the two arches which form a vascular ring. The ring may be patent as in double aortic arch or it may be completed by an atretic arch or ligamentum arteriosum as in right-sided aortic arch with aberrant left subclavian artery [11]. Surgical division of the ring formed by double aortic arches is indicated in patients with symptomatic airway compression and in patients undergoing surgery for repair of associated cardiovascular or thoracic anomalies. This is achieved by dividing the minor arch through an ipsilateral thoracotomy. When the minor arch is atretic, the atretic segment is ligated and divided. When the minor arch is patent, it is usually ligated and divided between the subclavian artery and descending aorta. Aberrant right subclavian artery is repaired by ligating and dividing it at its origin from aorta and reimplanting it to the right common carotid artery [12]. The standard procedure for vascular ring formed by right aortic arch and aberrant left subclavian artery is division of ligamentum arteriosum. Primary translocation of the aberrant left subclavian artery to the left carotid artery with removal of the Kommerell diverticulum is also practiced [13].

Airway compression by pulmonary artery

Pulmonary sling is a less common cause of airway compression. Pulmonary artery sling refers to anomalous or aberrant left pulmonary artery causing anterior tracheal displacement [14]. It occurs due to failure of formation of left sixth aortic arch. The term sling is usually applicable when the proximal portion of the anomalous vessel impinges on the right main bronchus causing obstructive emphysema of the entire right lung or the right middle and lower lobes, depending on the site of the compression. Dilated pulmonary arteries can

also cause bronchial compression as seen in our cases. Pulmonary sling can be repaired by dividing the left pulmonary artery and translocating and reimplanting it anterior to the airway. The second option consists of resection and anastomosis of the stenosed airway along with reimplantation of left pulmonary artery [15]. Repair of the underlying congenital heart disease with repair of stenotic pulmonary artery will normally relieve the symptoms caused by post stenotic dilatation of right or left pulmonary artery, otherwise the bronchial compression can be treated by division of the pulmonary artery and its prolongation by interposition of a conduit [16].

Imaging plays a crucial role in the diagnosis and treatment of vascular compression of the airway in children. MDCT is being increasingly used for the evaluation of children with suspected vascular compression. Other investigations like barium swallow studies and magnetic resonance imaging (MRI) are also used for the diagnosis of these conditions. Echocardiography is essential for the evaluation of abnormal vascular structures but direct evaluation of airway compression is limited [2]. Though barium swallow is accurate for diagnosis of a vascular ring, it does not delineate the precise anatomy required for surgical planning [6]. MRI is superior to CT in evaluation of cardiac anatomy and physiology. However, MRI studies are usually quite prolonged (>30 min) and may require general anesthesia [7]. Axial MDCT images are generally sufficient to diagnose the type and severity of airway compression, but multiplanar reconstruction and 3D volume rendered images may provide further useful information [17]. The main disadvantage of MDCT is exposure of the patient to ionizing radiation at the age of greatest sensitivity to its carcinogenic effects.

Conclusion

MDCT plays a pivotal role in evaluation of airway compression in patients with CHD. Complete delineation of the anomaly and grading of the stenosis with detailed measurements and virtual surgery can prognosticate the outcome of the surgery.

References

1. McLaren CA, Elliott MJ, Roebuck DJ (2008) Vascular compression of the airway in children. *Paediatric respiratory reviews* 9: 85–94.
2. Kussman BD, Geva T, McGowan FX (2004) Cardiovascular causes of airway compression. *Paediatr Anaesth* 14: 60–74.
3. Park MK Vascular rings. In: Park MK (ed) *Pediatric cardiology for practitioners*, 4th edn. St. Louis, Mosby 2002; p 241.
4. Heck HA Jr, Moore HV, Lutin WA, Leatherbury L, Truemper EJ, et al. (1993) Esophageal aortic erosion associated with double aortic arch and tracheomalacia. *Tex Heart Inst J* 20: 126–129.
5. Glazer HS, Siegel MJ. Diagnostic imaging of the trachea. In: Cummings CW, Fredrickson JM, eds. *Otolaryngology: Head and Neck Surgery*. Vol 3. 2nd ed.

- St. Louis, Mo: Mosby; 1993:2243-57.
6. Shah RK, Mora BN, Bacha E, Sena LM, Buonomo C, et al. (2007) The presentation and management of vascular rings: an otolaryngology perspective. *Int J Pediatr Otorhinolaryngol* 71: 57–62.
 7. Payne DN, Lincoln C, Bush A (2000) Lesson of the week: right sided aortic arch in children with persistent respiratory symptoms. *BMJ* 321: 687–688.
 8. Shuford WH, Sybers RG. The aortic arch and its malformations. Springfield, Ill: Thomas, 1974.
 9. Bisset GS, Strife JL, Kirks DR, Bailey WW (1987) Vascular rings: MR imaging. *AJR* 149: 251-256.
 10. Kommerell B. Verlagerung des oesophagus durch eine abnorm verlaufende arteria subclavia dextra (arteria lusoria). *Fortschr Rontgenstr* 1937; 2:56.
 11. McLaughlin RB Jr, Wetmore RF, Tavill MA, Gaynor JW, Spray TL (1999) Vascular anomalies causing symptomatic tracheobronchial compression. *Laryngoscope* 109: 312–319.
 12. Ruzmetov M, Vijay P, Rodefeld MD, Turrentine MW, Brown JW (2009) Follow-up of surgical correction of aortic arch anomalies causing tracheoesophageal compression: a 38-year single institution experience. *J Pediatr Surg* 44: 1328-1332.
 13. Kieffer E, Bahnini A, Koskas F (1994) Aberrant subclavian artery: surgical treatment in thirty-three adult patients. *J Vasc Surg* 19: 100-11.
 14. Wittenborg MH, Tantiwongse T, Rosenberg BF (1956) Anomalous course of left pulmonary artery with respiratory obstruction. *Radiology* 67: 339–345.
 15. Castaneda AR, Jonas RA, Mayer JE, Hanley FL. Vascular rings, slings, and tracheal anomalies. En: Castaneda A.R., Jonas R.A., Mayer J.E., Hanley F.L., editors. *Cardiac surgery of the neonate and infant*. Philadelphia: WB Saunders; 1994. 397-408.
 16. Corno A, Picardo S, Ballerini L, Gugliantini P, Marcelletti C (1985) Bronchial compression by dilated pulmonary artery. Surgical treatment. *J Thorac Cardiovasc Surg* 90: 706-710.
 17. Pacham P, Poe SA, Donnelly LF (2002) Low-tube-current multidetector CT for children with suspected extrinsic airway compression. *Am J Roentgenol* 179: 1523–1527.

Copyright: ©2015 Yadav A, et al. This is an open-access article distributed under the terms of the Creative Commons Attribution License, which permits unrestricted use, distribution, and reproduction in any medium, provided the original author and source are credited.

Citation: Yadav A, Buxi TBS, Reddy S, Ghuman SS, Rawat KS, et al. (2015) Clinico-Radiological Correlation in 7 Cases of Airway Compression by Vascular Anomalies on MDCT. *Global J Med Clin Case Reports* 2(1): 017-022. DOI: 10.17352/2455-5282.000020