

Vishal V Tewari^{1*}, Ritu Mehta² and Kunal Tewari³

¹Department of Pediatrics, Army Hospital (Referral & Research), New Delhi, India

²Department of Pathology, All India Institute of Medical Sciences, New Delhi, India

³Department of Anaesthesia, Base Hospital, New Delhi, India

Dates: Received: 06 February, 2016; Accepted: 04 June, 2016; Published: 10 June, 2016

*Corresponding author: Dr Vishal V Tewari, MD (Pediatrics), DNB (Neonatology), MNAMS, Department of Pediatrics, Army Hospital (Referral & Research), New Delhi-110010, M: +91-8826118889; E-mail: docvvt_13@hotmail.com

www.peertechz.com

Keywords: Congenital hypothyroidism; Muscular pseudohypertrophy; Thyroxine replacement

Case Report

Kocher-Debre-Semelaigne Syndrome: Response to Thyroxine Replacement Therapy

Abstract

Introduction: Congenital hypothyroidism with muscular pseudohypertrophy or Kocher-Debre-Semelaigne syndrome is the result of long standing untreated moderate to severe hypothyroidism. The pathogenesis of this muscular pseudohypertrophy is unknown and it is usually noted in the muscles of the extremities, limb girdle, trunk, hand and feet but is most evident in the muscles of the lower limb giving the child a Herculean appearance. This is in contrast to the thyroid myopathy due to hypothyroidism in older age group patients which results in muscle atrophy and wasting.

Case: A 6-year-old male child presented with short stature, globally delayed developmental milestones, a characteristic stocky and muscular appearance due to hypertrophied back and calf muscles. Investigations revealed delayed osseous maturation, elevated total cholesterol with low T3 and T4 with grossly elevated TSH. He was diagnosed as a case of congenital hypothyroidism with muscular pseudohypertrophy and thyroxine replacement therapy was initiated. A rare presentation of congenital hypothyroidism with muscular pseudohypertrophy i.e. Kocher-Debre-Semelaigne syndrome and dramatic response to therapy with thyroxine replacement with regression of the muscular pseudohypertrophy is discussed.

Conclusion: Prolonged untreated congenital hypothyroidism results in pseudohypertrophy of muscles of limbs and trunk. There is muscle weakness, stiffness and sluggish deep tendon jerks. Laboratory parameters show deranged thyroid function tests, elevated creatinine kinase and a myopathic pattern on electromyogram. Thyroxine replacement therapy rapidly results in regression of the pseudohypertrophy with improvement in muscle power and reduction in stiffness. Our case showed all the phenotypic and metabolic features of this syndrome with rapid resolution of muscle pseudohypertrophy with thyroxine replacement.

Abbreviations

CK: Creatinine Kinase; DQ: Developmental quotient; EMG: Electromyography; KDS: Kocher-Debre-Semelaigne Syndrome; LDH: Lactate Dehydrogenase; SMR: Sexual Maturity Rating; T3: Triiodothyronine; T4; Thyroxine; TSH: Thyroid Stimulating Hormone; TTF: Thyroid Transcription Factor; US: LS: Upper Segment to Lower Segment Ratio;

Introduction

Congenital hypothyroidism has a worldwide distribution with a prevalence of 1: 3500 infants. It may be sporadic or familial, goitrous or non-goitrous. Thyroid dysgenesis accounts for nearly 85% of these cases. A number of proteins are known to be crucial for normal thyroid gland development. These include the thyroid specific transcription factor PAX8 as well as thyroid transcription factors 1 and 2 (TTF1 & 2) [1]. Inherited defects in hormone biosynthesis are rare causes of goitrous hypothyroidism and account for nearly 10-15% of cases. In most instances the defect is transmitted as an autosomal recessive trait [2]. Protean clinical manifestations result from the involvement of multiple systems as a result of deficiency of thyroid hormones. Muscular pseudohypertrophy as a manifestation of congenital hypothyroidism, called as Kocher-Debre-Semelaigne syndrome (KSD) may rarely be seen. Management with thyroxine replacement helps in regression of the muscular pseudohypertrophy.

Case Presentation

A 6-year-old male child presented to the out-patient-department. He was the third sib of a non-consanguineous marriage; the earlier two siblings being girls aged 12 and 8 years respectively. He was born at term, at home following an uneventful antenatal and intrapartum period. There was history of neonatal jaundice, and delayed developmental milestones. The child looked stocky and muscular, with hypertrophied appearing back and calf muscles. There was abdominal distension with a firm 3 cm hepatomegaly and a small umbilical hernia. His height was 89 cm (< 5th centile), weight was 14.5 kg (< 5th centile), and US: LS ratio was 1.4:1.0. The occipito-frontal circumference was 50 cm. There was pallor, dry rough skin and mild enlargement of the tongue. The child was in sexual maturity rating (SMR) stage I. Systemic examination revealed pseudohypertrophy of the back, gluteal and calf muscles with a firm feel giving the child a 'prize - fighter appearance' (Figures 1,2). The deep tendon jerks were diminished with proximal and distal muscle weakness. The child had globally delayed developmental milestones with mental subnormality. On developmental testing his developmental quotient (DQ) was 68, with delay in the physical and mental developmental scores. Investigation done at presentation showed mild anemia (Hemoglobin 9.6 g/dl, Hematocrit 28%). Thyroid profile showed serum triiodothyronine (T3) of 0.3 ng/ml (0.6 – 1.81), thyroxine (T4) of 2 mcg/dl (5.5 – 11) and a grossly elevated

thyroid stimulating hormone (TSH) of >150 uIU/ml (0.35 – 5.5). The lipid profile was also deranged with elevated total cholesterol (326 mg/dl) and elevated triglycerides (210 mg/dl). Serum creatinine kinase (CK) was modestly elevated with a value of 1429 U/L (normal 5 – 130 U/L) and the serum lactate dehydrogenase (LDH) was 576 U/L (normal 140-280 U/L) and also elevated. Serum transaminases were minimally elevated. X-ray of left wrist showed delayed bone age. Ultrasound of the neck for thyroid gland using an 8 MHz transducer showed a hypoplastic thyroid gland in the sublingual location. The gland showed increased echogenicity and reduced vascularity on color Doppler. Technitium-99 pertechnetate scintigraphy confirmed ectopic sublingual location and showed decreased radiotracer uptake confirming thyroid dysgenesis (Figure 3). Muscle biopsy was done and it showed non-specific muscle changes with patchy atrophy and necrosis with increased connective tissue reaction and no cytological infiltration. The child was diagnosed as a case of congenital hypothyroidism with muscular pseudohypertrophy i.e. Kocher-Debre-Semelaigne syndrome and started on 50 micrograms per day of oral thyroxine replacement therapy. The child showed a dramatic improvement in growth, gaining 6 cm height over a period of two months. There was a change in the body habitus with the child losing the Herculean appearance with regression of the pseudohypertrophied muscles and attaining a more mature LS:US ratio of 1.3: 1 by the end of 1½ months of therapy (Figure 4). The muscle feel was softer with improved power and normal deep tendon jerks. There was regression of the enlarged liver resulting in the abdomen losing its distended appearance with shrinking of the umbilical hernia. The child also showed remarkable improvement in the personal-social and speech domains of development. On lab evaluation TSH was completely suppressed (< 0.5 uIU/ml) with T3 and T4 within the normal range. The elevated CK and LDH levels returned to normal (Table 1). Muscle biopsy was not repeated. Genetic studies were not performed due to resource limitation. Presently the child is on regular follow-up and attending developmental therapy and physiotherapy for improving muscle strength and ambulation.

Discussion

Congenital hypothyroidism is one of the most common and treatable causes of mental retardation in children. Its incidence, detected by neonatal screening, is rather constant worldwide and is reported to be 1:3,000 to 1:4,000. In nearly 85% of cases, congenital hypothyroidism is associated with, and presumably is a consequence of thyroid dysgenesis [3]. In these cases, there might be thyroid agenesis, hypoplasia or ectopic location. When thyroid hormone therapy is not initiated within the first 2 months of life, congenital hypothyroidism can cause severe neurological, mental, and motor damage. Untreated congenital hypothyroidism virtually affects all systems producing a myriad of clinical findings. KDS syndrome, first described by Emil Theodore Kocher in 1892 and later by Robert Debre and George Semelaigne in 1934 probably results from the effects of long-standing untreated moderate to severe congenital hypothyroidism on muscles. The occurrence of this syndrome in various forms of hypothyroidism, athyreosis, ectopic thyroid as well as hypothyroidism due to dysmorphogenesis supports this possibility. In our case ectopic sublingual thyroid gland leading to thyroid dysgenesis was responsible for the congenital hypothyroidism.

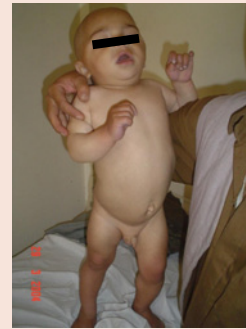

Figure 1: Child at presentation: Note the infantile upper to lower segment ratio, protuberant abdomen and small umbilical hernia.



Figure 2: Child at presentation: Note the hypertrophied calf, back, gluteal and quadriceps muscles, giving the child a 'prize-fighter appearance'.

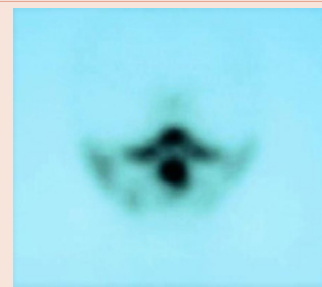


Figure 3: Technitium-99 pertechnetate thyroid scintigraphy of the child showing the thyroid gland in the sublingual location.

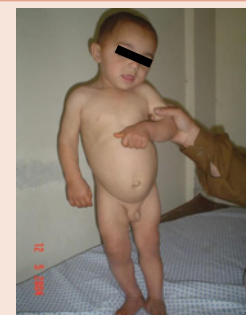

Figure 4: Child after 1½ months of Thyroxine replacement therapy showing increase in height and regression of muscle pseudohypertrophy.

Table 1: Laboratory investigation results before initiation of thyroxine replacement therapy and after therapy at three month follow-up visit.

Investigation	Before thyroxine replacement	After initiation of thyroxine
Hemoglobin (g/dl)	9.6	11.3
Hematocrit (%)	28	36
Total Cholesterol (mg/dl)	326	177
VLDL (mg/dl)	45	22
Serum Triglyceride (mg/dl)	210	94
Creatinine Kinase (U/L)	1429	45
Lactate Dehydrogenase (U/L)	576	168
Total Protein (g/dl)	4.2	5
Serum Albumin (g/dl)	2.8	3.6
Total Bilirubin (mg/dl)	1.1	0.8
Direct Bilirubin (mg/dl)	0.2	0.2
AST (U/L)	55	37
ALT (U/L)	65	35
Alkaline phosphatase (U/L)	422	288
T3 (ng/ml)	0.3	1.2
T4 (mcg/dl)	2	7.6
TSH (uIU/ml)	> 150	< 0.5

Muscle pseudohypertrophy presents at a later age and probably reflects a delay in diagnosis [4]. There is a greater preponderance in females with the male to female ratio of 2:1 [5]. In a study of twenty cases of congenital hypothyroidism over a seven year period, only three cases were noted to have muscular pseudohypertrophy [6]. Cross et al described the occurrence of this syndrome in sibling sisters in whom thyroid scan demonstrated the presence of thyroid tissue in the neck suggesting that the entity is an 'agoitrous cretinism' rather than 'athyreotic cretinism' [7].

Coarse facies with macroglossia, delayed dentition, hoarse voice, and hypertrophied appearance of muscles of the neck, tongue, face, and also calf, back, quadriceps and deltoid region are seen. The muscle pseudohypertrophy is more pronounced in children as they have immature body proportions, lower body fat content and myxoedema [8, 9]. Light microscopy of muscles shows central nucleation, variation in size and shape of muscle fiber and abortive spiral annulets. Electron microscopy shows non-specific changes, and electromyography (EMG) shows a myopathic pattern [8]. Hepatomegaly results from fatty infiltration of liver and is reversible with therapy. An association with arrhythmogenic right ventricular cardiomyopathy and pericardial effusion has also been reported [10]. Elevated serum creatinine has been seen due to rhabdomyolysis in a patient with Hashimoto's thyroiditis and KDS syndrome [11].

Thyroxine replacement reverses the muscular hypertrophy and the histopathological changes [8,12]. In our case the regression of the muscular pseudohypertrophy was remarkably fast with a complete change in the habitus apparent from the pre-treatment and post thyroxine replacement clinical photographs. This was also because of regression of the hepatomegaly and the abdominal distension.

There was also improvement in the height even though the overall height attained in these children remains less. There are limited reports describing the regression of the muscular pseudohypertrophy amongst other improvements in clinical features following initiation of therapy. However these reports have noted a regression over 6 months [12,13] while in our case a more marked and dramatic regression of muscle pseudohypertrophy was noted.

This syndrome has a potential for being confused for a primary muscle disease with resultant inordinate delay in initiation of therapy [14]. The differential diagnosis of such a child with short stature, developmental delay and pseudohypertrophy of muscles would include a mucopolysaccharidosis, overgrowth syndromes like Beckwith-Wiedemann or Simpson-Golabi-Behmel syndrome or a muscular dystrophy [15]. All these can easily be differentiated on clinical grounds. Cases like these will continue to be reported in countries where a universal newborn screening programme is not in place. This case is being highlighted, for its rarity, dramatic response to thyroxine replacement with rapid regression of the muscular pseudohypertrophy and the necessity for early recognition and differentiation from a primary muscle disease.

Conclusion

Congenital hypothyroidism of moderate to severe nature remaining untreated results in amongst other features of hypothyroidism in pseudohypertrophy of muscles giving the child a short and stocky appearance. This needs to be clinically differentiated from conditions like muscular dystrophy, overgrowth syndromes and mucopolysaccharidosis. Thyroxine replacement results in rapid resolution of the pseudohypertrophy with improvement in muscle power, reduction in stiffness and resolution of the elevated creatinine kinase. With this case report we have aimed to highlight the occurrence of muscular pseudohypertrophy and its response to thyroxine replacement.

Consent

Written informed consent was taken from the parents for publication purpose.

Acknowledgement

VVT and KT have contributed in conception and preparing the draft manuscript of this article. RM carried out the Biochemistry evaluation and Hormonal assays. KT was involved in providing clinical intensive care and helped prepare the draft manuscript. All authors contributed towards providing intellectual content for this article and have approved the final manuscript. VVT was responsible for overall supervision and is the guarantor of the article.

References

- Patil M, Ayyaz V, Bantwal G, Raman A, George B, et al. (2015) Thyroid ectopia: a case series and literature review. *Thyroid research and Practice* 12: 110-115.
- LaFranchi S (1999) Congenital hypothyroidism: etiologies, diagnosis, and management. *Thyroid* 9: 735-740.
- Macchia, PE, Lapi P, Krude H, Pirro MT, Missero C, et al. (1998) PAX8 mutations associated with congenital hypothyroidism caused by thyroid dysgenesis. *Nature Genet* 19: 83-86.

4. Unachak K, Dejkharnon P (2004) Primary congenital hypothyroidism: Clinical characteristics and Etiological study. *J Med Assoc Thai* 87: 612-617.
5. Najjar SS, Nachman HS (1965) The Kocher-Debré-Sémélaigne syndrome: Hyperthyroidism with muscular hypertrophy. *J Pediatr* 66: 901-908.
6. Havaladar PV, Shanthala C, Dhaded SM, Siddibhavi BM (1993) Clinical spectrum and follow-up study of congenital hypothyroidism at District Hospital in India. *J Trop Pediatr* 39: 38-41.
7. Cross HE, Hollander CS, Rimoin DL, McKusick VA (1968) Familial goitrous cretinism accompanied by muscular hypertrophy. *Pediatrics* 41: 413-420.
8. Virmani A, Gambhir A, Iyer PU (1990) Kocher Debre Semelaigne syndrome mimicking primary muscle disease. *Indian Pediatr* 27: 88-89.
9. Panat SR, Jha PC, Chinnannaver SN, Chakarvarty A, Aggarwal A (2013) Kocher Debre Semelaigne syndrome: a rare case report with oro-facial manifestations. *Oman Medical Journal* 28:128-130.
10. Moorthy N, Kumar S, Dabadghao P, Kapoor A (2012) Kocher-Debre-Semelaigne syndrome with arrhythmogenic right ventricular cardiomyopathy: A hitherto unrecognized association. *Indian J Endocrinol Metab* 16: 1032-1034.
11. Cimbe EA, Sen Y, Yuca SA, Cam D, Gur C, et al. (2015) Kocher-Debre-Semelaigne syndrome with rhabdomyolysis and increased creatinine. *J Pediatr Endocr Met* 28: 1383-1385.
12. Mehrotra P, Chandra M, Mitra MK (2002) Kocher Debre Semelaigne syndrome: Regression of pseudohypertrophy of muscles on thyroxine. *Arch Dis Child* 86: 224-225.
13. Shaw C, Shaw P (2012) Kocher-Debre-Semelaigne syndrome: hypothyroid muscular pseudohypertrophy – a rare report of two cases. *Case Reports in Endocrinology* 2012: 153143. 3.
14. Bhide MP, Khare MD, Jaykar AV, Ranade AY, Patnekar PN (1989) Kocher Debre Semelaigne syndrome. *Indian Pediatr* 26: 1049-1052.
15. Agrawal S, Thakur P (2010) Kocher-Debre-Semelaigne syndrome. *BMJ Case reports* 10: 1136.

Copyright: © 2016 Tewari VV, et al. This is an open-access article distributed under the terms of the Creative Commons Attribution License, which permits unrestricted use, distribution, and reproduction in any medium, provided the original author and source are credited.

Citation: Tewari VV, Mehta R, Tewari K (2016) Kocher-Debre-Semelaigne Syndrome: Response to Thyroxine Replacement Therapy. *Int J Clin Endocrinol Metab* 2(1): 008-011.