

Jana G. Hashash¹, Ibrahim Hanouneh²,
Swaytha Ganesh¹, John Nasr¹ and
Robert E. Schoen^{1*}

¹Division of Gastroenterology, Hepatology, and
Nutrition, University of Pittsburgh, Pittsburgh, PA
²Department of Gastroenterology and Hepatology,
the Cleveland Clinic, Cleveland, OH

Dates: Received: 27 April, 2015; Accepted: 09 May,
2015; Published: 11 May, 2015

*Corresponding author: Robert E. Schoen, MD,
MPH, Professor of Medicine and Epidemiology,
Division of Gastroenterology, Hepatology and
Nutrition, University of Pittsburgh Medical Center,
200 Lothrop Street - PUH, M2, C Wing, Pittsburgh,
PA 15213, Tel: 412-648-9825; Fax: 412-648-9378;
E-mail: schoen@dom.pitt.edu

www.peertechz.com

ISSN: 2455-2283

Keywords: Diminutive polyp; CT colonography;
Colonoscopy

Research Article

Implementation and Implication of Ignoring Small Polyps at Colonoscopy

Abstract

Background and Aim: CT colonography has promoted a new paradigm, that up-to 2 polyps ≤ 5 mm can be left in-situ and followed. In contrast, endoscopists identify and remove all colorectal polyps, regardless of size. We evaluated whether and how endoscopists might implement a plan of ignoring small polyps in clinical practice.

Methods: We prospectively queried endoscopists as they encountered small polyps with a hypothetical question: "If you accepted and believed in a new paradigm that a polyp ≤ 5 mm does not need to be endoscopically removed, would you remove this polyp?" We assessed how the new paradigm would be implemented by gastroenterologists and the pathologic impact of ignoring polyps' ≤ 5 mm.

Results: Of 141 patients undergoing colonoscopy, 55 (39%) had polyps and 35 (24.8%) had only small polyps ≤ 5 mm. Endoscopists were agreeable to implementing the new paradigm of not removing small polyps in 17/35 (48.6%) patients. Of patients with only small polyps where endoscopists agreed to forego removal, 13/17 (76.5%) had ≥ 1 adenomatous polyp. Among the 18/35 subjects for whom the endoscopists would remove the small polyp because of appearance or clinical situation, 12/18 (66.7%) had ≥ 1 adenoma ($p=0.521$). If polyps in subjects with only diminutive polyps were ignored, 35/55 (64%) of colonoscopies with therapy would be obviated, at an impact of not removing small adenomas in approximately 75% (25/35).

Conclusion: Ignoring polyps' ≤ 5 mm reduces therapeutic colonoscopy at a price of missing a substantial number of small adenomas.

Introduction

Small (≤ 5 mm) polyps are much more frequently encountered than medium (6-9mm) or large sized (≥ 10 mm) polyps. In a study of 4,967 patients undergoing colonoscopy, 1,025 polyps ≤ 5 mm, 247 polyps between 6-9mm, and 89 polyps ≥ 10 mm in size were detected [1]. When a small polyp is found in conjunction with a larger polyp, the small polyp's impact on cost is less significant. Presuming that the medium or large sized polyp will be removed, the procedure will include a polypectomy. Furthermore, the equipment charge may be redundant, since the same instrument may be used to remove the small and large polyp. However, when only small polyps are found, procedure costs such as equipment, facility fee for polypectomy, physician fee for polypectomy, and pathology fee are determined by small polyps. Not removing small polyps, while sparing cost, does have potential consequences. Specifically, adenomatous polyps that would have been removed will remain, with the potential to advance over time. Only rarely do small adenomas have histologic features consistent with advanced adenomas [2-4]. The natural history of small adenomas is unknown, though some studies suggest that small adenomas are not associated with significant long term risk for colorectal cancer [5]. New, creative approaches to minimizing the cost of removal of small polyps have been suggested. One such approach is to remove polyps, but discard them and not submit them for pathologic analysis, obviating the pathology cost, under the premise

that the polyps are unlikely to be significant [6-9]. While this approach does eliminate pathology costs, it does not eliminate the facility or physician fee for polypectomy, or the equipment costs. Others are pursuing the longstanding quest to differentiate hyperplastic from adenomatous polyps using technology. A recent prospective study evaluated the use of Fuji Intelligent Color Enhancement (FICE) with and without magnification for the identification of polyp histology [10]. FICE with high magnification had a better accuracy in detecting polyp histology than FICE without high magnification, particularly for diminutive polyps. Among 763 patients undergoing surveillance colonoscopy, the overall accuracy of detection of diminutive polyps ≤ 5 mm in size by FICE with high magnification was 85.4% compared to an accuracy of 79.1% for FICE without magnification ($p<0.05$) [10]. Similarly, the accuracy of diagnosing adenomatous polyps less than 10 mm using FICE with high magnification was better compared to the use of FICE without high magnification (87% vs. 80.4%; $p<0.05$) [10]. Chromoendoscopy, narrow band imaging, and autofluorescence imaging are also under study for real time pathologic assessment [6,11-13].

CT colonography has suggested yet another approach. Current guidelines have recommended ignoring polyps' ≤ 5 mm and leave them in situ [14,15]. We explored whether endoscopists would be willing to ignore small polyps, and what the consequence would be in terms of polypectomy procedures that could be avoided and adenomas that would remain in situ should such a policy be implemented. All of the

adenomas that were encountered in our study were categorized as a histologic grade of low grade dysplasia.

Methods

Physician participation

Five endoscopists from the University of Pittsburgh Medical Center participated. These endoscopists performed between 7-27 colonoscopies per week on average. The endoscopists were predominantly dedicated to clinical care, and routinely managed patients with colorectal polyps. The physicians signed informed consent at the initiation of the study that allowed the researchers to query them about management of small colorectal polyps during the endoscopic procedure.

Patient participation

Patients provided informed consent prior to their colonoscopy. The consent permitted the researcher to obtain demographic data, personal risk factors such as family history, procedure details, direct observation of the procedure, and review of pathologic records post-procedure. Patients between the ages of 18 and 90 years were included. There were no exclusion criteria; however, patients with colonoscopy procedures where no small polyps were encountered did not provide useful data for analysis.

Study procedure

The endoscopists performed colonoscopy and removed polyps as they were accustomed. There was no change to medical practice. However, when polyps were encountered that were to be removed, the research investigator prospectively queried the endoscopist as they encountered small polyps about the characteristics of the polyp including location and size. With regard to the management of small polyps, a hypothetical question was posed, «If you accepted and believed in a new paradigm, that a polyp ≤ 5 mm size does not need to be endoscopically removed, would you remove this polyp?» Subsequent to the procedure, the electronic medical record was assessed and the pathologic status of the removed polyps was determined. We then assessed the pathologic impact of ignoring polyps' ≤ 5 mm.

Statistical analysis

Pearson Chi square and independent sample t-test were used for statistical comparison. The power calculation assumed that the chi-square statistic primarily reflected differences between clinicians rather than between subjects because each clinician sees many subjects. If the mean for physician preference for removal of small polyps is 40%, at a level of 0.05 we had 80% power to detect a standard deviation (among the clinicians) of approximately 6% or greater. A p -value < 0.05 was considered significant.

Results

Among 5 endoscopists, 141 patients (63 males and 78 females) were recruited. Of the patients undergoing colonoscopy, 53.9% underwent testing for screening, 35.4% for surveillance, and the rest were for abdominal pain, iron deficiency anemia, or work up of gastrointestinal bleeding. Approximately 29 ± 1.2 (SD) patients were recruited per endoscopist. As displayed in **Figure 1**, 39% (N=55) had

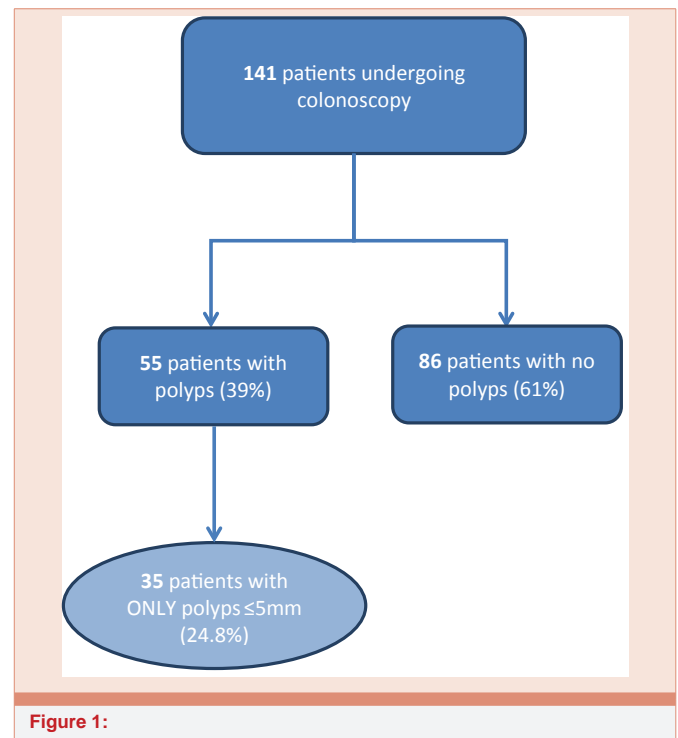


Figure 1:

any polyp and 24.8% (N=35) had only small polyps ≤ 5 mm. Of the 35 patients with small polyps, 20 (57.1%) underwent colonoscopy with forceps biopsy and 14 (40%) underwent colonoscopy with snare polypectomy, while one patient required both. As demonstrated in **Table 1**, endoscopists were agreeable to implementing the new paradigm of not removing small polyps in 17/35 (48.6%) patients. Of patients with small polyps where endoscopists agreed to forego removal, 13/17 patients (76.5%) had ≥ 1 adenomatous polyp (all of which were of a low grade histology grade). Among the 18/35 subjects for whom the endoscopists would not leave the polyp(s) in situ and would remove because of the appearance or clinical situation, 12/18 (66.7%) had ≥ 1 adenoma (histology grade of low grade dysplasia) ($p=0.521$). If polyps in subjects with only polyps ≤ 5 mm were ignored, 35/55 (64%) of colonoscopy procedures with therapy would be obviated, at an impact of not removing small adenomas in approximately 75% (25/35).

Discussion

Colonoscopy enables polypectomy, preventing benign colorectal adenomatous polyps from progressing to invasive cancer. Studies of fecal occult blood testing and flexible sigmoidoscopy demonstrate that subjects who undergo screening with polypectomy, have a reduced incidence of subsequent CRC [16,17]. Whether all polypectomy is equivalent in preventing subsequent cancer is unclear. For example, removing advanced adenomas presumably has a greater effect on preventing subsequent cancer, since these adenomas have a greater proclivity for evolving into cancer [18,19]. While it is known that small polyps are less likely to be advanced [20-22], it is not known how often small polyps advance to cancer. Small polyps, being substantially more common, consume considerable management resources. Some studies have suggested that small polyps are not

Table 1: Acceptance of paradigm among endoscopists in patients with ≥ 1 adenomatous polyp.

| | | Detected ≥ 1 Adenomatous Polyp | | Total |
|-----------------------|-------------------------|-------------------------------------|----|-------|
| | | YES | NO | |
| Accepting of Paradigm | Yes (no removal needed) | 13 | 4 | 17 |
| | No (removal needed) | 12 | 6 | 18 |
| Total | | 25 | 10 | 35 |

of concern [2] and that new approaches to their management be considered [23]. In our sample, ignoring polyps' ≤ 5 mm in diameter would obviate polypectomy in 64% of subjects currently undergoing polypectomy, but at a cost of missing adenomas in 75% of those subjects. Routine visual assessment by endoscopists without the benefit of technologic tools such as enhanced imaging was unable to differentiate between adenomatous and hyperplastic polyps, as has been previously reported [24,25]. The endoscopist's determination of whether a given polyp should remain or be removed did not associate with the pathologic diagnosis of adenoma.

While ignoring small polyps would reduce overall therapeutic endoscopy procedures by 64%, endoscopists would only hypothetically agree to do so in under 50% of cases. Their reticence in agreeing to leave polyps in situ is expected and not surprising. Given the established knowledge that polypectomy reduces subsequent cancer incidence [17,26], the fact that three-fourths of the small polyps encountered in this study were adenomas with a low grade dysplasia histologic grade, is strong justification against leaving polyps in situ. Unless additional data prove that small adenomas do not associate with subsequent cancer, it will be difficult to convince endoscopists to change their practice regarding the need for excision. Furthermore, routine white light endoscopy is not discerning enough to provide accurate real time histology.

A major limitation of this study is the artificial nature of the question we posed. Endoscopists were not asked to alter their practice, so whether they would truly be comfortable not removing polyps and leaving them in situ is speculative. We could not and did not assess the natural history of small polyps. Whether leaving them in situ will incur an increased risk of subsequent cancer is unknown. However, clues to the natural history may be forthcoming. In the UK study of flexible sigmoidoscopy [17], subjects in the intervention arm with small polyps, in contrast to those with multiple or advanced adenomas, had them removed but did not undergo subsequent colonoscopy. It will be interesting to compare the distal cancer incidence rate in subjects who had small and medium sized adenomas removed compared to those with non-adenomatous polyps and those who refused sigmoidoscopy testing, and thus did not have their polyps taken out. The difference in distal cancer incidence across these groups may provide insight to the relative risk of cancer associated with small polyps. Also anticipated are studies of CT colonography where small polyps were left in situ and observed with follow up CT scanning years later [15,27,28]. These studies should offer insight on the natural history of small polyps, although their limited sample size

will probably not allow firm conclusions on whether small polyps are associated with subsequent cancer. Other limitations of our study include the small sample size and the limited number of participating endoscopists.

In conclusion, ignoring polyps' ≤ 5 mm would substantially reduce therapeutic colonoscopy procedures but at a price of missing a considerable number of small adenomas with a histologic grade consistent with low grade dysplasia. The long term consequence of leaving small adenomas in situ requires further study.

References

1. Tsai FC, Strum WB (2011) Prevalence of advanced adenomas in small and diminutive colon polyps using direct measurement of size. *Digestive diseases and sciences* 56: 2384-2388.
2. Kim DH, Pickhardt PJ, Taylor AJ (2007) CT colonography versus colonoscopy for the detection of advanced neoplasia. *N Engl J Med* 357: 1403-1412.
3. Butterly LF, Chase MP, Pohl H (2006) Prevalence of clinically important histology in small adenomas. *Clin Gastroenterol Hepatol* 4: 343-348.
4. Pickhardt PJ, Kim DH (2009) Colorectal cancer screening with CT colonography: key concepts regarding polyp prevalence, size, histology, morphology, and natural history. *AJR Am J Roentgenol* 193: 40-46.
5. Atkin WS, Morson BC, Cuzick J (1992) Long-term risk of colorectal cancer after excision of rectosigmoid adenomas. *N Engl J Med* 326: 658-662.
6. Rex DK (2009) Narrow-band imaging without optical magnification for histologic analysis of colorectal polyps. *Gastroenterology* 136: 1174-1181.
7. Ignjatovic A, East JE, Suzuki N (2009) Optical diagnosis of small colorectal polyps at routine colonoscopy (Detect InSpect ChAracterise Resect and Discard; DISCARD trial): a prospective cohort study. *Lancet Oncol* 10: 1171-1178.
8. Kessler WR, Klein R, Wielage RC (2008) Cost savings of removing diminutive polyps without histologic assessment [abstr]. *Gastrointest Endosc* 67: AB105.
9. Kessler WR, Imperiale TF, Klein RW, Wielage RC, Rex DK (2011) A quantitative assessment of the risks and cost savings of forgoing histologic examination of diminutive polyps. *Endoscopy* 43: 683-691.
10. Kim YS, Kim D, Chung SJ, Park MJ, Shin CS, et al. (2011) Differentiating small polyp histologies using real-time screening colonoscopy with Fuji Intelligent Color Enhancement. *Clin Gastroenterol Hepatol* 9: 744-749 e1.
11. Rastogi A, Pondugula K, Bansal A (2009) Recognition of surface mucosal and vascular patterns of colon polyps by using narrow-band imaging: interobserver and intraobserver agreement and prediction of polyp histology. *Gastrointest Endosc* 69: 716-722.
12. Rastogi A, Bansal A, Wani S (2008) Narrow-band imaging colonoscopy—a pilot feasibility study for the detection of polyps and correlation of surface patterns with polyp histologic diagnosis. *Gastrointest Endosc* 67: 280-286.
13. van den Broek FJ, van Soest EJ, Naber AH, van Oijen AH, Mallant-Hent RCh, et al. (2009) Combining autofluorescence imaging and narrow-band imaging for the differentiation of adenomas from non-neoplastic colonic polyps among experienced and non-experienced endoscopists. *Am J Gastroenterol* 104: 1498-1507.
14. Pickhardt PJ, Hassan C, Laghi A (2008) Small and diminutive polyps detected at screening CT colonography: a decision analysis for referral to colonoscopy. *AJR Am J Roentgenol* 190: 136-144.
15. Zalis ME, Barish MA, Choi JR (2005) CT colonography reporting and data system: a consensus proposal. *Radiology* 236: 3-9.
16. Mandel JS (2008) Screening for colorectal cancer. *Gastroenterol Clin North Am* 37: 97-115.
17. Atkin WS, Edwards R, Kralj-Hans I, Wooldrage K, Hart AR, et al. (2010)



- Once-only flexible sigmoidoscopy screening in prevention of colorectal cancer: a multicentre randomised controlled trial. *Lancet* 375: 1624-1633.
18. Stryker SJ, Wolff BG, Culp CE (1987) Natural history of untreated colonic polyps. *Gastroenterology* 93: 1009-1013.
19. Leung K, Pinsky P, Laiyemo AO, Lanza E, Schatzkin A, et al. (2010) Ongoing colorectal cancer risk despite surveillance colonoscopy: the Polyp Prevention Trial Continued Follow-up Study. *Gastrointest Endosc* 71: 111-117.
20. Tsai FC, Strum WB (2011) Prevalence of advanced adenomas in small and diminutive colon polyps using direct measurement of size. *Dig Dis Sci* 56: 2384-2388.
21. Granqvist S, Gabrielsson N, Sundelin P (1979) Diminutive colonic polyps--clinical significance and management. *Endoscopy* 11: 36-42.
22. Hassan C, Pickhardt PJ, Kim DH, Di Giulio E, Zullo A, et al. ((2010) Systematic review: distribution of advanced neoplasia according to polyp size at screening colonoscopy. *Aliment Pharmacol Ther* 31: 210-217.
23. Rex DK, Overhiser AJ, Chen SC (2009) Estimation of impact of American College of Radiology recommendations on CT colonography reporting for resection of high-risk adenoma findings. *Am J Gastroenterol* 104: 149-153.
24. Rastogi A, Keighley J, Singh V (2009) High accuracy of narrow band imaging without magnification for the real-time characterization of polyp histology and its comparison with high-definition white light colonoscopy: a prospective study. *Am J Gastroenterol* 104: 2422-2430.
25. Sikka S, Ringold DA, Jonnalagadda S (2008) Comparison of white light and narrow band high definition images in predicting colon polyp histology, using standard colonoscopes without optical magnification. *Endoscopy* 40: 818-822.
26. Segnan N, Armaroli P, Bonelli L, Risio M, Sciallero S, et al. (2011) Once-only sigmoidoscopy in colorectal cancer screening: follow-up findings of the Italian Randomized Controlled Trial--SCORE. *J Natl Cancer Inst* 103: 1310-1322.
27. Bethea E, Nwawka OK, Dachman AH (2009) Comparison of polyp size and volume at CT colonography: implications for follow-up CT colonography. *AJR Am J Roentgenol* 193: 1561-1567.
28. Pickhardt PJ, Choi JR, Hwang I, Butler JA, Puckett ML, et al. (2003) Computed tomographic virtual colonoscopy to screen for colorectal neoplasia in asymptomatic adults. *N Engl J Med* 349: 2191-2200.

Copyright: © 2015 Hashash JG, et al. This is an open-access article distributed under the terms of the Creative Commons Attribution License, which permits unrestricted use, distribution, and reproduction in any medium, provided the original author and source are credited.

Citation: Hashash JG, Hanouneh I, Ganesh S, Nasr J, Schoen RE (2015) Implementation and Implication of Ignoring Small Polyps at Colonoscopy. *Arch Clin Gastroenterol* 1(1): 001-004. DOI: 10.17352/2455-2283.000001