

Oscar Josue Montes Aguilar<sup>1\*</sup>, Angel Medina Andrade<sup>1\*</sup>, Gerardo Perez<sup>1</sup>, Stephanie Serrano Collazos<sup>1</sup>, Brenda Ruiz<sup>1</sup>, Maria Fernanda Chein Vázquez<sup>1</sup>, Karina Yolanda Vite Pineda<sup>1</sup>, Eduardo Vidrio Duarte<sup>2</sup>, Carlos Eduardo Rodriguez Rodriguez<sup>2</sup> and Lizette Blanco Aguilar<sup>3</sup>

<sup>1</sup>University of Quintana Roo. General Surgery Department. Mexican Social Security Institute, Regional Polytechnic Manzana 1 Lote 1 509 Region General Hospital No. 17, Av. CP 55750, Cancun, Quintana Roo, Mexico

<sup>2</sup>La Salle University, General Surgery Department. Hospital Angeles Metropolitano, Tlacotalpan # 59, Cuauhtemoc, Col. Roma, Mexico

<sup>3</sup>Autonomous University of Chiapas Manuel Velasco Suarez. Prospera Rural Hospital # 1, San Cristobal de las Casas, Chiapas, Mexico

\*This authors have the same grade of responsibility as principal authors

**Dates:** Received: 07 December, 2015; Accepted: 08 January, 2016; Published: 09 January, 2016

**\*Corresponding author:** Angel Medina Andrade, University of Quintana Roo, General Surgery Department. Mexican Social Security Institute, Regional Polytechnic Manzana 1 Lote 1 509 Region General Hospital No. 17, Av. CP 55750, Cancun, Quintana Roo, Tel: (+52) (55) 9981963197; E-mail: buimedina\_5@hotmail.com

[www.peertechz.com](http://www.peertechz.com)

ISSN: 2455-2283

**Keywords:** Abdominal neoplasms; Appendiceal tumor; Appendicitis; Appendectomy

## Case Report

# Giant Appendicular Mucinous Cystadenoma: Case Report and Review of the Literature

### Abstract

**Background:** Appendix tumours present an incidence of 0.2 to 0.3% among all appendectomies. It is a rare condition, commonly found as an incidental diagnosis by imaging studies due to his lack of symptoms; nevertheless it is associated with many complications when undiagnosed like *pseudomixoma peritonei* a condition with high morbidity and mortality. This is the importance of recognize it to establish an opportune diagnose and treatment.

**Case:** A 49-year old man with abdominal pain of 6 days of evolution. He has medical history of diabetes mellitus 2 and hypertension. He presents to the emergency department complaining of pain in right lower quadrant and reports radiation to the ipsilateral renal fossa. Ultrasonography demonstrated an oblique cystic fusiform lesion suspicious of abscess. Simple computed tomography concluded probable mesenteric cyst. An exploratory laparotomy was performed finding a 12 X 8cm tumour lesion that protruded from the appendix. Tumour was dissected and a right hemicolectomy with side-end ileocolic anastomosis was performed. The histopathology study reveals an appendiceal mucinous neoplasm of low grade. After 5 days the patient was discharged without complications. After 8 months follow up the patients is asymptomatic and without evidence of tumour activity.

**Conclusion:** Appendix tumours are a rare pathology with an insidious presentation representing a difficult diagnosis; requiring high index of suspect and knowledge about the correct surgical management to obtain better outcomes.

## Introduction

Appendicular tumours are found in less than 1% of appendix pathology. Mucocele of the appendix is a rare entity, with 0.2 to 0.3% incidence, which are an obstructive appendicular dilatation of mucous material. Simple mucocele represents 29%, mucinous cystoadenoma contributes to 31 to 34% and cysatoadenocarcinoma is even less frequent, representing 22 to 23% of the malignant appendix pathology. Although cystoadenomas are a benign lesions, any proliferation or rupture of cystoadenomas have a risk of peritoneal dissemination, reason why the complete excision without rupture is important to prevent complications [1].

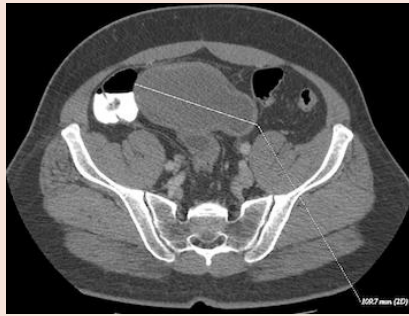
## Case Presentation

A 49-year-old man with 6 days of evolution abdominal pain presented to emergency room. He has medical history of diabetes mellitus 2 and hypertension in treatment. He presents to the emergency department complaining of pain in right lower quadrant and radiation to the ipsilateral renal fossa. Laboratories reported with blood cells 13000/mm<sup>3</sup>, Hemoglobin 13.7 g/dL, Platelets 122000, Glucose 115 mg/dL, Cr 1 mg/dL. Gas analysis report

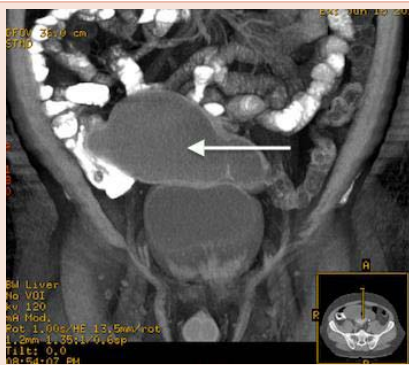
respiratory acidosis for hyperventilation. Urinalysis report leucocytes <2 $\mu$ L, no red blood cells, bacteria, nitrites, glucose, proteins or ketones. An urinary infection was discarded and acute appendicitis was suspected. Ultrasonography demonstrated an oblique cystic fusiform lesion suspicious of abscess but inconclusive. Contrast computed tomography scan (CT scan) reported a tumour image of 27 Hounsfield Units that increase to 100 Hounsfield Units with the contrast medium, has extension through the left side of the abdomen with 109.7mm of longitude and concluded probable mesenteric cyst, without other abdominal disease and no colon tumour (Figures 1,2). Tumoral markers report carcino-embryonic antigen 1.77 ng/ml (normal value 0-3ng/ml), Alfa fetoproteine 4.27 ng/ml (normal value 0-10 ng/ml), Ca-125 14 ng/ml (normal value 0-35ng/ml). An exploratory laparotomy was performed finding a 12 X 8 cm tumour lesion that protruded from the appendix (Figure 3). Tumour was dissected and right hemicolectomy with side-end ileocolic anastomosis was performed. The histopathology study reports a cecal appendix of 15x7.5x6 cm, smooth and pearly colour surface, with abundant mucus inside and fibrous septum that divide his light, flattened mucosa and wall of 0.3 cm thick with fibrous aspect (Figure 4). Conclusion of this study was appendiceal mucinous neoplasm of low grade. After 5 days the patient was discharged without complications. After 8 months follow up the patients is asymptomatic and without evidence of tumour activity.

## Discussion

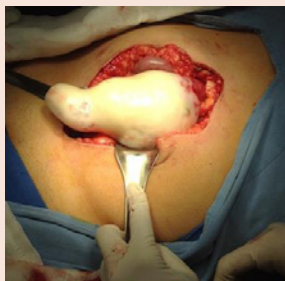Appendicular tumours have been divided in three main categories:



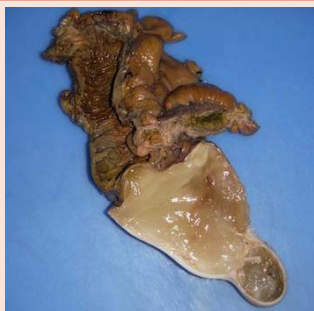**Figure 1:** CT scan axial view with a tumour image of 109.7 mm of length.



**Figure 2:** CT scan coronal view showing the extension from right to left abdomen, apparently right colon origin and septum inside.



**Figure 3:** Smooth and pearly colour surface, 12 x 8 cm tumor protruding from the appendix.



**Figure 4:** 15 x 7.5 x 6 cm cecal appendix with abundant mucus inside and fibrous septum that divide his light.

1) adenoma, 2) mucinous neoplasms of uncertain malignant potential or low-grade mucinous neoplasm and 3) adenocarcinoma [1-3].

Mucocele of the appendix can be divided into simple mucocele, which is seen in approximately 29%, epithelial hyperplasia and mucinous cystadenoma, 31 to 34% respectively, cystadenocarcinoma 5% and retention cysts [3]. Appendix mucoceles are characterized by a thin walled round cystic mass, confined to the mucosa, encapsulated and calcifications areas in 55% of cases. Mucoceles smaller than 2 cm are rarely malignant, but in larger ones, >6 cm in size, cystadenoma or cystadenocarcinoma must be suspected, with a perforation rate of 20%. Enhancing nodules in the mucocele wall suggests diagnosis of adenocarcinoma [4].

The mean age of presentation is 49.1 years and showed a female preponderance. In 50% of cases, mucocele of the appendix is asymptomatic and picked up as an incidental diagnosis. When symptomatic, 80% is presented as abdominal pain, palpable mass, nausea, vomiting, weight loss, generalized peritonism and intestinal obstruction. The right lower abdominal pain may simulate an acute appendicitis, a mass or *pseudomixoma peritonei* [1,4].

When rupture occurs there is extravasation of mucin and/or neoplastic epithelium, resulting in an inflammatory reaction and fibrosis with formation of a mass localized to the right lower quadrant [3].

Ultrasound may be helpful and may show an encapsulated cystic lesion, firmly attached to the caecum and sometimes an “onion skin” like appearance. CT scan shows round low-density, thin walled encapsulated mass communicating with the cecum. Colonoscopy may show a pathognomonic “sign of the volcano” image, an erythematous soft mass with a central crater from which mucus is discharged [4,5].

Carcinoembryonic antigen (CEA), Ca 19-9 and Ca-125 are potential tumour markers in epithelial appendicular neoplasm. CEA is raised on 56.1% and Ca 19-9 in 67.1% of cases. One or any combination of them can be elevated in 60% of patients. A Ca-125 elevation can be an important survival indicator. A 3-year survival rate in patients with elevated versus non elevated Ca-125 level were 83%, versus 52% respectively [1,5]. Synchronous colon cancers have been recognized to occur with appendicular mucoceles in 19.5 to 21.4 %, and these patients require full evaluation for the presence of other tumours [4,6].

It is estimated that based on imaging studies only 15 to 29% of appendicular mucinous cystadenomas are correctly diagnosed prior to surgical intervention. Cystadenoma of the appendix remains a diagnosis that is rarely considered prior to elective surgery [7].

Perforation occurs in approximately 20% leading to mucin distribution either locally or throughout the peritoneal cavity, knowing as *pseudomixoma peritonei* [1].

Complete excision of the mucocele without rupture is of paramount importance because complications with rupture increase the risk of malignancy. Simple appendectomy and resection of the mesentery is also thought to be adequate even in patients with cystadenocarcinoma without mesenteric lymph nodes or adjacent organ involvement. Whenever there is doubt, caecal resection or



right hemicolectomy is advised. Right hemicolectomy is indicated for: invasive adenocarcinoma, tumors near the cecum with lesions larger than 2 cm, mucin production, invasion of the lymphatics, if a non-mucinous histological type is identified by histopathological examination and serosa, or mesoappendix or cellular pleomorphism with a high mitotic rate. However, if invasive cystadenocarcinoma has already seeded into peritoneum at diagnosis time, there are no better outcomes or benefit in patient mortality with hemicolectomy compared to simple appendectomy [1,4,8,9].

Low-grade adenomas need a completely atraumatic removal to minimize the risk of peritoneal seeding. If exploration reveals a ruptured appendicular mucocele, the primary resection should be accompanied by removal of all gross implants, increasing 5-year survival rates to 91-100%. This 5-year survival rate is markedly diminished due to complications of *pseudomyxoma peritonei*, decreasing to 32 to 58%. A survival advantage was shown for patients treated by appendectomy alone (median survival 18 years) compared with those who underwent right hemicolectomy (median survival 10 years) if this patients did not have the previous mentioned hemicolectomy indications [1,8].

Aggressive treatment strategy involving cyto-reductive surgery and perioperative intra-peritoneal chemotherapy showed no benefit in the group of patients who had right hemicolectomy compared with appendectomy alone. Patients who had right hemicolectomy in the absence of intra-peritoneal chemotherapy had a survival disadvantage [9].

## Conclusions

Appendix tumors are a rare pathology with an insidious presentation representing a diagnostic challenge inclusive with appropriate image studies like CT scan, making difficult surgery planning and requiring high index of suspect and knowledge about the best surgical management to obtain good outcomes without complications or morbidities associated with the different treatment options.

Although many cystadenomas are benign, any proliferation or rupture of cystadenomas have a risk of peritoneal dissemination, reason why the complete excision without rupture is important to prevent complications and in cases of laparoscopic approach the risk of rupture must be valued.

## Informed Consent

Informed consent for publication of this case was signed.

## Acknowledgements

Claudia Cavazos PhD, for her contribution to the pathology photographs and analysis.

## References

1. Rymer B, Forsythe RO, Husada G (2015) Mucocele and mucinous tumours of the appendix: A review of the literature. *Int J Surg* 18:132-135.
2. Vriens BH, Klaase JM (2007) Giant mucinous cystadenoma of the appendix. *Am J Surg* 194: 392-393.
3. Shu-Yuan X (2010) Mucinous Neoplasms of the Vermiform Appendix. *Surgical Pathology* 3: 395-409.
4. McFarlane ME, Plummer JM, Bonadie K (2013) Mucinous cystadenoma of the appendix presenting with an elevated carcinoembryonic antigen (CEA): Report of two cases and review of the literatura. *Int J Surg Case Rep* 4: 886-888.
5. Rampone B, Roviello F, Marrelli D, Pinto E (2005) Giant appendiceal mucocele: Report of a case and brief review. *World J Gastroenterol* 11: 4761-4763.
6. Shankar S, Ledakis P, El Halabi H, Gushchin V, Sardi A (2012) Neoplasms of the Appendix Current Treatment Guidelines. *Hematol Oncol Clin N Am* 26: 1261-1290.
7. Hajiran A, Baker K, Jain P, Hashmi M (2014) Case of an appendiceal mucinous adenocarcinoma presenting as a left adnexal mass. *Int J Surg Case Rep* 5: 172-174.
8. Gonzalez Moreno S, Sugarbaker H (2004) Right hemicolectomy does not confer a survival advantage in patients with mucinous carcinoma of the appendix and peritoneal seeding. *Br J Surg* 91: 304-311.
9. Chen YN, Lee JJ, Cheng SP, Tsai CH (2015) Transformation of Low-Grade Mucinous Neoplasm of the Appendix With Pseudomyxoma Peritonei to High-Grade Sarcomatoid Carcinoma. *J Clin Med Res* 7: 571-574.

**Copyright:** © 2016 Montes Aguilar OJ, et al. This is an open-access article distributed under the terms of the Creative Commons Attribution License, which permits unrestricted use, distribution, and reproduction in any medium, provided the original author and source are credited.

**Citation:** Montes Aguilar OJ, Andrade AM, Perez G, Collazos SS, Ruiz B, et al. (2016) Giant Appendicular Mucinous Cystadenoma: Case Report and Review of the Literature. *Arch Clin Gastroenterol* 2: 001-03. DOI: 10.17352/2455-2283.000009