

Néstor Gómez Cuesta^{1,2*}, Stanley Jama^{1,3}, Ernesto Paladines⁴, Jorge Ayón⁵, Ludwig Álvarez¹ and Jorge Villón¹

¹Gastroenterology Department - León Becerra Hospital - Guayaquil, Ecuador

²Professor of Post Graduate of Surgery – University of Guayaquil – Guayaquil, Ecuador

³Chief of Surgery – León Becerra Hospital – Milagro, Ecuador

⁴Oncological Institute SOLCA – Guayaquil, Ecuador

⁵Chief of Imagenology Dept. - Kennedy Hospital - Guayaquil, Ecuador

Dates: Received: 01 July, 2015; Accepted: 28 July, 2015; Published: 30 July, 2015

***Corresponding author:** Néstor A Gómez, MD, FAC, FAGS, Kennedy Hospital, Av. San Jorge Blq Gamma, Guayaquil, Guayas, Ecuador, Tel: (593) (4) 2293459; E-mail: ngomez@gye.satnet.net

www.peertechz.com

ISSN: 2455-2283

Keywords: Lipoma; Colon; Colotomy

Case Report

Colon Lipoma

Microscopy reported a neoplasia of mesenchymal lineage, demarcated and formed by the proliferation of mature adipocytes. No mitotic activity nor nuclear atypia was observed (Figure 3).

Case 2

40 year old female patient was admitted to the emergency

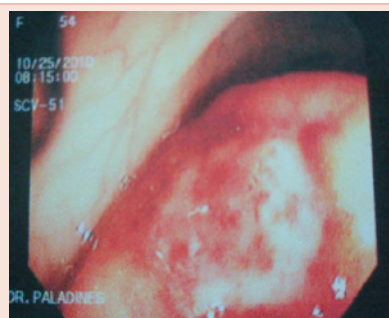


Figure 1: Polypoid lesion, pedunculated, and located 30 inches from the anal margin, with ulcers in the apex of approximately 2 inches.

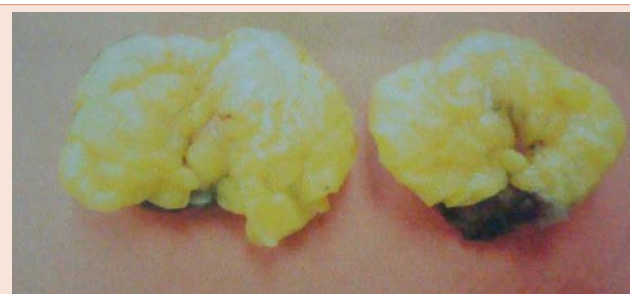

Figure 2: Macroscopic view of the polypoid nodule of adipose aspect that measures 2.16x1.37x1.18 inches.

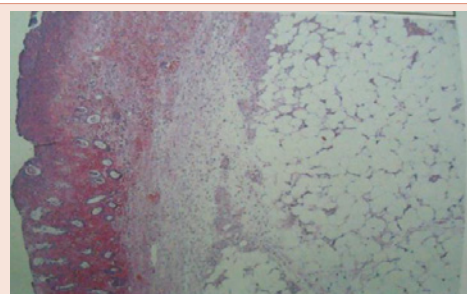


Figure 3: Microscopy of the polypoid lesion. Mature adipocytes disposed in lobules separated by thin walls of fibroconnectivevascular tissue. No nuclear atypia nor mitotic activity was observed.

Introduction

Benign lesions of the colon are infrequent and with a low percentage of appearance. Colon lipomas are in the third place of benign tumors after adenomas and smooth muscle [1,5]. Colonic lipomas are benign non epithelial tumors of soft texture and mesenchymal origin; generally they grow from mature adipocytes. Lipomas can appear in the entire gastrointestinal tract. They are generally asymptomatic, but when symptomatically, bleeding and obstruction can appear [2,4]. Its clinical diagnosis is difficult, signs and symptoms include abdominal pain, obstruction, lower gastrointestinal bleeding, diarrhea, constipation, and intussusception [5]. These tumors are found in endoscopies, radiological exams, surgical interventions, and autopsies. We present 2 cases of colon lipoma.

Case Report

Case 1

54 year old female patient presented progressive constipation that started 6 months ago. On her surgical records she presented cease and extirpation of a right ovarian cyst. Colonoscopy was performed where a sessile pedunculated polypoid lesion of approximately 2 inches was found 30 inches from the anal margin, with ulcers on its apex of approximately 2 inches of diameter (Figure 1).

The lesion obstructed the 60% of the lumen producing a valve effect which explained her symptomatology and making it impossible to extirpate via endoscopy. Instead, colotomy was performed to extirpate the tumor. The pathologist reported a nodular tumor of adipose aspect with dimensions of 2.16 x 1.37 x 1.18 inches (Figure 2).

department for presenting abdominal distention, pain, constipation, and lower gastrointestinal bleeding. She also presented one episode of enterorrhagia which made her almost faint. In the physical exam she presented abdominal distention and mild pain to palpation. Abdominal ultrasound revealed a mass located in the transverse colon. TC scans evidenced a tumoral solid mass, of adipose aspect, homogeneous, lobulated, of approximately 1.57x1.18 inches, and well demarcated suggesting a lipoma (Figures 4-6). Laparoscopic right hemicolectomy was performed and a sample was taken for biopsy. The pathologist reported a benign submucosal tumor formed by mature adipocytes. An extensive ulcer located in the overlying mucosa with an acute inflammation and fibrinopurulent exudate deposits that corresponds to submucosal, ulcerated and stenosing lipoma was also found. The pericolic lymph nodes had a preserved architecture. The lipoma located in the right colon obstructed almost 95% of the lumen. After the surgery, the patient had a successful recovery.

Discussion

Gastrointestinal lipomas were first described by Bauer et al in 1957 [6]. Lipomas of colonic presentation are non-epithelial neoplasias with an incidence of 0,035% to 4% from all the colon

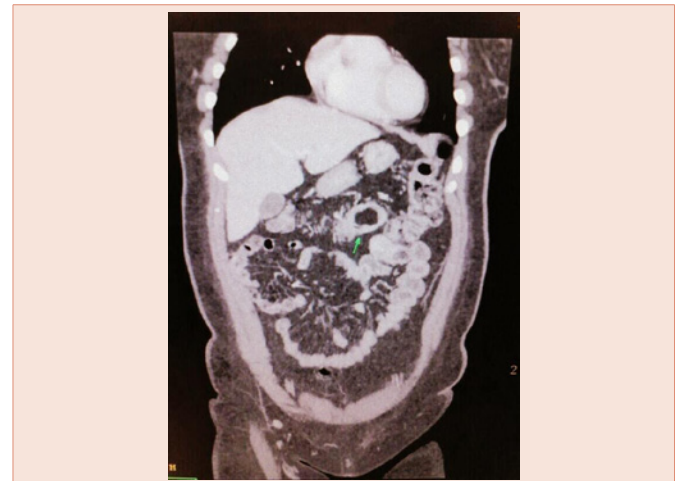

Figure 6: CT scan revealing the location of the lipoma.

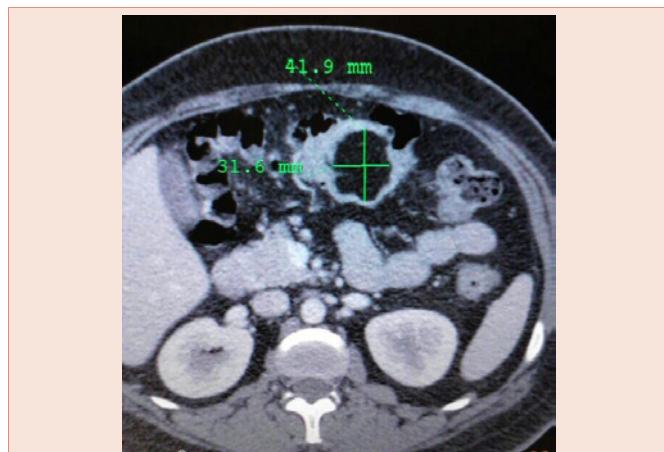


Figure 4: CT scan showing lipoma that measures 1.57x1.18 inches.

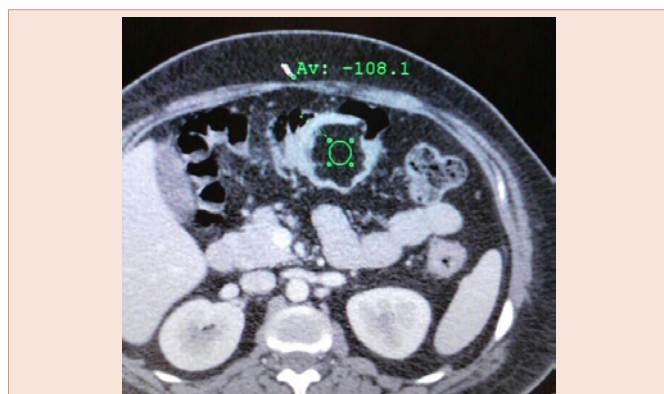


Figure 5: CT scan evidencing a mass of adipose density.

polypoid lesions. They are the most common mesenchymal tumors of the gastrointestinal tract. Sessile polypoid mass that emerges from the submucosa and leaves the mucosa intact is the most common presentation, while the pedunculated is more infrequent. They are commonly located in the ascending colon or cecum and present fewer symptoms compared with the transverse and descending colon [9]. Lipomas are frequently of plain surface and have a low rate of malignancy [1,2,10]. Familial multiple lipomas, an autosomal dominant disorder, are multiple lipomas around the body that are especially localized in the upper part [13].

Lipomas can be pedunculated and with an ulcerated or necrotic mucosa, which was presented in our 2 cases. They are generally asymptomatic, especially if their location is in the ascending colon; if it is located elsewhere, symptomatology varies. The most common symptom is abdominal pain followed by alterations in the gastrointestinal transit like our patients presented. Lower gastrointestinal bleeding, obstruction, and intussusception are less common [11].

Colon lipomas have been accidentally diagnosed in endoscopies, TC scans, colonoscopy and surgical procedures. Other radiologic studies like enema with contrast or endoscopy with ultrasound can also be performed to diagnose these tumors.

Lipomas have an endoscopic or surgical treatment. The endoscopic treatment is recommended for lipomas with a diameter of less than 0.78 inches or pedunculated lipomas with a thin stalk [12]. Complications and risks after this procedure are rare. On the other hand, the surgical treatment includes colotomy with local resection, segmentary resection, and hemicolectomy. These procedures vary according to the size, location, and possible complications of the lipoma [7,12]. Complications after this type of procedures are infrequent but include hemorrhage or perforation [2,8,11]. Chylous leakage is a rare complication and occurs after a surgical trauma of the lymphatic vessels [14]. In our 2 cases, surgical treatment was performed. The first case was a colotomy with extirpation of the



mass and posterior closure while the second case a right laparoscopic hemicolectomy was performed. Both cases did not present any type of complications and had a favorable recuperation after surgery.

References

1. Goligher JC (1980) Cirugía de Ano Recto y Colon. 2a ed. Barcelona: Salvat
2. Barrera A, Bannura G (1998) Lipoma de colon transverso como causa de intususcepción colónica. Rev Chil Cir 50: 669-673.
3. Zeebregts CJAM, Geraedts AAM, Blaawgeers JLG (1995) Intussusception of the sigmoid colon because of an intramuscular lipoma. Dis Colon Rectum 38: 891-892.
4. Notaro JR, Masser PA (1991) Annular colon lipoma: a case report and review of the literature. Surgery 110: 570-572.
5. Thonet G, Setton J, García M, et al. (2003) Lipomas de colon, a propósito de 2 casos. Rev Chil de Cirugía 55: 274-276.
6. Corrales A, Zuniga A (2008) Lipoma del tracto gastrointestinal (Reporte de un caso y Revisión Bibliográfica). Revista Médica de Costa Rica y Centroamérica. LXV (586) 383-385.
7. Katsinelos P, Chatzimavroudis G, Zavos C, Pilpilidis I, Lazaraki G, et al. (2007) "Cecal lipoma with pseudomalignant features: a case report and review of the literature," World J Gastroenterol 13: 2510-2513.
8. Castro E, Stearns M (1972) "Lipoma of the large intestine: a review of 45 cases," Diseases of the Colon and Rectum 15: 441-444.
9. Hong Zhang, Jin-Chun Cong, Chun-Sheng Chen, Lei Qiao, En-Qing Liu (2005) Submucous colon lipoma: A case report and review of the literature. World Journal of Gastroenterology 11: 3167-3169.
10. Siegal A, Wintz M (1991) Gastrointestinal lipomas and malignancy. J Surg Oncol 47: 107-104.
11. Rogy M, Mirza D, Berlakovich G, Winkelbauer F, Rauhs R (1991) "Submucous large-bowel lipomas-presentation and management. An 18-year study". European J Surg 157: 51-55.
12. Jiang L, Jiang LS, Li F (2007) "Giant submucosal lipoma located in the descending colon: a case report and review of the literature," World J Gastroenterol 13: 5664-5667.
13. Sayar I, Demirtas L, Gurbuzel M, Isik A, Peker K, et al. (2014) Familial multiple lipomas coexisting with celiac. J Med Case Rep 8: 309.
14. Isik A, Okan I, Firat D, Idiz O (2015) Una complicacion muy poco frecuente de la cirugia colorrectal y su tratamiento: fuga quillosa. Cir. Esp 118-120.

Copyright: © 2015 Cuesta NG, et al. This is an open-access article distributed under the terms of the Creative Commons Attribution License, which permits unrestricted use, distribution, and reproduction in any medium, provided the original author and source are credited.

Citation: Cuesta NG, Jama S, Paladines E, Ayón J, Álvarez L, et al. (2015) Colon Lipoma. Arch Clin Gastroenterol 1 (1): 014-016. DOI: 10.17352/2455-2283.000004