

Clinical Image

Left Circumflex Artery–Right Atrium Fistula Demonstrated By Transthoracic Echocardiography

Rahul Choudhary*, Vijay Pathak, Vimla Kumari and Dinesh Gautam

Department of Cardiology, Sawai Man Singh Medical college, Jaipur and 2 Dr SN Medical College, Jodhpur, Rajasthan, India

*Corresponding author: Rahul Choudhary, Department of Cardiology, Sawai Man Singh Medical college, Jaipur and 2 Dr SN Medical College, Jodhpur, Rajasthan, India. E-mail: rahulanna@gmail.com

Received: 09 December, 2015; Accepted: 11 January, 2016; Published: 25 January, 2016

Clinical Image

Eight year-old child presented with two year history of dyspnoea on exertion. Clinical examination revealed a continuous murmur peaking in diastole. Two dimensional transthoracic echocardiography revealed a dilated left circumflex artery (LCX) in parasternal short axis view with enlarged right atrium (RA) and right ventricle (Figures 1A,B). Apical four chamber view demonstrated fistulous flow from LCX to RA (Figures 1C,D, arrows); flow travelled initially in left atrioventricular groove and then along inter-atrial septum before opening into RA near its superior wall (Movie 1).

Coronary cameral fistulae are rare congenital vascular anomalies that present largely as asymptomatic, incidental findings on imaging studies [1,2]. Coronary angiography has traditionally been used to diagnose coronary artery fistula. With the advent of high-resolution two-dimensional and colour Doppler echocardiography, the accurate detection of coronary artery fistula has increased [3]. Echocardiographic evidence of coronary-cameral fistula is continuous flow from the epicardial surface into the RA cavity on colour Doppler imaging.

References

1. Friedman W, Silverman N (2001) Congenital heart disease in infancy and childhood. In : Braunwald E, Editor, Heart disease, A textbook of cardiovascular medicine. Ed 6, Philadelphia, WB saunders 1505-1591.
2. Vavuranakis M, Bush CA, Boudoulas H (1995) Coronary artery fistulas in adults: incidence, angiographic characteristics, natural history. Cathet Cardiovasc Diagn 35: 116–120.
3. Barbosa MM, Katina T, Oliveira HG, Neuenschwander FE, Oliveira EC (1999) Doppler echocardiographic features of coronary artery fistula: Report of 8 cases. J Am Soc Echocardiogr 12: 149-154.

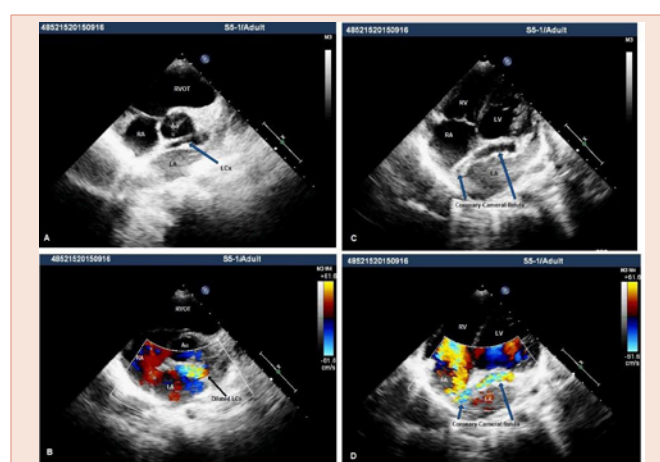
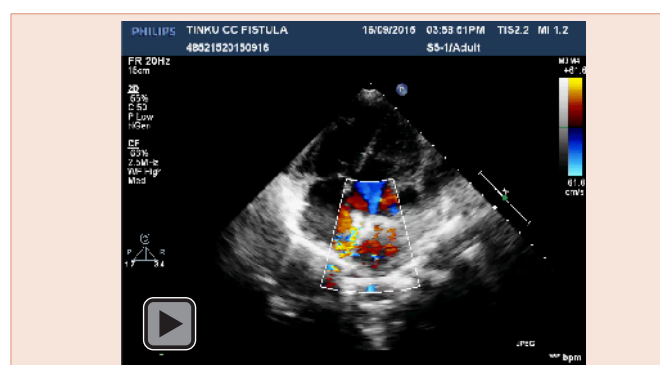


Figure 1: A and B. Parasternal short axis view showing dilated left circumflex artery (LCX) and enlarged right atrium (RA). C and D. Apical four chamber view showing fistulous flow from LCX to RA (arrow).

(Ao,Aorta; LA,left atria; LCx,left circumflex artery; LV,left ventricle; RA,right atria; RV, right ventricle; RVOT,right ventricular outflow tract).



Movie 1

Copyright: © 2016 Choudhary R, et al. This is an open-access article distributed under the terms of the Creative Commons Attribution License, which permits unrestricted use, distribution, and reproduction in any medium, provided the original author and source are credited.

Citation: Choudhary R, Pathak V, Kumari V, Gautam D (2016) Left Circumflex Artery–Right Atrium Fistula Demonstrated By Transthoracic Echocardiography. Imaging J Clin Med Sciences 3(1): 001. DOI: 10.17352/2455-8702.000021