

Shinji Makino* and Hironobu Tampo
CO

Department of Ophthalmology, Jichi Medical
University

Dates: Received: 10 June, 2016; Accepted: 12 July,
2016; Published: 13 July, 2016

*Corresponding author: Shinji Makino, MD,
Shimotsuke, 3311-1 Yakushiji, Tochigi 329-0498,
Japan, Tel: +81-285-58-7382; Fax: +81-285-44-8365;
E-mail: makichan@jichi.ac.jp

www.peertechz.com

ISSN: 2455-8702

Clinical Image

Peripheral Circumferential Chorioretinal Atrophy in a Patient with Alagille Syndrome

Clinical Image

The patient was a 15-year-old girl with an established diagnosis of Alagille syndrome (AS) since early life. Her medical history was significant for systemic manifestations of AS including liver transplantation and pulmonary artery balloon dilation. She had an unusual triangular facies characterized by a broad overhanging forehead, deep set, hypertelorlic eyes and small pointed chin. Her best-corrected visual acuity was 1.0 in both eyes. Slit-lamp examination was positive for posterior embryotoxon in both eyes. Funduscopy revealed diffuse choroidal hypopigmentation with increased visibility of the choroidal vessels and symmetric, well-circumscribed macular discoloration (Figure 1). A circumferential chorioretinal atrophy was also detected in the peripheral retina (Figure 1). Fundus autofluorescence (FAF) imaging clearly defined hypofluorescent areas in the peripapillary regions that extended along the macula and had a sleep mask appearance (Figure 2). Peripheral circumferential chorioretinal atrophy was also clearly detected (Figure 2).

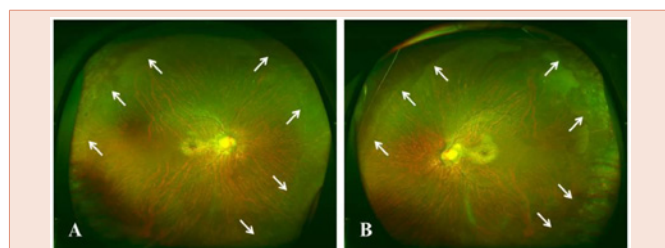


Figure 1: Right (A) and left (B) wide-field fundus photographs.

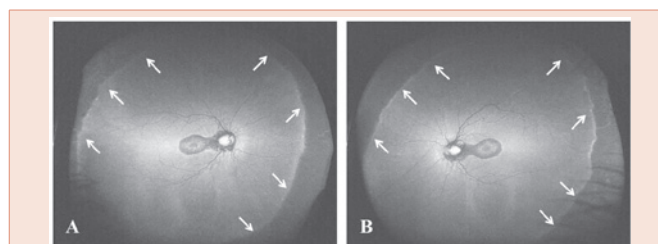


Figure 2: Right (A) and left (B) wide-field fundus autofluorescence images.

AS is clinically defined by neonatal cholestatic jaundice with intrahepatic bile duct hypoplasia. Ocular findings included posterior embryotoxon, iris abnormalities, optic disc anomalies, and fundus changes [1]. We found very few cases in the literature presenting as AS and chorioretinal atrophy with a sleep mask appearance when examined by FAF imaging [2,3]. Recently, peripheral circumferential chorioretinal atrophy was detected by wide-field FAF imaging [3]. To our knowledge, this is the second documentation of peripheral chorioretinal atrophy evaluated by wide-field FAF imaging. We speculate that chorioretinal atrophy with a sleep mask appearance and peripheral circumferential chorioretinal atrophy may be characteristic findings for AS. We also emphasize that FAF imaging is useful in visualizing chorioretinal changes in patients with AS.

References

1. Hingorani M, Nischal KK, Davies A, Bentley C, Vivian A, et al. (1999) Ocular abnormalities in Alagille syndrome. *Ophthalmology* 106: 330-337.
2. Makino S, Ohkubo Y, Tampo H (2012) Optical coherence tomography and fundus autofluorescence imaging study of chorioretinal atrophy involving the macula in Alagille syndrome. *Clin Ophthalmol* 6: 1445-1448.
3. Esmaili DD (2015) Chorioretinal atrophy in Alagille syndrome. *Retin Cases Brief Rep* 9: 330-332.

Copyright: ©2016 Makino S, et al. This is an open-access article distributed under the terms of the Creative Commons Attribution License, which permits unrestricted use, distribution, and reproduction in any medium, provided the original author and source are credited.

Citation: Makino S, Tampo CO H (2016) Peripheral Circumferential Chorioretinal Atrophy in a Patient with Alagille Syndrome. *Imaging J Clin Med Sciences* 3(1): 009-009. DOI: 10.17352/2455-8702.000026