

Franco Mónica*, Colaço Luisa, Pereira Cristina, Neves Joana and Seldon Raquel

Instituto de Oftalmologia Dr. Gama Pinto, Lisboa, Portugal

Dates: Received: June 10, 2014; Accepted: July 24, 2014; Published: July 26, 2014

*Corresponding author: Franco Mónica, Instituto de Oftalmologia Dr. Gama Pinto, Lisboa, Portugal, E-mail: monicasofiafranco@gmail.com

www.peertechz.com

Keywords: Syphilis; Optic neuropathy; Immunocompetent; Penicillin

ISSN: 2455-1414

Case Report

Secondary Syphilis Presenting as Optic Neuritis in an Immunocompetent Patient: Case Report

Abstract

Purpose: The purpose of this report is to present a case of optic neuropathy as a manifestation of secondary syphilis in an HIV-negative patient.

Methods: We describe a case of gradual loss of visual acuity in the left eye (LE) in a 53-year-old healthy woman.

Results: The patient presented with visual acuity of 20/20 in the right eye and hand movements in the LE. Fundoscopy revealed swollen optic disc in the LE. Fluorescein angiography showed leakage of dye from the optic disc. Optical coherence tomography (OCT) confirmed the oedema in the left optic disc. Serologic testing was positive for venereal disease research laboratory (VDRL) and fluorescent treponemal antibody absorption (FTA-ABS), and negative for HIV antibodies.

Conclusions: Ophthalmologic findings, including disc oedema, may be the presenting features of syphilis, therefore ophthalmologists have the opportunity to play a key role in the diagnosis and management of this disease, important for a good visual outcome.

Introduction

Syphilis is a sexually transmitted, systemic infection caused by the spirochete bacterium *Treponema pallidum* [1]. The incidence of syphilis continues to rise in the USA and Europe, and it is estimated that around 20% of patients with syphilis in the USA also have HIV infection [2-4]. Ocular involvement may be silent or present as anterior uveitis, choroiditis, interstitial keratitis, retinal vasculitis, retinitis, optic neuritis, dacryoadenitis, or scleritis [5-7]. The observation of optic nerve abnormalities in an ophthalmological examination in a patient with syphilis is highly suggestive of central nervous system (CNS) involvement and should be considered synonymous with neurosyphilis [8,9].

Purpose

The purpose of this report is to present a case of optic neuropathy as a manifestation of secondary syphilis in an HIV-negative patient.

Case Report

The authors obtained written consent from the patient for the publication of her anonymised clinical data.

A 53-year-old healthy woman presented with complaints of decreased visual acuity in the left eye (LE) which she had begun to notice 2 weeks prior. In a general examination, a rash on the palms and soles was detected. Best corrected visual acuity of 20/20 in the right eye (RE) and hand movements in the LE. Biomicroscopy of the anterior segment was unremarkable in both eyes, and intra-ocular

pressure was 12mmhg in both eyes. Fundoscopy showed a swollen optic disc in the LE, with no abnormalities detected in the RE. A left relative afferent pupillary defect was present (Figure 1 and Figure 2).

Fluorescein angiography showed leakage of dye from the optic disc. Optical coherence tomography (OCT) confirmed the oedema in the left optic disc.

Serologic testing was positive for VDRL (1:128) and FTA-ABS, and negative for HIV antibodies. No abnormalities were detected during magnetic resonance imaging of the cranium and orbits.

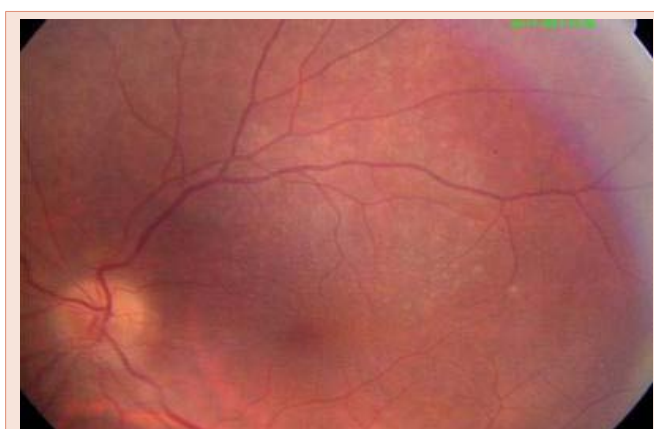


Figure 1: Colour Fundus, Left Eye.

Cerebrospinal fluid (CSF) examination revealed normal opening pressure, and that CSF protein, glucose and white cell count were within the normal range. The CSF VDRL was negative and CSF Treponema pallidum particle agglutination technique (TP.PA) reactive at 1:160. CSF results were thus inconclusive of neurosyphilis (Figure 3 and Figure 4).

The diagnosis of optic neuropathy associated with secondary syphilis in the LE was made and the patient was treated with intravenous aqueous penicillin G (four million units given every 4h for 2weeks). Three months after the treatment, funduscopy revealed the absence of oedema in the LE, with a visual acuity of 20/20 in both eyes, and VDRL titer was 1:32.

Discussion

Ocular involvement in syphilis is rare and typically occurs with secondary or tertiary syphilis [8,10,11]. Tamesis and Foster [8] reported that uveitis was the most common ocular manifestation in ocular syphilis. CNS involvement can occur at any stage of syphilis. Ocular syphilis has been reported in both immunocompromised

and immunocompetent individuals[12], therefore patients should be tested for HIV [8,13,14].

Patients presenting with ocular manifestations who are subsequently diagnosed with syphilis should have lumbar puncture to rule out neurosyphilis. Standard treatment of ocular syphilis is intravenous penicillin, as recommended for patients with neurosyphilis, regardless of immune status [15]. There is limited data on the use of systemic corticosteroids as an adjunct for posterior uveitis, scleritis and optic neuritis associated with syphilis [7].

Conclusion

This report describes an infrequent case of unilateral optic neuropathy as presenting symptom of secondary syphilis in an immunocompetent patient. Epidemiological data indicates a worldwide reemergence of syphilis and a high degree of suspicion is necessary in view of its multitude of presenting ocular signs without pathognomonic features. Ophthalmologic findings may be the presenting features of syphilis, therefore ophthalmologists have the opportunity to play a key role in the diagnosis and management of this disease, important for a good visual outcome.

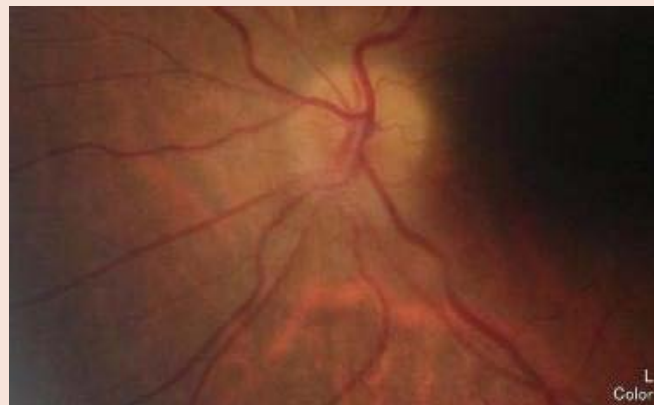

Figure 2: Colour Fundus, Left Eye.

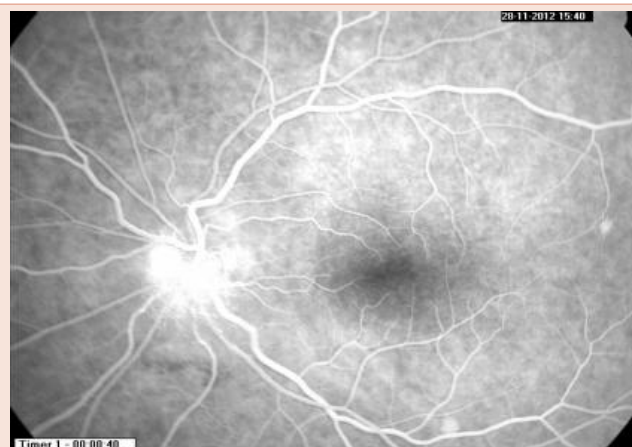


Figure 3: Fluorescein Angiogram, Left Eye.

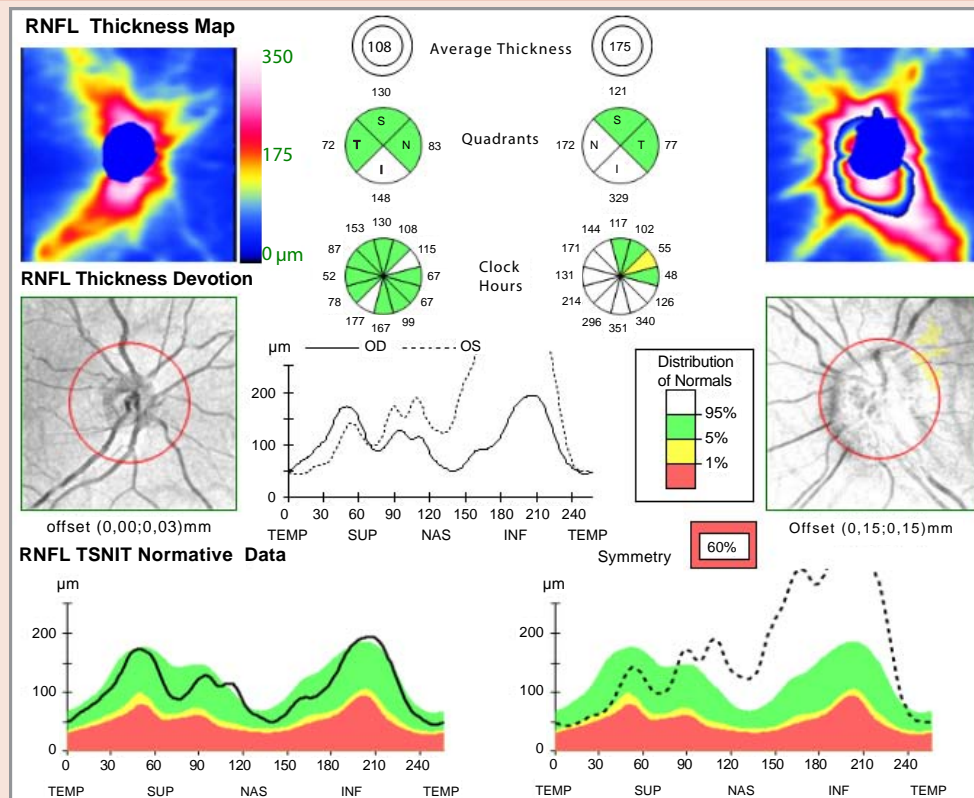


Figure 4: Optical coherence tomography optic nerve, Right and Left Eye.

Summary Statement

We report on an infrequent case of unilateral optic neuropathy as presenting symptom of syphilis in an immunocompetent patient.

References

- Lutchman C, Weisbrod DJ, Schwartz CE (2011) Diagnosis and management of syphilis after unique ocular presentation. *Can Fam Physician* 57: 896-899.
- Foti C, Carnimeo L, Delvecchio S, Guerriero S, Cassano N, et al. (2009) Secondary syphilis with progressive ocular involvement in an immunocompetent patient. *Eur J Dermatol* 19: 288.
- Ghanem KG (2010) Evaluation and management of syphilis in the HIV-infected patient. *Curr Infect Dis Rep* 12: 140-146.
- Puech C, Gennai S, Pavese P, Pelloux I, Maurin M, et al. (2010) Ocular manifestations of syphilis: recent cases over a 2.5-year period. *Graefes Arch Clin Exp Ophthalmol* 248: 1623-1629.
- Tamesis RR, Foster CS (1990) Ocular syphilis. *Ophthalmology* 97: 1281-1287.
- Lukehart SA, Hook EW 3rd, Baker-Zander SA, Collier AC, Critchlow CW, et al. (1988) Invasion of the central nervous system by *Treponema pallidum*: implications for diagnosis and treatment. *Ann Intern Med* 109: 855-862.
- Margo CE, Hamed LM (1992) Ocular syphilis. *Surv Ophthalmol* 37: 203-220.
- Gaudio PA (2006) Update on ocular syphilis. *Curr Opin Ophthalmol* 17: 562-566.
- Bandettini di Poggio M, Primavera A, Capello E, Bandini F, Mazzarello G, et al. (2010) A case of secondary syphilis presenting as optic neuritis. *Neurol Sci* 31: 365-367.
- Kiss S, Damico FM, Young LH (2005) Ocular manifestations and treatment of syphilis. *Semin Ophthalmol* 20: 161-167.
- Klig JE (2008) Ophthalmologic complications of systemic disease. *Emerg Med Clin North Am* 26: 217-231.
- Foti C, Carnimeo L, Delvecchio S, Guerriero S, Cassano N, et al. (2009) Secondary syphilis with progressive ocular involvement in an immunocompetent patient. *Eur J Dermatol* 19: 288.
- Barile GR, Flynn TE (1997) Syphilis exposure in patients with uveitis. *Ophthalmology* 104: 1605-1609.
- Aldave AJ, King JA, Cunningham ET Jr (2001) Ocular syphilis. *Curr Opin Ophthalmol* 12: 433-441.
- Shalaby IA, Dunn JP, Semba RD, Jabs DA (1997) Syphilitic uveitis in human immunodeficiency virus-infected patients. *Arch Ophthalmol* 115: 469-473.

Copyright: ©2014 Mónica F, et al. This is an open-access article distributed under the terms of the Creative Commons Attribution License, which permits unrestricted use, distribution, and reproduction in any medium, provided the original author and source are credited.

Citation: Mónica F, Luisa C, Cristina P, Joana N, Raquel S (2014) Secondary Syphilis Presenting as Optic Neuritis in an Immunocompetent Patient: Case Report. *J Clin Res Ophthalmol* 1(1): 019-021. DOI: 10.17352/2455-1414.000005