

Farhan Raza Khan<sup>1\*</sup> and Sadia Tabassum<sup>2</sup>

<sup>1</sup>Assistant Professor, Operative Dentistry, Aga Khan University Karachi, Pakistan

<sup>2</sup>Resident, Operative Dentistry, Aga Khan University Karachi, Pakistan

**Dates:** Received: 29 October, 2014; Accepted: 09 January, 2015; Published: 11 January, 2015

**\*Corresponding author:** Farhan Raza Khan, Assistant Professor, Operative Dentistry, Aga Khan University Karachi, Pakistan, Tel: +92 213 34863940; Fax: +92 213 4934294; E-mail: farhan.raza@aku.edu

[www.peertechz.com](http://www.peertechz.com)

ISSN: 2394-8418

**Keywords:** Dental Implant; Immediate implant placement; Immediate loading; Single tooth implant

## Case Report

# Replacement of A Hopeless Mandibular Tooth With an Immediately Placed and Loaded Dental Implant : A Case Report

### Abstract

Immediate implants have gained a wide popularity in the recent times as patients benefit from reduced time interval between the implant placement and delivery of the final restoration. Careful treatment planning and execution of the procedure can prevent the need to undergo second stage surgery for prosthesis and thus improves the patients' compliance. An immediate placement and loading protocol has been followed in this case report.

## Introduction

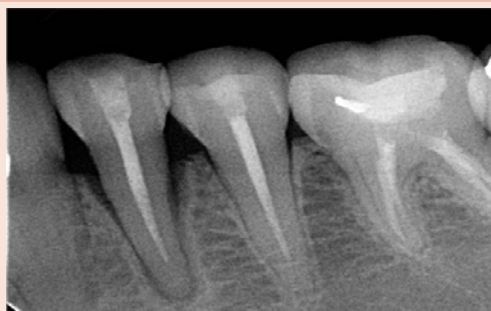Immediate restoration of implants has become a predictable method of replacing teeth with a successful prognosis [1]. Immediate loading is defined as 'an implant that is put in function within 1 week after its placement [2]. This case report describes an immediate placement of a dental implant in the premolar region of the mandible.

## Case Presentation

A 25-year-old otherwise healthy female presented to the dental clinic at Aga Khan University Hospital, Karachi, Pakistan with the chief complaint of pain and sensitivity in a tooth in left side of the mandible. On clinical and radiographic examination it was observed that her first premolar (FDI tooth # 34) was periodontally compromised. The periodontal probing depth was 6mm mesially and 5 mm distally with clinical attachment loss of 4mm. The tooth exhibited grade III mobility and the overall prognosis of its salvage appeared guarded (Figure 1). Moreover, the patient was scheduled to immigrate out of country in a month's time period. As the patient was quite conscious regarding her esthetics and did not want to remain toothless, therefore, an option of immediate implant placement and temporization was offered. After discussion, she opted for it.

## Case Management

After clinical and radiographic examination, procedure of implant surgery and prosthetics was explained to the patient and written informed consent was taken. The patient was medically fit and there was no contraindication for the procedure. A preoperative alginate impression of the lower arch was taken to yield a gypsum cast on which a vacuum formed suck down stent was made in the in-office dental laboratory. One cartridge (1.7ml) of local anaesthesia (2% lidocaine with 1:100,000 epinephrine) was given as a buccal infiltrate and another cartridge of same volume and strength was administered for left inferior alveolar and lingual nerve block using standard technique. An atraumatic tooth extraction was carried out using periosteal elevator, coupland elevator and mandibular extraction



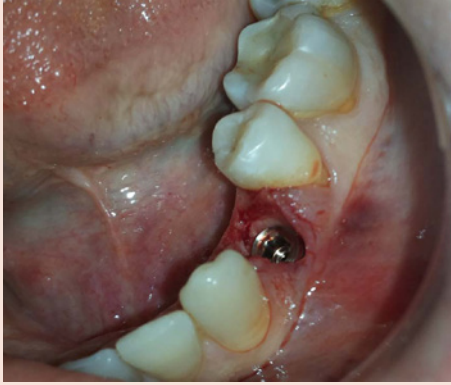**Figure 1:** Initial radiographic presentation of the lower left premolar that was periodontally compromised.

forceps. The socket was inspected and explored with probe and then irrigated with saline. The length of the implant had been decided pre-operatively on the patient's radiograph to keep a safe distance from the mental foramen. The osteotomy was prepared up to 13mm length with the surgical drill of Zimmer surgical kit at 1200 rpm under saline irrigation. The orientation of the long axis was confirmed with the guide pin and a Zimmer Tapered Screw-vent, 4.7mm diameter X13 mm length implant was immediately placed (Figure 2a, 2b). Primary stability was achieved beyond 30Ncm as determined with the torque wrench. The implant was temporised by placing a temporary acrylic crown on the same day by using patient's own pre extraction records (Figure 3a). Her occlusion was adjusted to keep the new implant crown slightly off the centric occlusion and slightly free on lateral excursions. On a subsequent follow up visit at 2 weeks interval, excellent tissue healing was achieved (Figure 3b), so the impression was obtained to fabricate a permanent ceramo-metal crown. The definitive crown was placed using cemented retention (Figure 4a, 4b).

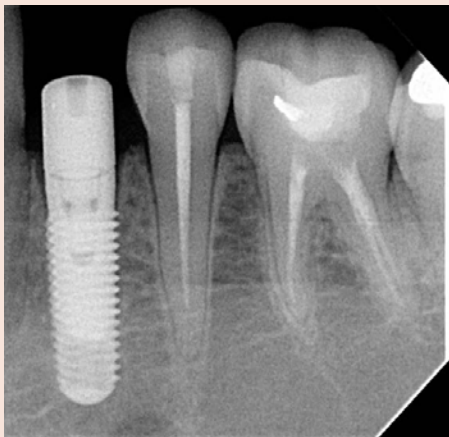
## Discussion

Implant placement in a freshly extracted tooth socket is a challenging task. The proponents of this procedure argue in its

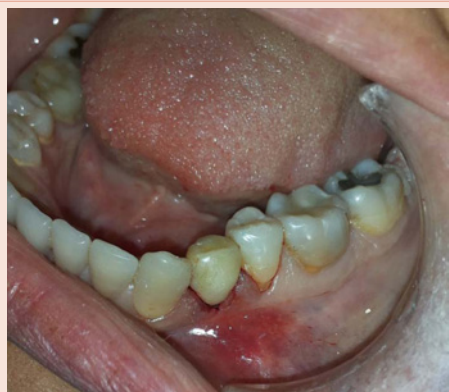favour because of the possibility of alveolar ridge preservation [1] along with better bone dimensions achieved and fewer post-operative complications [3]. The results of implant survival rates in patients with immediate loading protocol versus conventional loading have been similar when careful planning is done to minimize



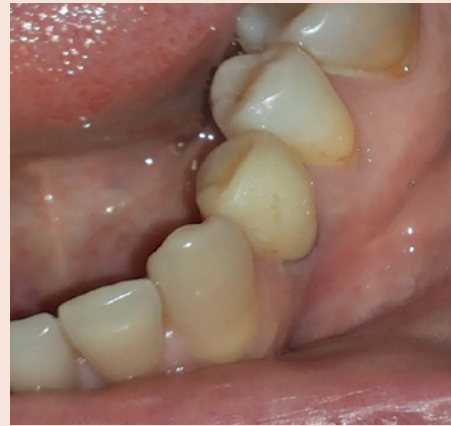**Figure 2a:** Zimmer MTX, 4.7X13 mm implant immediately placed after extraction.



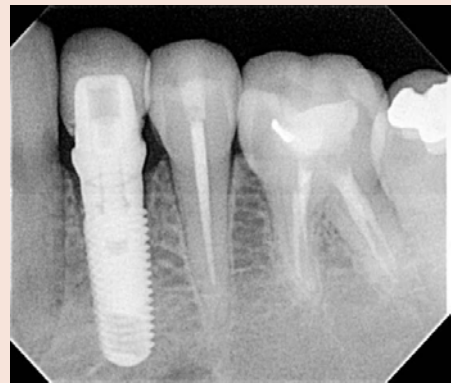
**Figure 2b:** Radiograph of the immediate implant after placement.



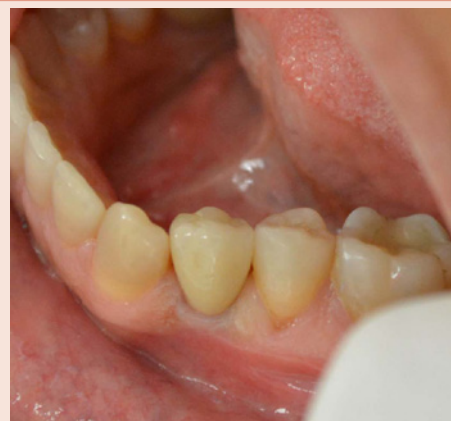**Figure 2c:** After immediate temporization with an acrylic crown.



**Figure 3a:** Excellent tissue healing achieved after 2 weeks of surgery.

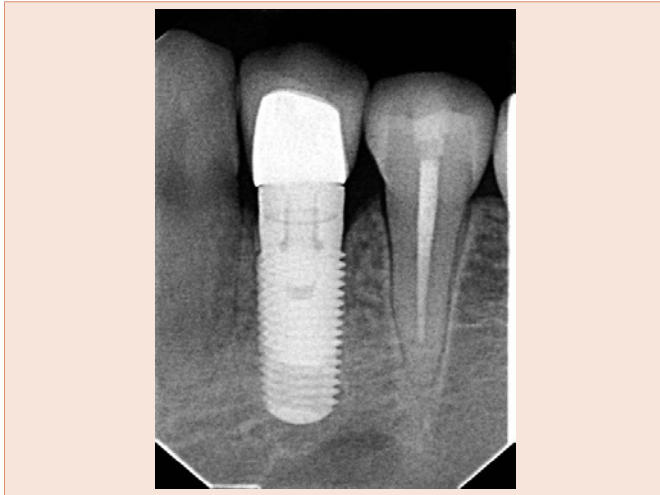

**Figure 3b:** Radiograph of the implant after the cementation of the temporary crown.



**Figure 4a:** After the placement of the permanent crown.

micro movements [4]. Lindeboom in 2006 [5] showed that after 1 year of implant placement, there was no statistically significant difference in gingival esthetics or complications in immediate versus delayed group. In a study by Jo et al. [6]. A success rate of 98.9% was observed for implants that were placed in fresh extraction sockets



**Figure 4b:** Radiograph of the final implant crown.

and immediately loaded. In a randomized clinical trial, [7] one year implant survival rate of immediate implants was found to be 96.6% in immediate loading group and 93.3% in conventional loading group (where loading was done after 3 months). However, several factors are needed to be taken into account when following the immediate protocol of implant placement. These include a surgical technique to ensure primary stability of the implant, sufficient quality and quantity of bone and keeping the implant off occlusion initially to reduce micro movements [8].

Our patient benefited with an esthetic smile as he never remained without the tooth during the entire treatment span. This has an important bearing on the patient from social and psychological stand point. The final crown was fixed within three weeks of surgery as opposed to 12-16 weeks, if a conventional loading protocol would have been followed. An early prosthetic rehabilitation can reduce the anxiety associated with the waiting period [9]. The pain experience was low as all the treatment was completed in a single surgery with minimal tissue damage as there had been no need to raise the flap in the primary surgery and as well for the second stage. Apart from all these, the dentist benefits from improved ergonomics due to the reduction of sitting time.

## Conclusions

Option of immediate placement and loading of implants can be exercised in selected cases. A meticulous case selection and achievement of primary stability in implant is the key to the predictable outcome.

## Acknowledgement

None of the authors have any conflict of interest regarding this paper.

## References

1. Del Fabbro M, Ceresoli V, Taschieri S, Ceci C, Testori T (2013) Immediate Loading of Postextraction Implants in the Esthetic Area: Systematic Review of the Literature. *Clin Implant Dent Relat Res* 12074.
2. Esposito M, Grusovin MG, Maghaireh H, Worthington HV (2013) Interventions for replacing missing teeth: different times for loading dental implants. *Cochrane Database Syst Rev* 3: CD003878.
3. Chen ST, Beagle J, Jensen SS, Chiapasco M, Darby I (2009) Consensus statements and recommended clinical procedures regarding surgical techniques. *Int J Oral Maxillofac Implants* 24: 272-278.
4. Capelli M, Zuffetti F, Del Fabbro M, Testori T (2007) Immediate rehabilitation of the completely edentulous jaw with fixed prostheses supported by either upright or tilted implants: a multicenter clinical study. *Int J Oral Maxillofac Implants* 22: 639-644.
5. Lindeboom JA, Tjook Y, Kroon FH (2006) Immediate placement of implants in periapical infected sites: a prospective randomized study in 50 patients. *Oral Surg Oral Med Oral Pathol Oral Radiol Endod* 101: 705-710.
6. Jo HY, Hobo PK, Hobo S (2001) Freestanding and multiunit immediate loading of the expandable implant: an up-to-40-month prospective survival study. *J Prosthet Dent* 85: 148-155.
7. Shibly O, Kutkut A, Patel N, Albandar JM (2012) Immediate implants with immediate loading vs. conventional loading: 1-year randomized clinical trial. *Clin Implant Dent Relat Res* 14: 663-671.
8. Gapski R, Wang HL, Mascarenhas P, Lang NP (2003) Critical review of immediate implant loading. *Clin Oral Implants Res* 14: 515-527.
9. Glauser R, Sennerby L, Meredith N, Rée A, Lundgren A, et al. (2004) Resonance frequency analysis of implants subjected to immediate or early functional occlusal loading. Successful vs. failing implants. *Clin Oral Implants Res* 15: 428-434.

**Copyright:** © 2015 Khan FR, et al. This is an open-access article distributed under the terms of the Creative Commons Attribution License, which permits unrestricted use, distribution, and reproduction in any medium, provided the original author and source are credited.

**Citation:** Khan FR, Tabassum S (2015) Replacement of A Hopeless Mandibular Tooth With an Immediately Placed and Loaded Dental Implant : A Case Report. *J Dent Probl Solut* 2(1): 005-007. DOI: 10.17352/2394-8418.000007