

Nidhi Gupta¹, Kunwarjeet Singh^{2*} and Sidarth Sharma³

¹Department of Pedodontics and Preventive Dentistry, Institute of Dental Studies and Technologies, Modinagar, Ghaziabad, Uttar Pradesh, India

²Department of Prosthodontics, Dental materials and Implantology, Institute of Dental Studies and Technologies, Modinagar, Ghaziabad, Uttar Pradesh, India

³Department of oral and maxillofacial surgery, Institute of Dental Studies and Technologies, Modinagar, Ghaziabad, Uttar Pradesh, India

Dates: Received: 09 February, 2015; Accepted: 09 March, 2015; Published: 11 March, 2015

*Corresponding author: Dr. Kunwarjeet Singh, Bds, Mds, Department of Prosthodontics, Dental materials and Implantology, Institute of Dental Studies and Technologies, Modinagar, Ghaziabad, Uttar Pradesh, India, Tel: 9911491242; E-mail: drkunwar@gmail.com

www.peertechz.com

ISSN: 2394-8418

Keywords: Hematoma; Posterior superior alveolar nerve; Local anesthesia; Pterygoid plexus of veins

Case Report

Hematoma - A Complication of Posterior Superior Alveolar Nerve Block

Abstract

The administration of anesthesia in dentistry is necessary to prevent pain in specific area of the oral cavity which is accomplished by blocking the branches of the trigeminal nerve. Posterior superior alveolar nerve block is most commonly used for the surgical procedures, extraction or root canal treatment of the maxillary molars (with possible exception of mesiobuccal root of maxillary first molar) and buccal soft tissues. The injection of local anesthesia is usually safe but a rare complication of extraoral hematoma formation in the mandibular lower buccal region might occur due to the insertion of the needle to far posteriorly into the pterygoid plexus of veins, maxillary artery – posterior superior alveolar artery and the facial artery which is esthetically unpleasant to the patient and quite embarrassing for the dentist. This case report describes the complication of posterior superior alveolar nerve block and its management.

Introduction

The unintentional nicking of the blood vessels (artery or vein) with needle during the injection of local anesthesia might result in effusion of blood into the extravascular spaces with subsequent hematoma formation. Puncture of vein by needle may or may not result in the formation of hematoma but perforation of artery subsequently develops hematoma which rapidly increases in size until treatment is instituted due to significantly greater blood pressure within the artery. The size of the hematoma also depends upon the density of the tissues surrounding the blood vessel.

The posterior superior alveolar (PSA) nerve block targets the posterior superior nerve in the infratemporal fossa. It is accomplished by depositing the anesthetic agent along the posterior surface of the maxilla. The needle must be advanced medially, superiorly and posteriorly at a 45 degree angle to the maxillary occlusal plane to reach the infratemporal fossa. The improperly placed posterior superior alveolar nerve block can result in various complications. The hematoma formation due to trauma to the pterygoid plexus of veins is one of the most common complications. A very uncommon and rare complication of Bell's palsy can result due to improper placement of the needle into the inferior part of the parotid gland resulting in the trauma of the cervicofacial division of the facial nerve. This along with trauma of the lateral and medial pterygoid muscles could result in trismus.

The injury of the blood vessel due to penetration of needle to far distally during Posterior superior alveolar nerve block may lead to temporary unaesthetic hematoma [1] extraorally in the lower buccal tissue region of the mandible. The injury of the blood vessel related to this nerve results in effusion of the blood into the infratemporal fossa which accommodates a large volume of the blood from where

it progresses inferiorly and anteriorly towards the lower region of the cheek resulting in the swelling and discoloration of the involved region which occurs within few minutes after completion of the injection.

It is difficult to apply pressure to the bleeding site due to the location of the involved blood vessels which are located posterior, superior and medial to maxillary tuberosity. Bleeding normally stops when external pressure on the blood vessels exceeds the internal pressure or the clotting occurs. The chances of hematoma formation might increase in patients suffering with hematological disorders or condition.

Case Report

A 45 years old female patient reported to our dental centre with chief complaint of severe pain in the maxillary right posterior region which aggravates during sleeping and on intake of the hot food. The clinical and radiographic evaluation reveals carious exposed maxillary right first molar (The intraoral photograph was taken after removal of carious lesion and temporary restoration). The root canal treatment followed by fabrication of the crown was planned for the same. When the local anesthesia was administered for the posterior superior alveolar nerve block, for the RCT of 16, a swelling along with large extraoral discoloration in the mandibular lower region (Figure 1) and a small intraoral hematoma (Figure 2) formation takes place immediately within minutes of administration of anesthesia. The patient became very apprehensive about the unaesthetic appearance of large discoloration on the side of the face. The follow up of the case was done for 4 weeks during which discoloration was completely disappeared within 3 weeks.

Discussion

The posterior superior alveolar nerve is a branch of the maxillary division of the trigeminal nerve. It originates from the main trunk in

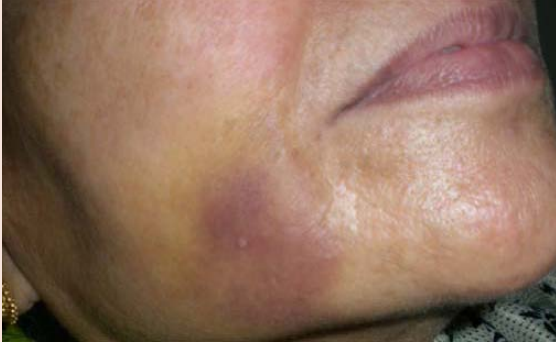


Figure 1: Extraoral hematoma in mandibular lower buccal region.

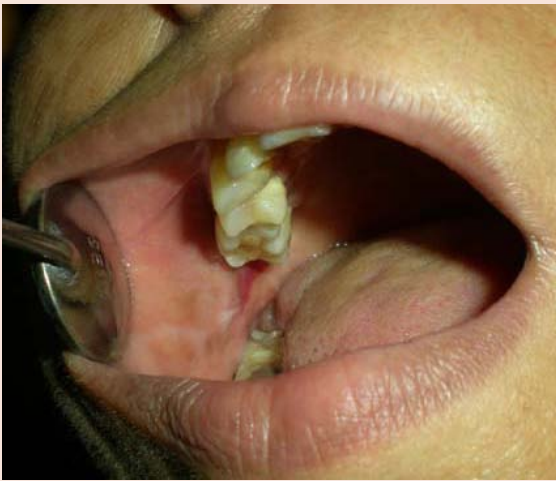

Figure 2: Intraoral hematoma distal to maxillary tuberosity.

the pterygopalatine fossa, passes inferiorly along the posterior wall of the maxilla, and enters the bone about 1 cm superior and posterior to the third molar tooth. This nerve supplies the buccal gingivae, periodontium, and alveolus associated with the upper molar teeth. It provides innervation to the pulps of all the upper molar teeth with the possible exception of the mesiobuccal pulp of the first molar, which is supplied by the middle superior alveolar nerve in approximately 50% of individuals.

The extraoral discoloration on the side of face had great psychological effect on the patient related to the duration of unaesthetic discoloration. The patient is usually very much concerned about the complication and might doubt the capability and experience of the

dentist. The situation is embarrassing for the concerned dentist. So prior information, before injection of local anesthesia to the patient about the possible complication of posterior superior alveolar nerve block is very important to minimize the psychological effect of the complication if it occurs.

The swelling and discoloration of the involved region usually subsides in 10 – 15 days. The patient might also experience soreness and trismus. The patient should be advised to take analgesic, avoid any heat application which might increase the size of the hematoma due to vasodilatation, application of ice immediately after developing hematoma helps in minimizing the size by vasoconstriction and also have palliative effect. Ice packs 30 minutes per hour for the first 24 hours after surgery following which intermittent hot moist packs can be used to resolve the condition [2]. Any dental treatment in the involved region should be avoided until symptoms and signs resolve.

Hematoma place pressure on tissues / wounds, decrease vascularity and increase tension on the wounds edges and also acts as culture media potentiating the development of a wound infection[3] so antibiotic therapy should be prescribed if the hematoma is large.

To prevent formation of hematoma during any nerve block, thorough knowledge of normal anatomy of that particular region is very important. The injection technique can be modified as dictated by the patient's anatomy. The risk of hematoma formation during posterior superior nerve block is highest followed by the inferior alveolar nerve and mental/incisive nerve block. To minimize the risk of hematoma formation, use of short needle and minimum number of needle penetration into tissues should be considered.

Conclusion

The unaesthetic appearance due to the discoloration of the hematoma on the side of face have a great psychological effect on the well being of the patient and embarrassing situation for the dentist. The knowledge of this possible complication for the dentist and prior information to the patient about the same before injection of local anesthesia is very important which helps patient not to lose his/her faith of the administrator. The swelling and discoloration usually subsides in 10 -15 days.

References

1. Stanley F Malamed (2014). Hand book of local anesthesia. Elsevier 6th edition 96.
2. Daniel M Laskin. Oral and maxillofacial surgery. Mosby 2nd edition page 41.
3. Larry J Peterson. Contemporary oral and maxillofacial surgery. Mosby 4th edition page 45.