

Ravindranath Acharya<sup>1</sup>, Syed Mohammed Yaseen<sup>2\*</sup> and Satish Yadav<sup>3</sup>

<sup>1</sup>Assistant professor, Division of Pediatric Dentistry, PullaReddy Dental College & Hospital, Kurnool, India

<sup>2</sup>Assistant Professor, Division of Pediatric Dentistry, College of Dentistry, King Khalid University, Abha, Kingdom of Saudi Arabia

<sup>3</sup>Assistant Professor, Division of oral pathology, Government Dental College, Bellary, India

**Dates:** Received: 09 September, 2014; Accepted: 03 August, 2015; Published: 06 August, 2015

\*Corresponding author: Syed Mohammed Yaseen, Division of Pediatric Dentistry, College of Dentistry, King Khalid University, Abha, Kingdom of Saudi Arabia, E-mail: drsmyom@gmail.com

www.peertechz.com

**Keywords:** Peripheral ossifying fibroma; Gingival overgrowth; Pyogenic granuloma; Peripheral cemento-ossifying fibroma

ISSN: 2394-8418

## Introduction

Peripheral ossifying fibroma (POF) is a relatively common gingival growth that is considered to be reactive in nature and postulated to appear secondary to irritation or trauma. POF is defined as a well demarcated and occasionally encapsulated lesion consisting of fibrous tissue containing variable amounts of mineralized material resembling bone [1]. In 1982 [2] recommended that the only term used to describe this entity should be POF. Clinically, POFs are sessile or pedunculated, usually ulcerated and erythematous or exhibit a color similar to the surrounding gingiva. Most lesions are <2cm in size, although larger ones occasionally occur. Furthermore, the lesions have female predilection and recurrence rate is considered high for benign reactive proliferation. POF is seen usually in teenagers and young adults, with an occurrence peak between the ages of 10 and 19 years. In a literature review revealed the youngest reported age of POF was in a 7-month-old infant. The purpose of this report is to present a case of peripheral ossifying fibroma in a 3 month old infant [3].

## Case Report

A three month old female infant was presented to Division of Pediatric Dentistry, by her parents with a complaint of a lump in her lower front region of the mouth which caused interference in nursing. Child was healthy and history revealed that, she was born, following completion of full term pregnancy without any complication. The only unusual finding at birth was two mandibular anterior natal teeth. Of the two natal teeth, one was extremely mobile and causing discomfort in nursing was extracted when the child was 40 days old. Few days following extraction, a small blister like lesion developed in the extraction site, which gradually increased to present size causing discomfort while nursing. According to the parents, the patient had difficulty when she was nursed because of the lump. Parents were

## Case Report

# Peripheral Ossifying Fibroma in Infant: A Case Report

### Abstract

Peripheral ossifying fibroma is a relatively common gingival growth of reactive rather than neoplastic in nature. Clinically differentiating one from the other as a specific lesion is often difficult and requires histopathology examination. It predominantly affects adolescents and young adults, but rarely seen in infants. We report here a clinical case of peripheral ossifying fibroma in a 3 month old infant. Clinical and histopathological features along with etiopathogenesis and differential diagnosis are also discussed.

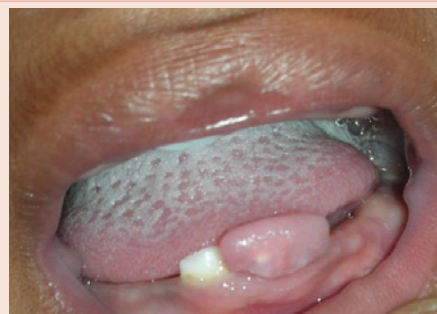very concerned regarding the lesion whether it may affect her facial appearance.

### Clinical Examination

Extra-oral examination revealed no findings of clinical significance. Intra oral examination revealed a fibrous nodular mass with a sessile base in the mandibular anterior region measuring about 0.5 x 1.5 centimetres (Figure 1). The lesion appeared reddish pink with areas of white and rubbery in consistency. The lesion was tender to firm pressure but not to light palpation. However, the lesion was non fluctuant and did not blanch under pressure. Based on these findings and the history, the differential diagnosis consisted of irritation fibroma, pyogenic granuloma, and peripheral giant cell granuloma. Radiographic examination was not attempted as the parents did not want the baby to be exposed to any radiation.

### Treatment

It was decided to excise the lesion and an informed consent was obtained from the parents. A routine blood examination was done, which reflected normal findings. Under local anesthesia, the mass was excised using ligature technique, where the suture was ligated beneath the deeper part of the mass followed by excision of the lesion over the suture material (Figure 2). The tissue was submitted for histopathology examination. Microscopic examination revealed moderately cellular



**Figure 1:** Facial view of the lesion beside natal tooth in mandibular anterior region.

with active, proliferating fibroblast, dense fibrous stroma, with foci of calcified spherules corresponding to irregular bony trabeculae (Figure 3). The histopathological diagnosis was peripheral ossifying fibroma. Post operatively the healing was uneventful and normal (Figure 4). The patient was recalled for a follow up examination thrice after one week, one month and three months. The surgical site appeared healing well with no signs of recurrence.

## Discussion

Localized gingival enlargements are fairly common and typically represent reactive proliferative lesions, rather than true neoplasms [4]. Reactive or inflammatory lesions represent more than 90% of histopathologically analyzed gingival biopsies and most commonly include diagnoses of pyogenic granuloma, fibrous hyperplasia,

peripheral ossifying fibroma and peripheral giant cell granuloma [5]. POF has been cited in the literature under various names such as cemento ossifying fibroma, peripheral fibroma with osteogenesis, peripheral odontogenic fibroma, calcifying fibroblastic granuloma etc [6].

The exact cause for occurrence of POF is difficult to identify. However; it is believed that POF may arise from the gingival fibers of the periodontal ligament as hyperplastic growth of tissue unique to the gingival mucosa. Eversole and Rovin [7] stated that constant irritation present during exfoliation of deciduous teeth and eruption of permanent teeth may result in increased incidence of reactive lesions originating from periodontal ligament. Chronic irritation of the periosteal and periodontal membrane causes metaplasia of the connective tissue and result in initiation of formation of bone or dystrophic calcification. Apart from this, the other possible cited causes include trauma or irritants such as calculus, plaque, microorganisms, dental appliances and ill-fitting crowns.

While POF occurrence is uncommon in infant, it can be considered that the active growth of alveolar bone in the infant jaw, when stimulated by removal of natal tooth, might respond with an exuberant periosteal response and form a reactive lesion with some bone production [8]. As per Buchner and Hansen, the duration of POF can be from 2 weeks to 20 years with a mean of 11.5 months. Bhaskar and Jacoway [9] reported that the average duration of the lesion was 18.6 months.

According to Bodner and Dayan, POF may occur at any age, but rarely occur before age 10 and exhibits a peak incidence between the second and third decades and predominantly in females. There are only 2 reported cases of POF present at birth, presenting clinically as congenital epuli. Buchner and Hansen [10] reported an age range of 7-90 years with a mean age of 30 years, while Kenney [11] reports an incidence age of 5-25 years, with incidence decreasing each year. Zhang et al. [12] in a retrospective study among Chinese population reported the mean age of POF occurrence to be 44 years which is contradictory to previous studies. The lesion affects females more often than males (5:1 respectively). However, in our case POF occurred in 3 month old male infant.

As per Bucher and Hansen, 60% of the POF occur in maxilla, while 40% occur in mandible and 54% in the incisor cuspid region. Kenney et al reported that occurrence was equal in maxilla and mandible with 80% of the lesions occurring in mandibular anterior region, as seen in the present case.

Clinically when such a gingival lesion is presented, it is essential to differentiate it from other remarkably similar lesions such as pyogenic granuloma and Peripheral odontogenic fibroma. Since POF resembles pyogenic granuloma, some consider POF to develop secondary to fibrosis of granulation tissue. POF in some cases may initially develop as a pyogenic granuloma that undergoes subsequent fibrosis, maturation and calcification. The other condition that has to be differentiated is Peripheral odontogenic fibroma (PODF), in that they lack the odontogenic components found in this latter lesion. Histologically, PODF has been defined as a fibroblastic neoplasm containing odontogenic epithelium.

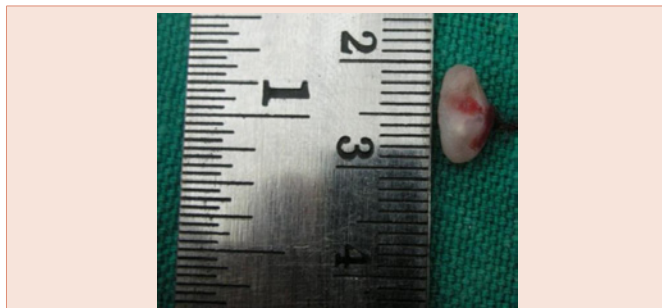


Figure 2: Excised mass.

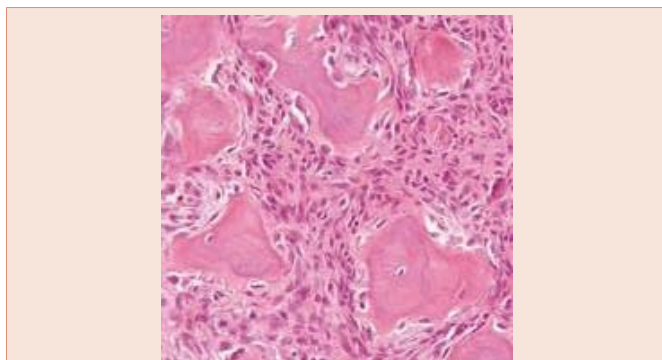


Figure 3: Microscopic picture exhibiting proliferating fibroblast, with foci of calcified spherules.

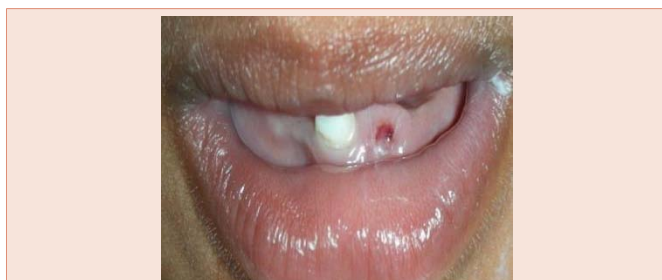

Figure 4: Surgical site following Excision.

Histologically POF can exhibit an intact or ulcerated stratified squamous epithelium with a non-encapsulated mass of cellular fibroblastic connective tissue. As per Buchner and Hansen, in initial stages, the lesion may be ulcerated and composed of cellular fibroblastic tissue with granular foci of dystrophic calcification with pro fused endothelial proliferation in ulcerated areas, leading to misdiagnosis as pyogenic granuloma. The mineralized component can vary from cementum like material, bone or foci of dystrophic calcifications.

The recommended treatment for POF is conservative surgical excision that extends to include the periosteum to reduce the risk of recurrence. In the present case, the excision was done using Ligature technique, where a suture was ligated deep beneath the lesion followed by excision. The reason was to reduce post-operative bleeding as it was difficult for an infant to hold a pressure pack. Moreover the parent were advised to breastfeed the child 10 minutes following the procedure as it can play a role of pressure pack providing hemostasis. Bhaskar and Jacoway reported a recurrence rate of 8%, while Buchner and Hansen reported 16%. Kenney et al reported a recurrence rate of 14%. Since it is a reactive lesion, incomplete removal of the lesion or constant irritation could be attributed for recurrence.

## Conclusion

Clinically, it is difficult to differentiate between most of the reactive gingival lesions. Though POF is uncommon among infants, it should be included in the differential diagnosis when presented as anterior alveolar masses in infants. Moreover the parents are often apprehensive and should be educated and a discussion of differential diagnosis has to be done to allay the distress of the parents. Close post-operative follow up is essential as there can be recurrence on incomplete removal.

## References

1. Waldrom CA (1993) Fibro-osseous lesions of the jaws. *J Oral Maxillofac Surg* 51: 828-835.
2. Gardner DG (1982) The peripheral odontogenic fibroma: an attempt at clarification. *Oral Surg Oral Med Oral Pathol* 54: 40-48.
3. Kohli K, Christian A, Howell R (1998) Peripheral ossifying fibroma associated with a neonatal tooth: case report. *Pediatr Dent* 20: 428-429.
4. Van der Waal I (1991) Non-plaque related periodontal lesions. An overview of some common and uncommon lesions. *J. Clin. Periodontol* 18: 436-440.
5. Bhaskar SN, Levin MP (1973) Histopathology of the human gingiva (study based on 1269 biopsies). *J Periodontol* 44: 3-17.
6. Walters JD, Will JK, Hatfield RD, Cacchillo DA, Raabe DA (2001) Excision and repair of the peripheral ossifying fibroma: A report of 3 cases. *J Periodontol* 72: 939-944.
7. Eversole LR, Rovin S (1972) Reactive lesions of the gingiva. *J Oral Pathol* 1: 30-38.
8. Bodner L, Dayan D (1987) Growth potential of peripheral ossifying fibroma. *J Clin Periodontol* 14: 551-554.
9. Bhaskar SN, Jacoway JR (1966) Peripheral fibroma and peripheral fibroma with calcification: report of 376 cases. *J Am Dent Assoc* 73: 1312-1320.
10. Buchner A, Hansen LS (1987) The histomorphological spectrum of peripheral ossifying fibroma. *Oral Surg Oral Med Oral Pathol* 63: 452-561.
11. Kenney JN, Kaugars GE, Abbey LM (1989) Comparison between the peripheral ossifying fibroma and peripheral odontogenic fibroma. *J Oral Maxillofac Surg* 47: 378-382.
12. Zhang W, Chen Y, An Z, Geng N, Bao D (2007) Reactive gingival lesions: a retrospective study of 2,439 cases. *Quintessence Int* 38: 103-110.
13. Das UM, Azher U (2009) Peripheral Ossifying Fibroma. *J Indian Soc Pedod Prev Dent* 27: 49-51.
14. Feller L, Buskin A, Raubenheimer EJ (2004) Cemento-ossifying fibroma: casereport and review of the literature. *J Int Acad Periodontol* 6: 131-135
15. Neville BW, Damm DD, Allen CM, Bouquot JE. *Soft tissue tumors. Oral and maxillofacial pathology*. 3rd ed. Missouri; Elsevier. P 521-523.
16. Yadav R, Gulati A (2009) Peripheral ossifying fibroma: a case report. *J Oral Sci* 51: 151-154.