

Hanae BOUZIDI\*, Salim Galouj and Fatima Zahra MERNISSI

Department of dermatology, University Hospital Hassan II, Fes, Morocco

**Dates:** Received: 27 January, 2015; Accepted: 30 March, 2015; Published: 31 March, 2015

\*Corresponding author: Hanae BOUZIDI, Boulevard Almadina Lmounaoura, Résidence Bilal, N°10, Hay Amal, Narjiss, Fes, Morocco, E-mail: bouzidi.hanae@gmail.com

www.peertechz.com

ISSN: 2455-8605

## Case Report

# Woman with Giant Lesion in the Trunk

## Introduction

The congenital melanocytic nevus is a type of melanocytic nevus found in infants at birth. This type of birthmark occurs in an estimated 1% of infants worldwide. It may be divided into the Small, medium-sized congenital nevocytic nevus and giant congenital melanocytic nevus also known as "Bathing trunk nevus." We report a case in a 42-year-old woman.

## Case Report

A 42-year-old woman presented to the department of dermatology, reporting a lesion on her trunk (Figure), which had been present since birth and progressively increased in size. No history of new lesions or lesions that have recently increased in size. Physical examination revealed a brown to black lesion occupying the upper half of the front face of the trunk and the entire back, extending to the upper limbs, with many proliferative nodules of varying size, without active bleeding, ulceration, or purulence (Figure 1).

The dermoscopic examination found the presence of globular pattern, homogeneous pattern, points (Figure 2).

In our patient, punch biopsies of the 2 nodular sites were

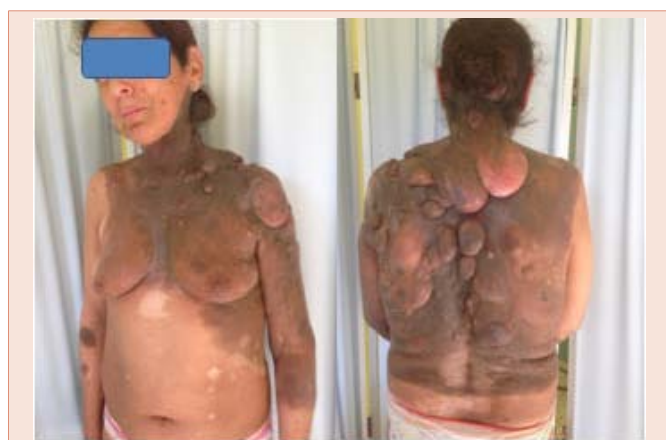

Figure 1: Congenital melanocytic nevus in 42-year-old woman.

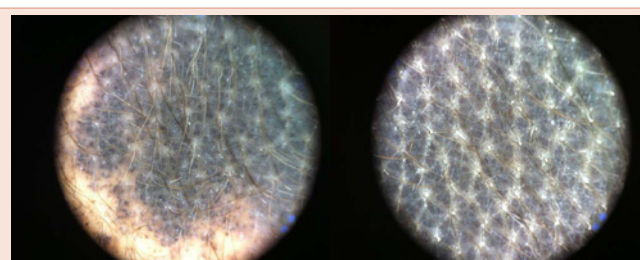


Figure 2: Homogeneous globular pattern with dots at the periphery.

performed. They were most consistent with compound nevus with congenital features, demonstrating mildly thickened epidermis with overlying basket-weave stratum corneum, hyperpigmented basilar keratinocytes, melanocytic hyperplasia of mildly enlarged melanocytes along the dermal-epidermal junction, focal sclerosis, an increased number of vessels, and dermal edema. Single bland-appearing melanocytes were admixed between sclerotic collagen bundles in the superficial and deep dermis. There was no significant evidence of mitotic activity in the dermal melanocytic population.

## Discussion

Large or giant congenital melanocytic nevi affect 1 in 20,000 births and may be disfiguring [1]. Malignant transformation into melanoma is the most common life-threatening complication and occurs in 5% to 8% of cases [2]. Half of these malignant transformations develop by age 5 [2]. Rarely, neurocutaneous melanocytosis, which includes leptomeningeal melanosis and central nervous system proliferation of melanocytes may develop [3]. Individuals with a congenital melanocytic nevus in the posterior axial location and more than 20 satellite nevi have a 5 fold increased risk for neurocutaneous melanocytosis [3,4]. Acceptable treatment options include close observation or surgical excision. Surgical management requires staged surgeries, skin grafting, or tissue expanders [1,2,5].

Our patient received a diagnosis of congenital melanocytic nevus. The lesion had not exhibited recent malignant behavior, we opted for conservative management, clinical and dermoscopic monitoring with threshold for future lesion biopsy.

## References

1. Vourc'h-Jourdain M, Martin L, Barbarot S (2013) Large congenital melanocytic nevi: therapeutic management and melanoma risk: a systematic review. *J Am Acad Dermatol* 68: 493-498.
2. Zaal LH, Mooi WJ, Sillevius Smitt JH, van der Horst CM (2004) Classification of congenital melanocytic naevi and malignant transformation: a review of the literature. *Br J Plast Surg* 57: 707-719.



3. DeDavid M, Orlow SJ, Provost N, Marghoob AA, Rao BK, et al. (1996) Neurocutaneous melanosis: clinical features of large congenital melanocytic nevi in patients with manifest central nervous system melanosis. *J Am Acad Dermatol* 35: 529-538.
4. Bett BJ (2006) Large or multiple congenital melanocytic nevi: occurrence of neurocutaneous melanocytosis in 1008 persons. *J Am Acad Dermatol* 54: 767-777.
5. Gosain AK, Santoro TD, Larson DL, Gingrass RP (2001) Giant congenital nevi: a 20-year experience and an algorithm for their management. *Plast Reconstr Surg* 108: 622-636.

**Copyright:** © 2015 BOUZIDI H, et al. This is an open-access article distributed under the terms of the Creative Commons Attribution License, which permits unrestricted use, distribution, and reproduction in any medium, provided the original author and source are credited.

**Citation:** BOUZIDI H, Galouj S, MERNISSI FZ (2015) Woman with Giant Lesion in the Trunk. *Int J Dermatol Clin Res* 1(1): 007-008. DOI: 10.17352/2455-8605.000002