

Alexander KC Leung<sup>1\*</sup>, Amy AM Leung<sup>2</sup> and Benjamin Barankin<sup>3</sup>

<sup>1</sup>Clinical Professor of Pediatrics, The University of Calgary, Pediatric Consultant, The Alberta Children's Hospital, Calgary, Alberta, Canada

<sup>2</sup>Medical Student, Faculty of Medicine and Dentistry, University of Alberta, Edmonton, Alberta, Canada

<sup>3</sup>Dermatologist & Medical Director, Toronto Dermatology Centre, Toronto, Ontario, Canada

**Dates:** Received: 30 July, 2015; Accepted: 29 August, 2015; Published: 01 September, 2015

\*Corresponding author: Dr. Alexander KC Leung, #200, 233 – 16th Avenue NW, Calgary, Alberta, Canada T2M 0H5, Tel: (403) 230-3322; Fax: (403) 230-3322; E-mail: aleung@ucalgary.ca

[www.peertechz.com](http://www.peertechz.com)

ISSN: 2455-8605

**Keywords:** Subungual hyperkeratosis; Nail-plate crumbling; Nail-plate discoloration; Onycholysis; Onychomycosis

## Case Report

# Psoriasis with Onychodystrophy in a 7-Year-Old Boy

### Abstract

Up to 90% of patients with psoriasis develop onychodystrophy at some point during their lives. Nail involvement precedes the skin lesions in approximately 4% of patients. We herewith report a case of a 7-year-old boy with psoriatic onychodystrophy at the age of 6 years followed by the appearance of plaque psoriasis 6 months later. The psoriatic onychodystrophy was initially misdiagnosed as onychomycosis by his family physician and was treated as such. Psoriatic onychodystrophy can clinically mimic onychomycosis and differentiation of the two conditions can be difficult. We emphasize the need for potassium hydroxide examination and culture of nail scrapings/clippings to demonstrate fungal elements, should there be doubt in the diagnosis.

## Introduction

Psoriasis, a chronic inflammatory immune-mediated disease involving the skin, nails, and the musculoskeletal structures, affects 1 to 3% of the world population [1]. Approximately 25% of patients develop the disease before 20 years of age [2]. It is reported that up to 90% of patients with psoriasis develop onychodystrophy at some point during their lives [3-5]. Nail involvement precedes the skin lesions in approximately 4% of patients [2]. We herewith report a 7-year-old boy who presented with psoriatic onychodystrophy at the age of 6 years followed by the development of plaque psoriasis 6 months later.

## Case Report

A 7-year-old Chinese boy sought medical attention from his family physician a year ago because of nail abnormalities on the hands and feet. He was diagnosed with onychomycosis and was treated with several courses of oral terbinafine without much success and with no adverse reaction. Six months later, he developed a pruritic skin eruption on the scalp and trunk. The skin lesions were erythematous and increased in size and number with time. There was no associated joint pain. His past health was otherwise unremarkable. There was no family history of psoriasis.

The patient was referred to us for consultation at this stage. Physical examination revealed a solitary, discrete, well-demarcated, thick, erythematous plaque with overlying scales on the left frontal scalp and sharply demarcated erythematous plaques with adherent silvery micaceous scales on the trunk. The distal aspects of all digits were erythematous with subungual hyperkeratosis, nail-plate crumbling, yellow nail-plate discoloration, and distal onycholysis (Figure 1). The rest of the physical examination was normal. In particular, there were no signs of psoriatic arthritis.

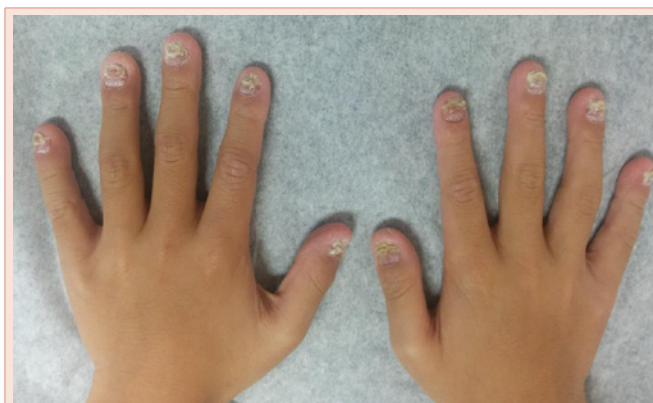
Complete blood cell count and liver function tests were normal.

Antinuclear antibodies (ANA), rheumatoid factor (RF), and anti-citrullinated peptide antibodies (ACPA) were negative. Microscopic examination of potassium hydroxide wet mount preparation of the fingernail scrapings and clippings were negative for fungus. Scrapings and clippings of the fingernails were also sent for fungal culture on Sabouraud's medium and results were negative.

A diagnosis of plaque psoriasis with psoriatic onychodystrophy was made. The patient was treated with methotrexate 7.5 mg orally once weekly, folic acid 5 mg orally daily, and topical calcipotriene-betamethasone dipropionate gel to the nails once daily. Reassessment three months later revealed entirely normal appearing skin without evidence of plaque psoriasis. There was modest improvement in the nail deformities.

## Discussion

Plaque psoriasis or psoriasis vulgaris is characterized by sharply demarcated erythematous plaques with adherent silvery micaceous scales. Removal of the scales results in fine punctate bleeding, which is referred to as the Auspitz sign. The lesions are usually symmetrically



**Figure 1:** Psoriatic onychodystrophy in a 7-year-old child presenting with subungual hyperkeratosis, crumbling, yellow nail-plate discoloration, and distal onycholysis.

distributed and pruritic. Typical sites include the knees, elbows, and lower back. Involvement of the scalp, face, and the intertriginous and diaper areas is more common in infants and young children. Mucosal involvement is unusual. Seronegative inflammatory arthritis develops in about 10 to 30% of patients [2]. Psoriatic arthritis can precede, coincide with, or follow the development of the skin lesions.

Most patients with psoriasis eventually develop nail involvement; both fingernails and toenails can be involved. Conversely, 1 to 5% of patients have isolated nail psoriasis without skin manifestations [4,6]. Nail involvement precedes the skin lesions in approximately 4% of patients [2]. Familiarity with onychodystrophy is important as the presence of nail changes may sometimes facilitate the diagnosis of psoriasis. Onychodystrophy can present as nail pitting, onycholysis, onychorrhexis ("brittle nails"), leukonychia, oil drop discoloration, red spots in the lunula, longitudinal ridging, splinter hemorrhage, nail-plate crumbling, subungual hyperkeratosis, or a combination thereof [1,3,5]. In severe cases, nails may be lost as a result of onycholysis or subungual hyperkeratosis [7].

Another important cause of onychodystrophy is onychomycosis. This is especially so in patients with psoriasis. A recent systematic review of 10 studies showed an average prevalence of 18% of onychomycosis in psoriatic patients [8]. Onychomycosis may present as yellow-brown discoloration and hyperkeratosis of the nail, and onycholysis [9]. Dermatophytes such as *Trichophyton rubrum* and *Trichophyton mentagrophytes* account for 80 to 90% of all cases [9]. Psoriatic onychodystrophy can clinically mimic onychomycosis and differentiation of the two conditions can be difficult. After all, the two conditions may coexist [10]. Onychomycosis has been reported in up to 47% of patients with psoriatic onychodystrophy [10]. As the treatment of the psoriatic onychodystrophy and onychomycosis are different, it is important to rule out onychomycosis in patients with psoriasis as a cause of onychodystrophy and in patients with psoriatic onychodystrophy. In case of doubt, potassium hydroxide examination of nail scrapings/clippings and fungal culture to demonstrate dermatophytic hyphae and arthrospores is the best means of confirming the diagnosis. Fortunately, our patient did not have any adverse reaction to the oral terbinafine prescribed by the family physician for the incorrectly diagnosed onychomycosis.

Psoriatic onychodystrophy has been shown to be associated with widespread and more severe forms of cutaneous psoriasis and quality of life impairment [5,6,11]. Psoriatic onychodystrophy affecting the toenails can alter mobility. It has further been shown that psoriatic onychodystrophy is the strongest predictor for concomitant psoriatic arthritis [2,4,5,12,13]. So far, our patient did not have any evidence of psoriatic arthritis.

## Conclusion

We herewith report a 7-year-old boy with plaque psoriasis and onychodystrophy. The development of onychodystrophy preceded the skin lesions. Because psoriatic onychodystrophy can mimic onychomycosis and the two conditions may coexist, we emphasize the need for potassium hydroxide examination and fungal culture of nail scrapings/clippings to demonstrate dermatophytic hyphae and arthrospores, should there be doubt in the diagnosis.

## References

1. Al-Mutairi N, Manchanda Y, Nour-Eldin O (2007) Nail changes in childhood psoriasis: a study from Kuwait. *Pediatr Dermatol* 24: 7-10.
2. Leung AK, Robson WL (2009) Psoriasis. In: Lang F, ed. *The Encyclopedia of Molecular Mechanisms of Disease*. Berlin: Springer-Verlag 1750-1751.
3. Schons KR, Beber AA, Beck Mde O, Monticelo OA (2015) Nail involvement in adult patients with plaque-type psoriasis: prevalence and clinical features. *An Bras Dermatol* 90: 314-319.
4. Tan ES, Chong WS, Tey HL (2012) Nail psoriasis: a review. *Am J Clin Dermatol* 13: 375-388.
5. van der Velden HM, Klaassen KM, van de Kerkhof PC, Pasch MC (2013) Fingernail psoriasis reconsidered: a case-control study. *J Am Acad Dermatol* 69: 245-252.
6. Augustin M, Reich K, Blome C, Schäfer I, Laass A, et al. (2010) Nail psoriasis in Germany: epidemiology and burden of disease. *Br J Dermatol* 163: 580-585.
7. de Berker D (2009) Management of psoriatic nail disease. *Semin Cutan Med Surg* 28: 39-43.
8. Klaassen KM, Dulak MG, van de Kerkhof PC, Pasch MC (2014) The prevalence of onychomycosis in psoriatic patients: a systematic review. *J Eur Acad Dermatol Venereol* 28: 533-541.
9. Hoy NY, Leung AK, Metelitsa AI, Adams S (2012) New concepts in median nail dystrophy, onychomycosis, and hand, foot, and mouth disease nail pathology. *ISRN Dermatology* 680163.
10. Natarajan V, Nath AK, Thappa DM, Singh R, Verma SK (2010) Coexistence of onychomycosis in psoriatic nails: a descriptive study. *Indian J Dermatol Venereol Leprol* 76: 723.
11. Klaassen KM, van de Kerkhof PC, Pasch MC (2014) Nail psoriasis, the unknown burden of disease. *J Eur Acad Dermatol Venereol* 28: 1690-1695.
12. Langenbruch A, Radtke MA, Krensel M, Jacobi A, Reich K, et al. (2014) Nail involvement as a predictor of concomitant psoriatic arthritis in patients with psoriasis. *Br J Dermatol* 171: 1123-1128.
13. Raposo I, Torres T (2015) Nail psoriasis as a predictor of the development of psoriatic arthritis. *Actas Dermosifiliogr* 106: 452-457.

**Copyright:** © 2015 Leung AKC, et al. This is an open-access article distributed under the terms of the Creative Commons Attribution License, which permits unrestricted use, distribution, and reproduction in any medium, provided the original author and source are credited.

**Citation:** Leung AKC, Leung AAM, Barankin B (2015) Psoriasis with Onychodystrophy in a 7-Year-Old Boy. *Int J Dermatol Clin Res* 1(2): 016-017. DOI: 10.17352/2455-8605.000007