

Subekcha Karki^{1*} and Ma Luisa Abad-Venida²

¹Resident, Department of Dermatology, Jose R Reyes Memorial medical Centre, Manila, Philippines

²Consultant, Research and Training Officer, Jose R Reyes Memorial medical Centre, Manila, Philippines

Dates: Received: 10 August, 2015; Accepted: 22 September, 2015; Published: 25 September, 2015

***Corresponding author:** Subekcha Karki, MD, Assistant Dermatologist to the Chair, Di Skin Hospital, Maharajgunj, Kathmandu, Nepal, E-mail: doctorakarki@gmail.com

www.peertechz.com

ISSN: 2455-8605

Keywords: Actinomycetoma; Trimethoprim-sulfamethoxazole (SMX+TMP)

Case Report

A Case of Actinomycetoma Treated with Trimethoprim + Sulfamethoxazole

Abstract

A 32-year-old man presented with a history of progressive, painful nodular growths with discharge consisting granules over the right thigh, inguinal area and right foot. Histopathological examination of the tissue biopsy was actinomycotic mycetoma. The patient showed improvement with trimethoprim-sulfamethoxazole. The novelty of our case is to use Co-trimoxazole as a first line treatment modality for cases diagnosed or suspected as actinomycetoma.

Introduction

Actinomycetoma is a chronic suppurative and or granulomatous infectious process caused by aerobic filamentous bacteria. Actinomycetomas are caused by members of genus *Nocardia*, *Streptomyces*, *Nocardiosis*, and *Actinomadura*.

The term mycetoma, coined by Vandyke Carter in 1860, suggests a fungal growth; however, aerobic filamentous bacteria cause most cases worldwide [1]. We report an advanced stage of actinomycetoma. To the best of our knowledge cure is possible, although a prolonged period is needed. Recurrence is common after an incomplete or irregular course of medical treatment.

There are no existing acceptable treatment protocols or guidelines for mycetoma. The available treatment options are based on personal experience, preference and drug availability.

Case

A 32-year-old Filipino male who worked as a farmer and a food-vendor, from Tondo, Manila presented with a history of progressive multiple nodules over the right lower limb associated with seropurulent discharge.

Eight years prior to consultation, patient had penetrating injury by a bamboo stick over the right foot, after which he developed a solitary mass measuring approximately 1x1cm gradually increasing in number and size. Surgical consultation was done and underwent tumor excision and split thickness skin graft from the right thigh. I.V. antibiotics were given post-surgically for a week and oral-antibiotics continued for a week more. He was asymptomatic for 8 years after which he sought medical consult, when there was difficulty in breathing, progressive multiple nodules over the right-foot, right-thigh and right-inguinal area associated with seropurulent discharge. He was confined in Internal Medicine and co-managed with Orthopedics with assessment to consider Osteosarcoma right leg.

Laboratory investigations revealed a decrease in hemoglobin

104g/dL (n.v 135-180g/dL) and hematocrit 0.40-0.54% (n.v 0.25%), leucopenia 21.05 (n.v 5-10 X 10⁹). Urinalysis revealed normal results.

It was essential to carry out HIV serology in our patients, according to the patient his HIV serology was done few months prior and was negative but the results were not available, hence not repeated.

His Chest X-ray PA and Lateral view revealed pleural effusion vs. pleural thickening right, PTB R. upper lobe, pleurodiaphragmatic

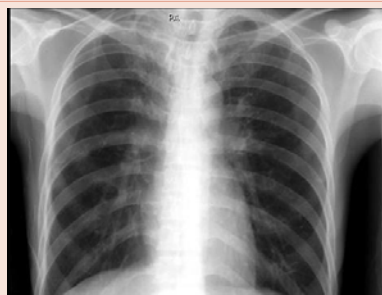

Figure 1: Chest X-ray PA view: Pleural effusion vs pleural thickening right.

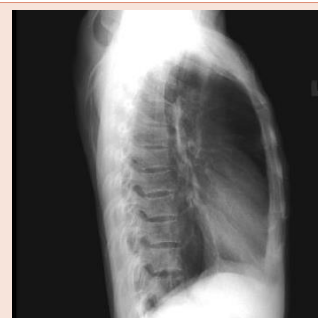

Figure 2: Chest X-ray Lateral view: Pulmonary Tuberculosis right upper lobe, Pleurodiaphragmatic adhesion bilateral.

adhesion bilateral. X-ray of the pelvis suggested arthritic hip, probably infectious in origin and R. foot revealed soft tissue masses in the 1st & 2nd intradigital space, beginning osteomyelitis 2nd metatarsal right (Figures 1-4).

Patient was also referred to our service for further evaluation and management, hence; this consultation.

The systems review revealed pallor and weight loss. Patient was non-hypertensive and non-diabetic, but history of pulmonary tuberculosis four-years back for which he was treated with Anti-Koch's drugs for 1 year. Past history of penetrating injury by a bamboo stick over the right foot. He was smoker with four-pack years, occasionally drank alcoholic beverages and admitted to have only one-sexual partner (wife). He lived with nine-other family members in a crowded environment. There was no similar illness in his family. He had been working as a farmer in the province until he moved to Manila and became a food-vendor. He admitted to being a habitual barefoot walker.

The patient had Blood pressure of 100/70mm Hg, heart rate 89bpm, respiratory rate of 28/min and temperature of 36.5°C. He had pale palpebral conjunctiva.

On dermatological examination, he was found to have multiple, ill-defined, soft to firm, confluent erythematous nodules productive of seropurulent discharge associated with tenderness and swelling over the anterior right thigh and right foot (Figures 5-7).

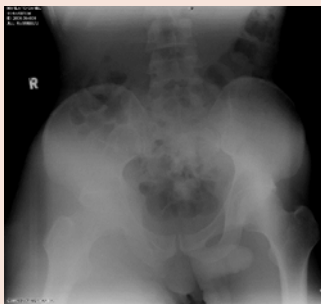


Figure 3: X-ray Pelvis: Consider arthritic hip, probably infectious in origin.

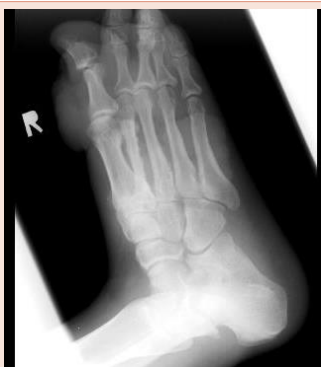

Figure 4: X-ray Right foot: Soft tissue masses in the 1st & 2nd intradigital space, beginning osteomyelitis 2nd metatarsal right.

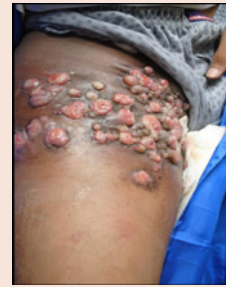

Figure 5: Lesions over the Right-Thigh spreading towards the inguinal area.

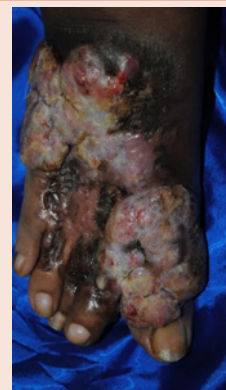

Figure 6: Lesions over the Right-foot.

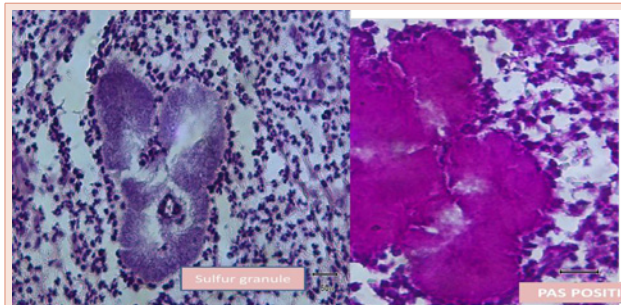


Figure 7: Characteristic sulfur granules which stained positive for Periodic Acid Schiff Stain.

The findings on an incision biopsy on the right-thigh revealed Actinomycetoma. The epidermis showed presence of pseudocarcinomatous hyperplasia, parakeratosis, and presence of sulfur granules. The dermis showed dilated capillaries along with sulfur granules, neutrophils, lymphocytes and plasma cells. Periodic Acid Schiff Stain (PAS) of the sulfur-granules was suggested. PAS stain was positive. Fungal culture suggested was done showed no growth after 4days incubation.

Discussion

Actinomycetoma is a non-contagious chronic infection, characterized by the triad of localized lesions, tumefactions, and

multiple draining sinuses. It involves the cutaneous, subcutaneous tissues, fascia and bone. The exudates contain grains, which may be yellow, white, red, brown, or black depending on the causative agent.

Mycetoma is classified as Eumycetoma or true-mycetoma caused by fungi and Actinomycetoma caused by aerobic filamentous bacteria. Actinomycetomas are caused by members of genus *Nocardia*, *Streptomyces*, *Nocardiosis*, and *Actinomadura*.

The term mycetoma, coined by Vandyke Carter in 1860, suggests a fungal growth; however, aerobic filamentous bacteria cause most cases worldwide [2]. It has a worldwide distribution, with preponderance over the tropics and sub-tropics. The disease has also been reported in areas of temperate climate. It is predominantly a disease of men in rural areas, who work bare foot on land such as cultivators and daily laborers [3]. Poor hygiene, low socioeconomic status and low nutrition are suggested risk factors [4].

The causative organism is usually found in the soil and enters the host through a breach in the skin or the mucosal membrane by sharp objects. The legs and feet are most commonly affected sites. Organisms gain entry into the skin through traumatic inoculation causing localized infection that is focally aggressive but does not typically disseminate. Early diagnosis and treatment can affect morbidity associated with this condition. Thus, it is important for clinicians to be aware of this disorder's clinical presentation and methods available for confirming the diagnosis [5,10].

Clinically, patients experience formation of erythematous papulonodules with drainage of purulent material and sinus tract formation. Ultimately, fibrosis and destruction of underlying soft tissue and bone will ensue. Severe edema and regional lymphadenopathy are common as the disease progresses.

Beyond the clinical appearance, histopathological analysis of affected skin is a critical step. A reaction pattern of granulomatous inflammation, abscess formation and fibrosis is typical [6,8]. The presence of the sulfur granules, on examination of smears of the discharge or tissue biopsy confirms the diagnosis of mycetoma.

Treatment regimens vary according to the organism causing the infection. The duration of treatment is dictated by the clinical response to medication, but reported cure rates are 60-90 percent with a mean duration of therapy longer than one year. Second-line treatment includes minocycline, co-amoxiclav, amikacin, cefuroxime, ceftriaxone, quinolones, imipenem, and linezolid. Involvement of underlying bone often requires more aggressive measures, including surgical debridement or even amputation of the affected areas [7,9,11].

Actinomycetoma lesions involving soft tissues are only mildly painful; those affecting bones or joints are more so. Systemic symptoms are absent or minimal.

“There are no existing acceptable treatment protocols or guidelines for mycetoma, and the available treatment options are based on personal experience, preference and drug availability. The novelty of our case is to use Co-trimoxazole as a first line treatment modality for all case diagnosed or suspected as actinomycetoma.

Because of the associated potential morbidities, empiric treatment based on clinical and histological findings alone should be initiated, even if specific microbiologic confirmation cannot be obtained. Also because studies have stated that; actinomycetomas are more responsive to antibiotics.”

Our patient's incision biopsy showed the presence of sulfur grains, positive PAS stain. Fungal culture was negative. These features were consistent with actinomycetoma. Incision and Trochar biopsy as suggested by the department of Orthopedics was done to rule out Osteosarcoma. Results revealed soft tissue mass, epidermal inclusion cyst, infected acute and chronic inflammation and granulation tissue formation; final result ruled out osteosarcoma.

Thus based on the radiological findings and the staging according to bone involvement, our patient is Stage4 i.e. longitudinal spreading along a single ray [12].

The patient was then started on SMX-TMP 800/160mg one tablet three times a day together with supportive therapy consisting of Multivitamin 1 capsule two times a day, Ferrous sulfate 1 capsule twice a day, and Tramadol + Paracetamol 500mg one tablet as needed for pain. Wound care was with Potassium permanganate (kmno4) compress two times a day for ten minutes followed by application of tetracycline ointment.

He was on regular follow up every two weeks. Four months after treatment, marked improvement was seen with decreased discharge, drying up of lesion, ease of pain on ambulation.

Although compliant with medications new lesions, discharge and painful ambulation observed on his third-month of follow-up. As revealed by the patient there was shift of the medication from a branded to a generic brand due to economic constraints.

However, when SMX+TMP was shifted back to the previous brand, good response regarding decrease in the discharge, drying up of lesions with no new lesions was observed (Figures 8-11).

Unfortunately, two weeks later; patient died while at home. He was still being treated with SMX+TMP for past 6 months. According to the death certificate death due to cardiopulmonary arrest 2^o to hypovolemic shock and underlying chronic anemia.

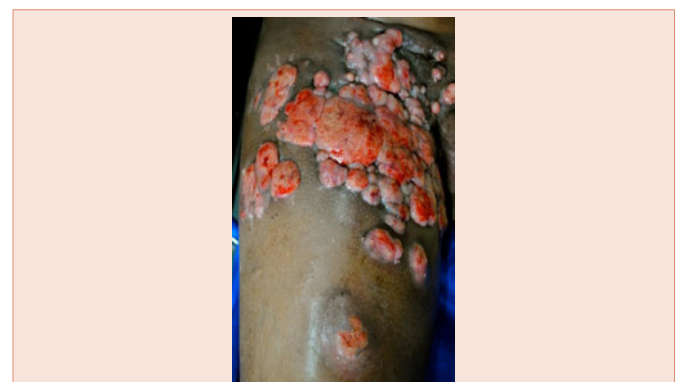

Figure 8: New lesions over the right thigh with discharge.

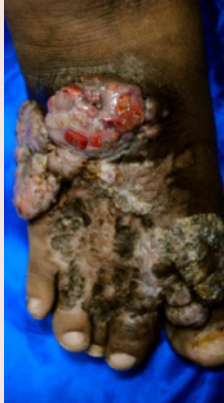

Figure 9: Discharge from the lesions over the right foot.

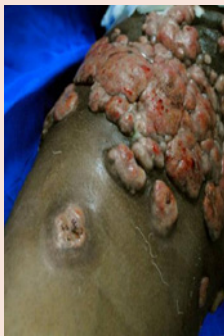

Figure 10: Improvement of lesions over right thigh and inguinal area, 3weeks after restarting SMX+TMP to the original brand.

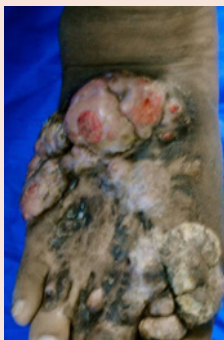

Figure 11: Improvement of lesions over right foot, 3weeks after restarting SMX+TMP to the original brand.

Acknowledgement

This case report would not have been possible without the help of Ma. Flordeliz Casintahan, MD, FPDS, and Dr. Daisy. K. Ismael, MD, FPDS; the histopathologists who signed our case as actinomycetoma; my senior A. Venida M.D. JRRMMC, who helped me manage this case regularly. My consultant; Dra. Elizabeth Tianco, MD, FPDS who inspired me to submit this case report and Dr. A.K. Jha Head of Department NMCTUTH, Founder Chairman DI Skin Hospital and Research Center, Maharajgunj; who inspired me to pursue my medical career as a Dermatologist.

References

1. Tellez I, Franco-Paredes C (2010) A Woman with Chronic, Subcutaneous Swelling og the Right Foot associated with sinus Tracts Discharging Yellow Granules. *PLoS Negl Trop Dis* 4: e772.
2. MEDSCAPE, Author: Basilio J Anía, MD Associate Professor of Infectious Diseases, Universidad de Las Palmas de Gran Canaria; Consultant in Internal Medicine, Hospital Universitario Dr. Negrín, Spain Raphael J Kiel, MD is a member of the following medical societies: American College of Physicians-American Society of Internal Medicine and American Geriatrics Society.
3. Turiansky GW1, Benson PM, Sperling LC, Sau P, Salkin IF, et al. (1995) Phialophora verrucosa: A new cause of mycetoma. *J Am Acad Dermatol* 32: 311–315.
4. Mcgininis MR, Fader RC (1988) Mycetoma: a contemporary concept. *Infect Dis Clin North Am* 2: 939–954.
5. Yaghoobi R, Ranjbari N, Rasaii S (1999) Actinomycetoma. Report of 4 cases of mycetoma from Khoozestan (Ahwaz). *Quarterly dermatology Journal* 2: 43–48.
6. Klokke AH, Swamidasan G, Anguli R, Verghese A (1968) The causal agents of mycetoma in South India. *Trans R Soc Trop Med Hyg* 62: 509–516.
7. Ameen M, Arenas R (2008) Developments in management of mycetomas. *Clin Exp Dermatol* 34: 1-7.
8. Desai SC, Pardanani DS, Sreedevi N, Mehta RS (1970) Studies on mycetoma. Clinical, mycological, histologic, radiologic studies on 40 cases of mycetoma with a note on its history and epidemiology in India. *Indian journal of surgery* 32: 427–447.
9. Mahgoub ES (1976) Medical management of mycetoma. *Bulletin of the World Health Organization* 54: 303–310.
10. Keng-Ee Thai (2008) Fitzpatrick's Dermatology in General Medicine 7th edition. *Australasian J Dermatol* 49: 175.
11. Ahmed Hassan Fahal (2010) Management of Mycetoma. *Expert Rev. Dermatol* 5: 87-93.
12. Basilio J Anía, et al. (1995) Mycetoma. *Emed.com staging of actinomycetomas.*