

Peter Torok*

Department of Obstetrics and Gynecology, Clinical Center, University of Debrecen, Hungary

Dates: Received: 19 April, 2016; Accepted: 29 April, 2016; Published: 2 May, 2016

*Corresponding author: Peter Torok, Department of Obstetrics and Gynecology, Clinical Center, University of Debrecen, Hungary, E- mail: drtorokp@freemail.hu

www.peertechz.com

Research Article

A Novel Method of Selective Chromopertubation at Office Hysteroscopy

Abstract

Introduction: Tubal dysfunction is diagnosed as an underlying cause of infertility in more than one third of cases. Laparoscopy dye is the gold standard procedure to detect tubal patency, but hysterosalpingography (HSG) and hystero-contrast-sonography (HyCoSy) is also used. Office hysteroscopy guided selective chromopertubation (OHSC-SPT) is a less invasive and reproducible method, which can be performed in an outpatient setting without anesthesia, therefore it can be carried out as an outpatient procedure.

Method: For the examination an office hysteroscope is used. A 1.7 mm diameter flexible plastic catheter is inserted through an inbuilt channel of the sheath. Normal saline is used for distention. The hysteroscope is introduced without grasping or dilatation of the cervix. First, diagnostic hysteroscopy is performed, then the catheter is inserted through the working channel and the tip of it is placed into the tubal orifice, through which methylene blue dye is injected slowly. If the tube is patent the blue dye does not appear in the uterine cavity and the normal color of the endometrium is seen. In case of tubal occlusion the distention media of the uterine cavity turns blue, due to the back-flow of the methylene blue.

Conclusion: After gathering additional experience the novel method of OHSC-SPT could be considered as an effective, minimally invasive method to investigate tubal patency, which can be performed in an office setting without anesthesia.

Introduction

Tubal dysfunction is a leading factor in female infertility, diagnosed in 30-50% of infertile patients [1]. The assessment of the tubal patency is necessary prior to the therapy, to define the type of assisted reproductive technique or tubal reconstructive surgery. Laparoscopic chromohydrotubation is the gold standard [2], to detect tubal patency, but hysterosalpingography (HSG) and hystero-contrast-sonography (HyCoSy) is also widely accepted. For HSG X-ray examination is needed which can be harmful despite its low dosage. HSG and the HyCoSy are not accurate enough [3], due to their lower specificity and sensitivity. For laparoscopic surgery general anesthesia, hospitalization and an operating room is compulsory which increases the costs of the procedure and strain for the patient [4].

We developed a less invasive, nevertheless effective and reproducible method, which can be performed in an outpatient setting without anesthesia. Office hysteroscopy guided selective chromopertubation (OHSC-SPT) can be applied as an outpatient procedure. In case of negative results more invasive and expensive laparoscopic surgery is avoidable.

Method

The procedure is performed in an outpatient setting. Patient is in dorsal lithotomy position. Modified no-touch technique is performed using Cusco instrument and thorough disinfection of the vagina and the portio. Hysteroscope is inserted without grasping, or dilatation of the cervix. A 2.7 mm rigid optic is used for the examination, with a

5.5 mm sheath (EMD Endoscopy Technologies). Normal saline (0.9% sodium chloride) is used for the distention, at controlled intrauterine pressure of 80-100 Hgmm. A digital camera is connected to the optic, so the results can be objectively evaluated and documented. The examination begins with a routine office hysteroscopy, during which any deformity of the uterine cavity and the endometrium can be visualized.

Technique of pertubation

In the second step a 1.7 mm plastic catheter (Cavafix, B-Braun) is inserted through the working channel of the sheath and the tip is placed to the tubal ostium (Figures 1,2). During selective pertubation, each Fallopian tube is considered as a diagnostic unit. By rotating the hysteroscope, the direction of the catheter can be modified toward the ostium. The cone shape of the tubal ostium will help in leading the tip of the flexible catheter into the ostium. The catheter should not to be inserted into the tube, only the tip should be placed at the entry of it. Through the catheter 2-10 ml of methylene blue dye (Patente Blue, 2 ml in 1000 ml saline) is injected slowly. In case of a patent Fallopian tube no blue fluid will appear in the uterine cavity. Normal color of the endometrium can be seen, while the transparent catheter turns blue, due to the methylene blue flowing inside it (Figure 3). Occluded Fallopian tube changes the uterine cavity into blue, due to the back-flow of the methylene blue (Figure 4). In case of corneal occlusion, blue dye will flow back immediately. If the blockage is at the distal part of the tube, the first fraction of the blue dye will disappear and after some time of the injection will the back-flow be detectable. After the evaluation of tubal patency, blue dye clears up within 5-10 seconds

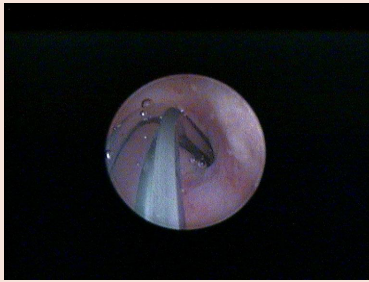


Figure 1: In the second step a 1.7 mm plastic catheter (Cavafix, B-Braun) is inserted through the working channel of the sheath and the tip is placed to the tubal ostium.

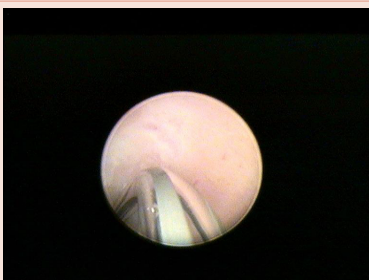

Figure 2: In the second step a 1.7 mm plastic catheter (Cavafix, B-Braun) is inserted through the working channel of the sheath and the tip is placed to the tubal ostium.

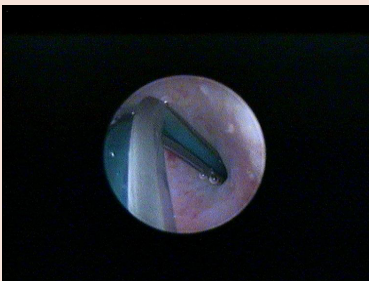


Figure 3: Normal color of the endometrium can be seen, while the transparent catheter turns blue, due to the methylene blue flowing inside it.

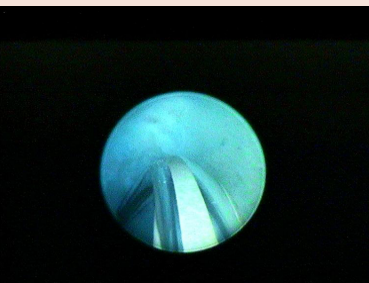


Figure 4: Occluded Fallopian tube changes the uterine cavity into blue, due to the back-flow of the methylene blue.

and the whole procedure can be repeated on the other side. To be more exact and precise, transvaginal ultrasound examination should be performed before and after the hysteroscopy. This examination can exclude any pathology of the tubes that can cause false negative results, for example hydrosalpinx. By detecting free fluid around the ovaries and in the pouch of Douglas, the result of the perturbation can be verified. Total examination time is 4-8 minutes. As usual after office hysteroscopy, there is no need for post-operative observation, and the procedure can be performed with a high patient compliance [5].

After the comparative study 65 analyzed examinations were performed. All examinations happened as a part of the infertility work-up. Following the protocols hysteroscopy was scheduled for the follicular phase, without anesthesia and having negative functional results. At least one tube was patent in 37 cases. There was no complication during or after the procedures. During an 18 months follow-up period, 8 patients conceived spontaneously.

Conclusion

During infertility work-up, evaluation of tubal patency is a cardinal point. Blockage of both tubes leads to either IVF treatment or consideration of tubal reconstructive surgery. Both therapeutic ways have high costs and risks of complications. Answering this question laparoscopic surgery should be chosen as a gold-standard method. Knowing the disadvantages of an abdominal surgery with general anesthesia, timing of the examination is questionable. The novel method of OHSC-SPT seems to be an effective, accurate, minimally invasive method to investigate tubal patency. Without using anesthesia and an operating room, costs can be reduced significantly. As an outpatient method, it has minimal strain for the patient. Performing more procedures and analyzing the results could lead to being accepted as effective, precise and reproducible as laparoscopy. To evaluate sensitivity and specificity of the new method a comparative study was performed and results show that it is precise and accurate compared to the laparoscopic examination that is used as the “golden standard” worldwide [6]. Laparoscopic surgery should be worth considering only in cases of blockage in both tubes.

References

1. Watrelot A, Hamilton J, Grudzinskas JG (2003) Advances in the assessment of the uterus and fallopian tube function. *Best Pract Res Clin Obstet Gynaecol* 17: 187-209.
2. Jayakrishnan K, Koshy AK, Raju R (2010) Role of laparohysteroscopy in women with normal pelvic imaging and failed ovulation stimulation with intrauterine insemination. *J Hum Reprod Sci* 3: 20-24.
3. Papaioannou S, Bourdrez P, Varma R, Afnan M, Mol BW, et al. (2004) Tubal evaluation in the investigation of subfertility: A structured comparison of tests. *BJOG* 111: 1313-1321.
4. Marsh F., Kremer C., Duffy S (2004) Delivering an effective outpatient service in gynaecology. A randomised controlled trial analysing the cost of outpatient versus daycase hysteroscopy. *BJOG* 111: 243-248.
5. Campo R, Van Belle Y, Rombauts L, Brosens I, Gordts S (1999) Office mini-hysteroscopy. *Hum Reprod Update* 5: 73-81.
6. Török P, Major T (2012) Accuracy of assessment of tubal patency with selective perturbation at office hysteroscopy compared with laparoscopy in infertile women. *J Minim Invasive Gynecol* 19: 627-630.

Copyright: © 2016 Torok P. This is an open-access article distributed under the terms of the Creative Commons Attribution License, which permits unrestricted use, distribution, and reproduction in any medium, provided the original author and source are credited.

Citation: Torok P (2016) A Novel Method of Selective Chromoperturbation at Office Hysteroscopy. *J Gynecol Res Obstet* 2(1): 031-032.