

Giorgio Bianciardi^{1*}, Maria Eugenia Latronico² and Claudio Traversi²

¹Department of Medical Biotechnologies, University of Siena, Siena, Italy

²Department of Medical Sciences, Surgery and Neurosciences, University of Siena, Siena, Italy

Dates: Received: 30 January, 2016; Accepted: 03 March, 2016; Published: 07 March, 2016

*Corresponding author: Bianciardi Giorgio, MS, MD, PhD, Department of Medical Biotechnologies, University of Siena, Siena, Italy, E-mail: giorgio.bianciardi@unisi.it

www.peertechz.com

ISSN: 2455-4634

Keywords: Mass dimension; Fractal analysis; Optic neuritis; Nonarteritic anterior ischemic optic neuropathy; Differential diagnosis

Research Article

Mass Dimension Evaluation of the Optic Nerve Head Microvasculature in Non-Glaucomatous Optic Neuropathies

Abstract

In several diseases, fractal analysis has been proven useful to give contribution in diagnosis and prognosis of the patient and to improve treatments. In the present work we have evaluated the mass dimension of the vascular pattern of optic nerve head in non-glaucomatous optic neuropathic patients and healthy controls. Static fluorescein angiogram was performed and the images of the early venous phase were saved. A manual outline of the trajectories of the two-dimensional vascular network was performed down to vessels of 20 micron diameter, processed to threshold the vessel network without background interference and converted into an outline of single pixels and then the fractal analysis was performed. Mass dimension evaluation of the optic nerve head microvasculature was able to differentiate health condition vs. non-glaucomatous neuropathies ($p < 0.01$), as well optic neuritis vs. nonarteritic anterior ischemic optic neuropathy ($p < 0.01$), with high sensitivity and specificity ($p < 0.0001$; $p < 0.0001$). Mass dimension index shows a significantly increased vascular complexity of the optic nerve head in cases compared with controls, also permitting to distinguish between patients affected by optic neuritis vs. nonarteritic anterior ischemic optic neuropathy. This new, fast, inexpensive, methodology may be used in helping the clinician to perform the differential diagnosis between the pathologies and to study the effect of therapies during the follow up of the patient.

Introduction

Fractal analysis is a very useful tool in the understanding of many phenomena in various fields, such as astrophysics, economics, biology and medicine. Interesting results have also been achieved in bacteriology, medical imaging and ophthalmology (e.g. diabetic retinopathy) [1-6].

Retinal vascular network in healthy subjects has a value of fractal dimension [7], close to the value of a Diffusion-Limited Aggregation (DLA) process ($D \approx 1.70$) [8], while in pathologic condition that value changes deeply. We can recall papers by Cavallari et al. [9], that showed a reduction in complexity of retinal vessels, reflecting the alteration of the brain microvessels in patients with cerebral autosomal dominant arteriopathy with subcortical infarcts and leukoencephalopathy (CADASIL) and the ones by Doubal et al. [10], that found a low value of retinal vessels fractal dimension associated to the lacunar stroke and by Talu et al. that, recently, showed that fractal analysis is able to characterize the human non-proliferative diabetic retinopathy [11]. In these works, fractal analysis has been demonstrated a sensitive tool to assess changes of retinal vessel branching, able to reflect the early microvessel alterations in human pathology. Moreover, the retina vessels network, described by generalized dimensions and singularity spectrum, has a multifractal structure (an object having different fractal properties in its different region) [12]. These multifractal approaches were able to characterize the retinal vascular architecture disorder in several diseases [11,13,14].

At initial presentation, the differential diagnosis between optic neuritis (ON) and nonarteritic anterior ischemic optic neuropathy

(NAION) is difficult to be performed on clinical grounds, both giving overlapping clinical profiles [15]. However, it is fundamental to establish an early differential diagnosis, having the ON patient a clear tendency to develop multiple sclerosis, a disease where therapies should be performed as early as possible [16]. In order to verify whether the fractal analysis of the optic nerve head microvasculature could help in the differential diagnosis between ON and NAION, we have evaluated the mass dimension of the optic nerve head vascular pattern, as revealed by fluorescein angiography.

Subjects

Patients with unilateral NAION or unilateral idiopathic ON were recruited from the Department of Ophthalmology of the University of Siena. Each patient underwent a complete neuro-ophthalmic examination, including assessment of visual acuity, colour vision, papillary reaction, slit-lamp examination, applanation tonometry, Goldman visual field testing, visual evoked potentials, dilated funduscopy and fluorescein angiogram.

The criteria for patients' admittance with NAION to the study were: unilateral disc swelling with clinical features consistent with NAION [16], no recovery of visual function in the first month of follow up, exclusion of arteritic anterior ischemic optic neuropathy either on clinical grounds or following a negative temporal artery biopsy, negative magnetic resonance imaging of the brain and orbits, no other ocular pathology, no neurological diseases that might influence or explain the patient's visual symptoms. The patient admittance criteria with ON for the present research were: unilateral visual impairment associated with impaired colour vision and visual-field loss, presence

of disc oedema, young age (≤ 35 years), ocular pain associated with eye movements, recovery of visual function in the first month of follow up, no other ocular pathology, no neurological diseases that might influence or explain the patient's visual symptoms; history or detection of multiple sclerosis confirmed the diagnosis [17].

Nine cases of NAION and nine cases of ON with presence of optic disc oedema were enrolled without any selection. The unaffected eye of the patient was used as control ($n=10$). All patients were examined using a fluorescein angiogram within the first two weeks after they reported the first symptoms and before treatments; all patients gave informed consent. The protocol for this research project was approved by the Ethics Committee of the University of Siena and it conforms to the provisions of the Declaration of Helsinki, 1955 (as revised, Edinburgh, 2000).

Image analysis

Static fluorescein angiogram was performed (IMAGEnet 2000,v.2.0, Topcon). The early, intermediate and late phases of the angiogram were studied. Images of the early venous phase of the angiogram (around 20 seconds) gave the best visualization of the optic disc vessels and were saved. The same magnification was used for every patient.

A manual outline of the trajectories of the two-dimensional microvascular network was performed down to microvessels of 20 micron of diameter, processed to threshold the vessel network without background interference and converted into an outline of one pixel by means of Jmicrovision, <http://www.jmicrovision.com>, and Image Analyzer, <http://www.fosshub.com/Image-Analyzer.html>, softwares.

Mass Dimension (Dm)

The images were represented on a graphic window of 500 x 500 pixels (1 pixel = 4 μ m). To evaluate the mass dimension of the pattern, the set was covered with circles of radius r , (from 20 to 200 pixels), and the amount of pixels (n_r) inside the circles was evaluated [7]. A log-log plot was performed. The plot of the logarithm of n_r against the logarithm of r produced a straight line with a slope equal to Dm.

The methodology was implemented using Benoit 1.3 software (TruSoft Int'l Inc, <http://trusoft-international.com/.html>) and validated measuring computer generated Euclidean and fractal shapes of known mass dimensions. Inter- and intra-observers errors were < 3%.

Statistical analysis

Mann-Whitney's U test was used in order to compare the mass dimension indexes and to ascertain the significance among the groups; regression analysis was used to ascertain the log-log plot linearity. Receiver Operator Characteristic (ROC) were obtained with XLSTAT software (www.xlstat.com). Variance analysis was used in order to ascertain the dependence of the fractal index by age or gender.

Results

Images of the early venous phase of the angiogram (around 20 seconds) gave the best visualization of the optic disc vessels (Figure 1).

Image processing was able to reveal the microvascular pattern of the optic nerve head (Figure 2).

Fractal analysis showed that the optic nerve head microvasculature is fractal (log-log plot, $r > 0.99$, Figure 3).

Mass dimension statistically distinguished three classes (health condition vs. NAION vs. ON patients with optic disc oedema (Table 1).

Mass dimension of the optic nerve head vascularization distinguishes among ON, NAION and health condition: **ON vs. control, $p < 0.001$; *ON vs. NAION, $p < 0.01$; *NAION vs. control, $p < 0.01$;

ROC curves showed high sensitivity and specificity of the measures in order to distinguish among controls and pathologies (Figures 4,5).

Age and gender of patients doesn't affect the results ($p > 0.05$; $p > 0.05$).

Discussion

Recovery of visual function, visual field testing abnormalities, pain induced by ocular movements, cup-to-disc ratio, presence and/or distribution of optic disc oedema and fluorescein angiography together which age at diagnosis may help to differentiate optic neuritis (ON) and nonarteritic anterior ischemic optic neuropathy

Table 1: Mass dimension, Dm, of the optic nerve head vascularization, cases vs. control (mean \pm standard deviation).

Subjects	Dm (SD)
ON [†] with optic disc oedema	1.94 (0.025) *,**
NAION [‡]	1.86 (0.03)*
Control	1.74 (0.03)

[†]optic neuritis
[‡] nonarteritic anterior ischemic optic neuropathy.
 * $p < 0.01$; ** $p < 0.001$

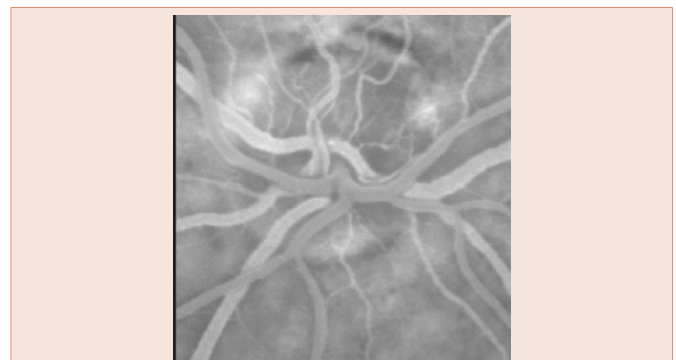

Figure 1: Fluorescein angiogram. Control eye.

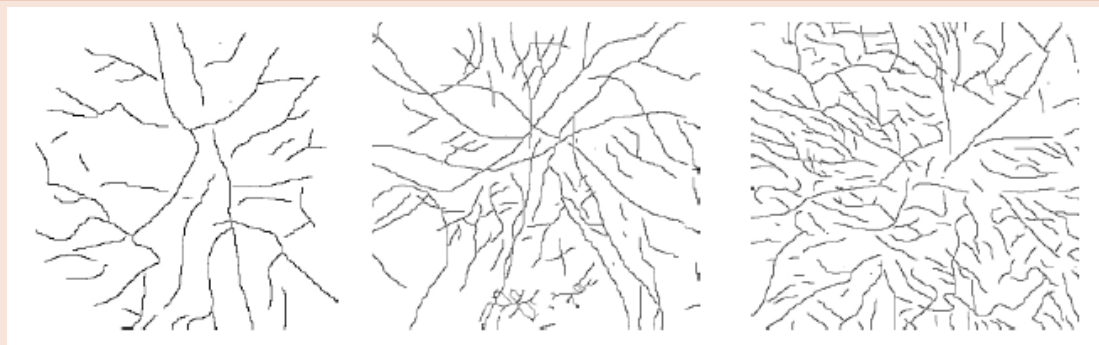

Figure 2: Trajectories of the optic nerve head microvasculature after fluorescein angiogram and image analysis. Control eye (left); nonarteritic anterior ischemic optic neuropathy (NAION, middle), optic neuritis with optic disc oedema (ON, right).

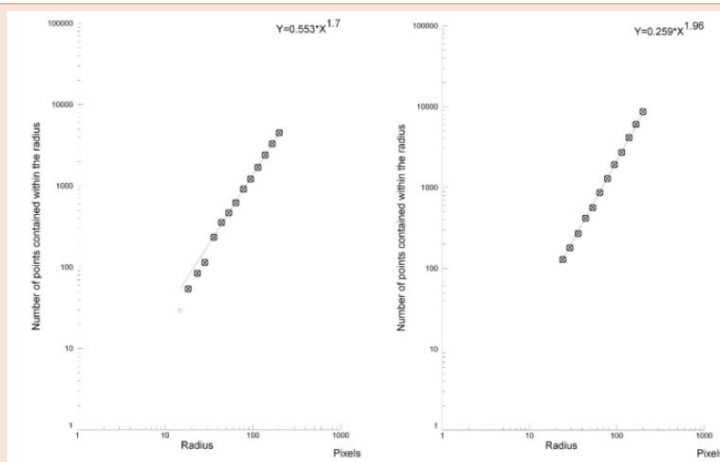


Figure 3: Log log plots. Plots present a straight line: the pattern is fractal. The exponent is the mass dimension of the optic nerve head microvasculature after fluorescein angiogram. Control eye (left), optic neuritis (right).

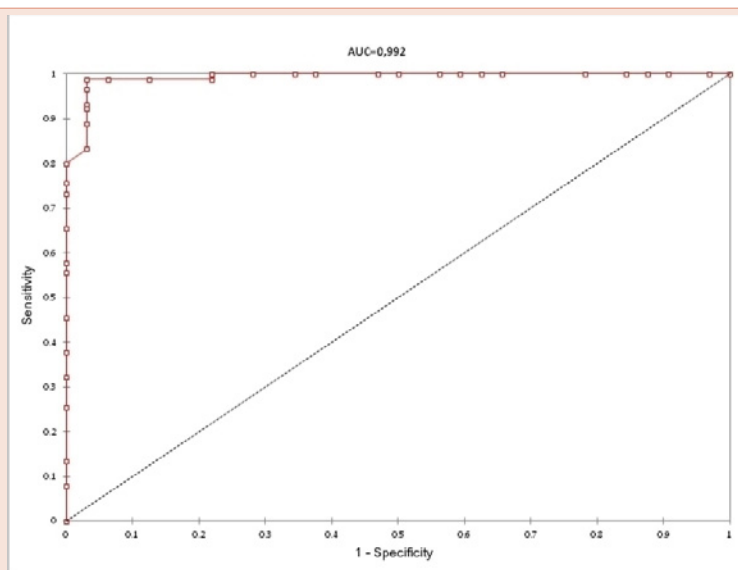


Figure 4: ROC curve. Health condition vs. non-glaucomatous disorders. Sensitivity = 0.98, Specificity = 0.96, $p < 0.0001$.

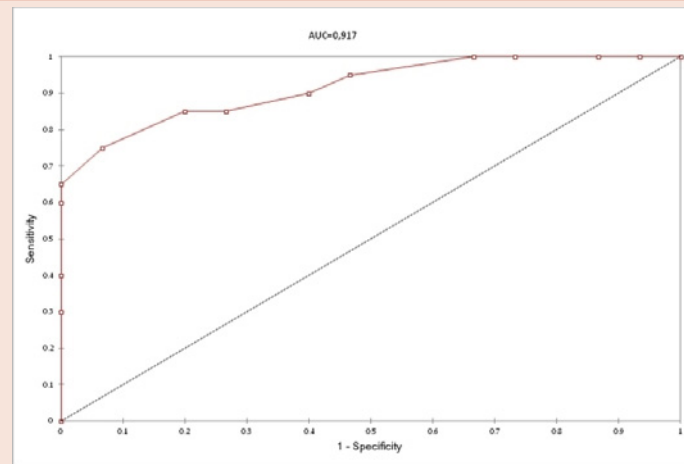


Figure 5: ROC curve. Non arteritic anterior ischemic optic neuropathy vs. optic neuritis with optic disc oedema. Sensitivity = 0.85, Specificity = 0.80, $p < 0.0001$.

(NAION) [18,19]. To facilitate early diagnosis, researchers have focused on objective morphological analysis of the retrobulbar tract and the head of the optic nerve, in order to reduce the bias caused by subjective medical interpretations [20]. Optic nerve analysis by means of magnetic resonance imaging, digital stereoscopy and Heidelberg retina tomography are some examples of how recent technologies can quantitatively document peculiar clinical findings in ON, NAION and other optic nerve diseases [21-23]. We can also recall the laser-based blood flow measuring technique applied to the study of optic nerve head microcirculation that has been able to quantitatively demonstrate optic nerve head circulatory abnormalities in patients with ON and NAION [24]. However, even by using these different approaches, ON and NAION frequently present overlapping clinical profiles, and sometimes appears difficult to distinguish them on clinical grounds at initial presentation [15].

In the present study, we have studied by means of fractal analysis the vascular patterns of optic nerve head obtained using fluorescein angiography in patients affected by ON and NAION. We then correlated the mass dimension values with the clinical diagnosis.

The validity of this method is confirmed by the concordance between the mass dimension values of the optic nerve head in the control group obtained by us and the fractal indexes obtained in normal retinal vessel by other Authors [25-29]. These values correspond to the complexity value of a diffusion limited aggregation (DLA) model [30], characteristic of many physiological structures [31-33].

The evaluation of mass dimension values in NAION and in ON patients showed significantly higher values compared with controls. In particular, the mass dimension in the ON group with optic disc oedema showed the highest value, corresponding to the highest complexity of the vascular pattern of the optic nerve head and represented by almost complete filling of the plane.

Mass dimension values in the NAION were approaching the one of a percolation model [34,35], in NAION a 2nd order phase transition arises. The changing state means that the vessel growth does not follow

according to nonlocal gradient value of diffusible growth factors, a diffusion-limited growth process as in our normal vascular retina, but according to a mechanism related to variables that act locally, variables like stress, local concentration of angiogenic molecules, or, more likely, irregular, inhomogeneous, substrate, as observed in the tumor vascular architecture [36].

Mass dimension values in the ON group with optic disc oedema showed the highest mean fractal dimension value: the distribution of the vascular pattern of the optic nerve head is completely chaotic, almost completely filling the plane. A clear effect of the tissue flogosis, even if this last result might be biased by the presence of the disc oedema, able to alter the local geometry of the blood vessels and generating a difficult visualization of the geometric pattern itself.

In the present paper, mass dimension of the optic nerve microvasculature observed by fluorescein angiogram appears able to objectively quantify the optic nerve head microvasculature and to distinguish among ON, NAION and health condition with high sensitivity and specificity, giving us a new tool in order to help clinicians to perform early diagnosis and to follow therapeutic procedures. These results add also new information to previous data obtained by us, where another fractal index, geometrical complexity evaluated by local box-counting analysis, resulted able to distinguish between the pathologies [37].

The new fast and unexpensive methodology here described appears clearly able to help clinicians to perform differential diagnosis between non-glaucomatous optic neuropathies, it might be useful also in order to study the effect of therapies during the follow up of the patient.

References

1. Heymans O, Fissette J, Vico P, Blacher S, Masset D, et al. (2000) Is fractal geometry useful in medicine and biomedical sciences?. *Medical Hypothesis* 54: 360-366.
2. Iversen PO, Nicolaysen G (1995) Fractals describes blood flow heterogeneity within skeletal muscle and within myocardium. *Am J Physiol* 268: 112-116.
3. Lefebvre F, Benali H, Gilles R, Kahn E, Di Paola R (1995) A fractal approach

- to the segmentation of microcalcification in digital mammograms. *Med Phys* 22: 381-390.
4. Daxer A (1993) Characterization of the neovascularization process in diabetic retinopathy by means of fractal geometry: diagnostic implications. *Graefes Arch Clin Exp Ophthalmol* 231: 681-686.
 5. Daxer A (1995) Mechanism in retinal vasculogenesis: an analysis of the spatial branching site correlation. *Curr Eye Res* 14: 251-254.
 6. Daxer A (1992) Fractals and retinal vessels. *Lancet* 339: 618.
 7. Falconer K (1990) *Fractal geometry: mathematical foundations and applications*. Chichester, John Wiley, NY, USA.
 8. Family F, Masters BR, Platt DE (1989) Fractal pattern formation in human retinal vessels. *Physica D* 38: 98-103.
 9. Cavallari M, Falco T, Frontali M, Romano S, Bagnato F, et al. (2011) Fractal analysis reveals reduced complexity of retinal vessels in CADASIL. *Plos one* 6: e19150.
 10. Doubal FN, MacGillivray TJ, Patton N, Dhillon B, Dennis MS, et al. (2010) Fractal analysis of retinal vessels suggests that a distinct vasculopathy causes lacunar stroke. *Neurology* 74: 1102-1107.
 11. Țălu Ș, Mihai Călugăru D, Lupașcu CA (2015) Characterisation of human non-proliferative diabetic retinopathy using the fractal analysis. *Int J Ophthalmol* 8: 770-776.
 12. Stanley HE, Meakin P (1988) Multifractal phenomena in physics and chemistry. *Nature* 335: 405-409.
 13. Stošić T, Stošić BD (2006) Multifractal analysis of human retinal vessels. *IEEE Trans med imaging* 25: 1101-1107.
 14. Țălu Ș, Vlăduțiu C, Popescu LA, Lupașcu CA, Vesa ȘC, et al. (2012) Fractal and lacunarity analysis of human retinal vessel arborisation in normal and amblyopic eyes. *HVM Bioflux* 5: 45-51.
 15. Warner JE, Lessell S, Rizzo JF III, Newman NJ (1997) Does optic disc appearance distinguish ischemic optic neuropathy from optic neuritis. *Arch Ophthalmol* 115: 1408-1410.
 16. Balcer LJ (2006) Clinical practice. Optic Neuritis. *N Eng J Med* 354:1273-1280.
 17. Beck RW, Cleary PA, Trobe JD, Kaufman DI, Kupersmith MJ, et al. (1993) The effect of corticosteroids for acute optic neuritis on the subsequent development of multiple sclerosis. *N Eng J Med* 329: 1764-1769.
 18. Arnold AC, Badr MA, Hepler RS (1996) Fluorescein angiography in nonischemic optic disc oedema. *Arch Ophthalmol* 114: 293-298.
 19. Collington-Robe NJ, Feke GT, Rizzo JF III (2004) Optic nerve head circulation in nonarteritic anterior ischemic optic neuropathy and optic neuritis. *Ophthalmology* 111: 1663-1672.
 20. Burgoyne CF (2004) Image analysis of optic nerve disease. *Eye* 18: 1207-1213.
 21. Danesh-Meyer H, Savino PJ, Spaeth GL, Gamble GD (2005) Comparison of arteritis and nonarteritic anterior ischemic optic neuropathies with the Heidelberg Retina Tomograph. *Ophthalmology* 112: 1104-1112.
 22. Morgan JE, Sheen NJL, North RV, Choong Y, Ansari E (2005) Digital imaging of the optic nerve head: monoscopic and stereoscopic analysis. *Br J Ophthalmol* 89: 879-884.
 23. Rizzo JF III, Andreoli CM, Rabinov JD (2002) Use of Magnetic Resonance Imaging to differentiate optic neuritis and nonarteritic anterior ischemic optic neuropathy. *Ophthalmology* 109: 1679-1684.
 24. Leiba H, Rachmiel R, Harris A, Kagemann L, Pollack A, et al. (2000) Optic nerve head blood flow measurements in nonarteritic anterior ischemic optic neuropathy. *Eye* 14: 828-833.
 25. Masters BR (2004) Fractal analysis of the vascular tree in the human retina. *Annu Rev Biomed Eng* 6: 427-452.
 26. Stosic T, Stosic BD (2006). Multifractal analysis of human retinal vessels. *IEEE Trans Med Imag* 25: 1101-1107.
 27. Avakian A, Kalina RE, Sage HE, et al. (2002) Fractal analysis of region-based vascular change in the normal and non-proliferative diabetic retina. *Curr Eye Res* 24: 274-280.
 28. Landini G, Murray PI, Misson GP (1995) Local connected fractal dimensions and lacunarity analyses of 60 degrees fluorescein angiograms. *Invest Ophthalmol Vis Sci* 36: 2749-2755.
 29. Landini G, Misson GP, Murray PI (1993) Fractal analysis of the normal human retinal fluorescein angiogram. *Current Eye Research* 12: 23-27.
 30. Witten TA, Jr, Sander LM (1981) Diffusion-Limited Aggregation, a Kinetic Critical Phenomenon. *Phys Rev Lett.* 47: 1400-1403.
 31. Naeim F, Moatamed F, Sahimi M (1996) Morphogenesis of the bone marrow: fractal structures and diffusion-limited growth. *Blood* 87: 5027-5031.
 32. Cross SS, Cotton DWK (1992) The fractal dimension may be a useful morphometric discriminant in histopathology. *J Pathol* 166: 409-411.
 33. Losa GA, Nonnenmacher TF (1996). Self-similarity and fractal irregularity in pathologic tissues. *Mod Pathol* 9: 174-182.
 34. Chays JT, Chayes L, Grannan E, Swindle G (1991) Phase transition in mandelbrot's percolation process in three dimensions. *Probab Theory Relat Fields* 90: 291-300.
 35. Lopeza RH, Vidalesa AM, Zgrablich G (2003) Fractal properties of correlated invasion percolation patterns. *Physica A* 327: 76-81.
 36. Gazit Y, Baish JW, Safabakhsh N, Leunig M, Baxter LT, et al. (1997) Fractal characteristics of tumor vascular architecture during tumor growth and regression. *Microcirculation* 4: 395-402.
 37. Traversi C, Bianciardi G, Tasciotti A, Berni E, Nuti E, et al. (2008) Fractal analysis of fluoroangiographic patterns in anterior ischaemic optic neuropathy and optic neuritis: a pilot study. *Clin Exp Ophthalmol* 36: 323-328.

Copyright: © 2016 Bianciardi G, et al. This is an open-access article distributed under the terms of the Creative Commons Attribution License, which permits unrestricted use, distribution, and reproduction in any medium, provided the original author and source are credited.