

Guy Stéphane Padzys*, Jean Marc Martrette and Marie Trabalon

Département de Biologie, P 943 Franceville/Gabon, Université des Sciences et Techniques de Masuku, France

Dates: Received: 28 August, 2015; Accepted: 14 October, 2015; Published: 19 October, 2015

***Corresponding author:** Guy Stéphane Padzys, Département de Biologie, P 943 Franceville/Gabon, Université des Sciences et Techniques de Masuku, France, E-mail: padzys@gmail.com

www.peertechz.com

ISSN: 2455-4634

Keywords: Nasal obstruction; Olfactory bulb; Histology; Hormones

Research Article

Impact of Early Nasal Obstruction in Histological Development of and Physiological State

Abstract

Introduction: Nasal obstruction is a risk factor in sleep-disordered breathing with a negative impact on the quality of life in humans.

Objective: In this study we determined whether histological development of olfactory bulb development could be influenced by an early temporary (3 d) nasal obstruction associated with physiological state.

Methods: The rats were killed at specific time points after surgery. Plasma samples were taken for biochemical analyses, and histological measurements were performed. Shortly after nasal obstruction, the volumes of external plexiform (CPE), internal plexiform (CGI), and granule cell (CGr) was measured in both sexes of test rats compared with controls.

Results and Conclusion: Reversible nasal obstruction was further associated with reduced dimensions of the volumes of CPE (male: 55%; female: 37%), CGI (male: 49%; female: 34%) and CGr (male: 70%; female: 47%). Basal corticosterone levels had increased in female rats, however, we observed the lower level of thyroid hormone, especially in male experimental group.

We conclude that a 3-d nasal obstruction period in young rats leads to long-term hormonal changes was associated in modification of histological structural of olfactory bulb.

Introduction

Nasal obstruction is considered a risk factor in sleep-disordered breathing [1-3], which has a very negative impact on quality of life in children and adults with increased daytime sleepiness [4]. This symptom resembles that of obstructive sleep apnea (OSA) caused by episodes of upper airway obstruction leading to episodic hypercapnic hypoxia which alters upper airway muscle structure and fiber type expression [5]. The most common clinical manifestations of OSA are nocturnal snoring, respiratory pauses, restless sleep and mouth breathing [6]. This disturbed breathing is known to produce lethargy, cognitive impairment and sleep impairment, especially in children [7,8].

Chronic nasal obstruction is a non-specific condition observed in many pathological conditions, e.g. rhinitis. Nevertheless, because this disorder is not life threatening (at least in adults) its importance could be underestimated. Impaired nasal breathing results in obligatory oral breathing, which can be divided into two components: chronic absence of active nasal respiration that results in an olfactory deprivation [9], and chronic mouth opening [10]. Furthermore, in contrast to oral breathing, nasal breathing allows the optimal conditioning of inhaled air, clearing, moistening and warming the air before gas exchange in the lung [11,12].

Obligatory mouth breathing has been observed in human babies and has been associated with a number of conditions that could have both short and long term effects on the physiology and thus behavior of these infants later on in adolescence. Decreases in oxygen

saturation and respiratory frequency, with an increase in arousal were observed with nasal occlusion in preterm infants [13]. If untreated oral breathing in children can induce long narrow faces, narrow mouths, high palatal vaults, dental malocclusion, gummy smiles and other effects like skeletal facial profiles. These children do not sleep well at night and this lack of sleep can adversely affect growth and academic performance [8,14].

In other words, it is possible that nasal obstruction causes a loss of the sense of smell and this hyposmia could disrupt the orientation of young rats to the mother, with consequent deprivation of food and feeding. It has been shown in rats that deprivation of food for 3 days causes a diminution in thyroid hormones [15] associated an increase in stress hormones [16].

No study has shown the long-term impacts of early nasal obstruction, associated with oral breathing, on development of olfactory bulb in the rat. The aim of the present investigation was to evaluate the effect of early short-term (3 d) nasal obstruction, associated with oral breathing, on olfactory bulb long term (90 d, adult) impact. Our hypothesis was that nasal obstruction would have a significant effect on olfactory bulb development during the very short period of forced oral breathing. The effect of early nasal obstruction on olfactory bulbs and on hormonal status was also studied. In particular, the stress response and plasma levels of thyroid hormones T3 and thyroxine (T4) were evaluated to determine if these hormones could be implicated in olfactory bulb histology development during early nasal obstruction.

Methods

Animals

Forty-two male Wistar rats (IFFA-CREDO, France) were used for this experiment. The animals were born in the laboratory from twenty litters, culled to 7 pups per litter to ensure normal body growth. The animals were housed in standard cages under controlled temperature conditions ($22 \pm 1^\circ\text{C}$). Food and water were available ad libitum throughout the experiment. From birth, the rats were kept on a reversed 12:12 light–dark cycle (dark period 08:00–20:00).

Nasal obstruction procedure

All experiments conformed to the Guide for the Care and Use of Laboratory Animals published by the National Institutes of Health (no. 85-23, revised 1996), the recommendations of the European Community Council for the Ethical Treatment of Animals (no. 86/609/EEC) and the regulations of the University of Nancy 1. All efforts were made to minimise animal suffering. At the age of 8 days (D8), the litters were first anaesthetised. Animals were weighed and they were then divided randomly into one control group and one experimental group (oral breathing). Bilateral nasal obstruction, resulting in forced oral breathing, was performed in experimental animals (7 per age) as described previously by Meisami [10], and Waguespack et al. [17]. The selected method consisted in the cauterisation of the external nostrils, which is the most common and simple procedure allowing spontaneous reopening of nostrils after 4 days. The tissue surrounding the external nostrils was burned by placing a surgical cauterising instrument (1mm in diameter) on the nostrils, consequently occluding the orifice of the nostrils without mechanical or chemical damage to the olfactory mucosa. This procedure induced complete nasal obstruction between D8 and day 11 (D11) with 100% of the nostrils spontaneously reopened by day 15 (D15).

The sampling experiments were conducted during complete nasal obstruction day 9 (D9) and day 11 (D11) and at 90 days after post-reopening of the nostrils, i.e. at the beginning of adulthood (Figure 1). The animals started breathing through their mouths immediately after nasal occlusion, as has been reported in infant ⁸. Nostril cauterisation earlier in life resulted in rapid death of the pups. In the control group (7 per age), the nostrils were not sealed but the cauterising instrument was placed about 1–2mm above each nostril to burn the skin. After cauterisation, the nostrils were washed with

chlortetracycline (Aureomycine Evans 3%) to prevent infection. The pups were warmed (37°C) for 30mn and returned to their mothers. Exploratory and feeding behaviours of the pups after weaning were the same for both cauterised and control group rat pups suggestive of no serious long term central effects of the treatment, especially in the forced oral breathing group [18].

Sample collection

Seven rats per group (control and oral breathing) and per sex (D90) were removed, immediately humanely killed, weighed and an intracardiac blood sample (500–1000 ml) was taken between 11 h and noon for hormonal measurements. Blood was collected over 1–2 min into sterile heparinised syringes fitted with a 26-G needle. Plasma was immediately separated from cells by centrifugation (4°C , 15 min at 3000 rpm) and the extracts were stored at -18°C until assayed. After blood sampling, olfactory bulbs, were removed bilaterally and weighed.

Histology studies

Olfactory bulbs were removed, frozen rapidly in isopentane at -70°C , and stored at this temperature until sectioning. Serial coronal sections ($30\ \mu\text{m}$) were collected on a cryostat and thaw mounted onto gelatin-subbed slides. Sections were dried on a hot plate for 1 h, incubated in 10% formalin for at least 48 h, and stained with cresyl violet. Slides were then dehydrated, cleared, and coverslipped using DPX mounting medium (Aldrich, Milwaukee, WI). Volumes of the external plexiform (CPE), internal plexiform (CGI), and granule cell (CGr) layers (Figure 2) in both right and left olfactory bulbs were measured by projecting images at 403 onto a microcomputer-controlled digitizing tablet and measuring the area of each lamina in every 10th section.

Each lamina was measured twice to determine the mean area. The volume of each layer in the right (experimental) and left (control) olfactory bulbs was then calculated as described previously [19].

Hormone assays

Corticosterone were measured without an extraction procedure, using a commercially available EIA kit and performed according to the manufacturer's guidelines (Assay Designs Inc., USA). The concentration of corticosterone in plasma samples was calculated from a standard curve and expressed as ng/ml. The intra- and inter-assay coefficients of variation were under 8.4 and 13.1 %.

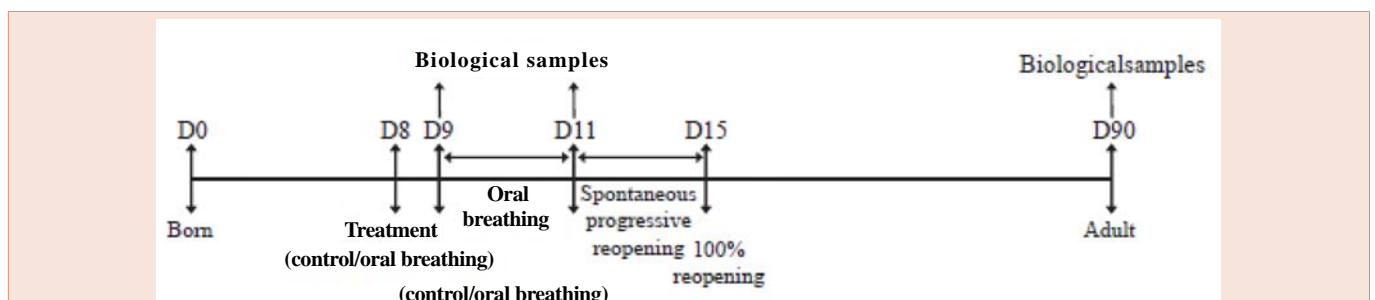


Figure 1: Time line of the experimental protocol.

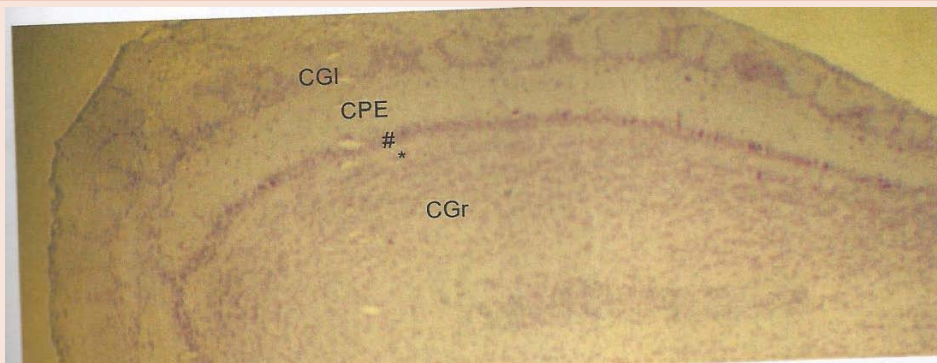

Figure 2: Histology of olfactory bulb (CGI: internal; CPE: external plexiform; CGr granule cell).

Thyroxine (T4) and triiodothyronine (T3) were assayed using commercial RIA kits and performed according to the manufacturer’s guidelines (Immunotech SA, Marseille, France). The concentrations of T4 and T3 in plasma samples were calculated from standard curves and expressed as pg/ml. The intra- and inter-assay coefficients of variation were respectively under 6.7 and 6.5% for T4 and under 6.4 and 5.5% for T3.

Statistical analysis

The results were expressed as group means ± SEM. Student’s t-test was used to establish the comparison between control and oral breathing animals since all data were normally distributed. Body weight group differences were determined using a two-way ANOVA (factor treatment × factor age). Specific mean comparisons were then made using t-test with the Bonferroni correction. Differences were considered significant at P < 0.05.

Results

Morphometric characteristics

Before treatment, at 8 days of age, the body weights of control and oral breathing pups were not significantly different. In male group there are 17.78 ± 0.52 g and 17.95 ± 0.28 g, respectively (p = 0.14). The body weights in female was 16.58 ± 0.42 g and 16.32 ± 0.38 (p = 0.48) respectively. **Table 1** shows no differences in body weights were observed at 90 days in male (p = 0.28) and female group (p = 0.39). Relative olfactory bulb weights are presented in **Table 1**.

A significant reduction in olfactory bulb specific weight was found for in the nasal obstruction group compared to control animals (p < 0.0001). The reduction was 41% in nasal obstruction males and 34% in female compared to control animals.

Histological study

To check whether nasal obstruction had affected the development of olfactory bulbs histology, the volumes of the external plexiform (CPE), internal plexiform (CGI), and granule cell (CGr) was measured (**Table 2**).

Results showed that nasal obstruction affect the development of olfactory bulb structure. In female group we observe the decrease volume of CGI (34%), CPE (37%) and CGr (47%). These changes are

more important in male experiment group. In male, we observe the decrease volume of CGI (49%), CPE (55%) and CGr (70%)

Hormone assays

As shown in **table 3**, plasma corticosterone levels were significantly different between control and experimental female groups (p<0.001). We observe an increase of plasma corticosterone level (302. 76%).

No difference was observed in thyroid hormones in female group (p>0.05).

In male group **Table 3** shown that decrease (p <0.0001) in plasma Thyroids hormones levels was observed (T4: 12%; T3: 27%). No difference was observed in corticosterone between control and male experimental group (P>0.05)

Discussion and Conclusion

Our data show atrophy of the olfactory bulbs. It is well established that induction of an obstruction nasal causes atrophy of the components of the olfactory system. This atrophy has been demonstrated not only in the olfactory mucosa, but also for the olfactory bulb [20,21]. Indeed, in the absence sensory stimulation, there is a decrease in the number of cells within the olfactory mucosa, lack of afferent from the mucosa leads to turn down the number of cells in the olfactory bulb. Two assumptions not exclusive can be advanced to explain these changes: a decrease in neo-neurogenesis and / or an increase in apoptosis [22,23].

Our results showed that early temporary (3 d) nasal obstruction

Table 1: Effects of temporary nasal obstruction on body weight (g) and olfactory bulbs specific weights (mg/g) at 90 days in controls and animals exposed to nasal obstruction.

Females	Body weight (g)	Olfactory bulb (mg/g)
Control	264,44±4,1	0,22±0,01
Oral breathing	250,6±8,6	0,13±0,01*
Males		
Control	394,18±8,65	0,3±0,01
Oral breathing	408,47±9,61	0,2±0,01*

Values are means ± SEM (n = 7/group/age).
*significantly different from control group at 90 days at P < 0.05.

Table 2: Effects of temporary nasal obstruction on olfactory bulbs structure at 90 days in controls and animals exposed to nasal obstruction.

Females	CGI (mm)	CPE (mm)	CGR(mm)
Ctrl	0,32±0,06	0,38±0,06	0,83±0,08
NO	0,21±0,03*	0,24±0,04*	0,44±0,07*
Males			
Ctrl	0,27± 0,08	0,56±0,07	0,7±0,06
NO	0,14±0,02*	0,25±0,02*	0,21±0,04*

Values are means ± SEM (n = 7/group/age).

*significantly different from control group at 90 days at P < 0.05.

Table 3: Effects of temporary nasal obstruction on physiological hormones at 90 days in controls and animals exposed to nasal obstruction.

Females	Corticosterone (ng/ml)	Triiodothyronine (pg/ml)	Thyroxine (pg/ml)
Ctrl	14,13±3,7	5,2±0,4	13,3±0,01
NO	42,78±6,01*	4,3±0,6	13,28±0,3
Males			
Ctrl	22,53±6,10	5,8±0,1	17,10±0,5
NO	27,77±3,44	3,01±0,8*	15,2±0,2*

Values are means ± SEM (n = 7/group/age).

*significantly different from control group at 90 days at P < 0.05.

associated with forced oral breathing causes changes in olfactory bulb structure. Nasal obstruction was associated with a decrease of the volumes of the external plexiform (CPE), internal plexiform (CGI), and granule cell (CGr) in both sexes. Similar results had already been found by Meisami [1], who showed atrophy of the olfactory bulbs due to nasal obstruction. Several hypotheses had been issued: the first clear –cut demonstration of a growth inhibitory effect in a central sensory structure as a consequence of the mere lack of sensory input to that structure during critical period's brain development. To be sure, true and complete differentiation with consequent axonic and synaptic degeneration has frequently been shown to result in reduced growth [24-26]. A number of causes may underlie the reduced growth in experimental group: reduction in rate magnitude of over –all protein synthesis related to growth; reduction in cell growth and differentiation, particularly with respect to dendritic and synaptic proliferation; reduction in glial and / or neuronal proliferation; reduction in lipid synthesis and myelin formation; reduction in electrical and other neurophysiological activities of the nasal obstruction as a consequence of decrease receptor and afferent stimulation; reduction in blood supply with a consequent state of under nutrition and lowered metabolism.

The decrease in the volume of histological layers of the olfactory bulbs could still involve other factors such as hormonal changes. Nasal obstruction was long associated with hypothyroidism in males and an excess of glucocorticoids in females. In fact, glucocorticoid and thyroid hormones receptor are present on cells of the olfactory bulb from the early stages of development [27,28]. Excess glucocorticoids and hypothyroidism have deleterious effects on synaptogenesis [29], and neuronal proliferation in the tendering components of olfactory system [30,31]. In the developing rodent brain hypothyroidism, induce various morphological abnormalities such abnormalities including: a) delayed proliferation and migration of granule cell

layer (EGL) to the internal granule cell layer (IGL); b) decreased arborisation of Purkinje cell dendrites; c) decrease synaptogenesis between parallel fibers and Purkinje cell dendrite.

In conclusion, the present study has shown that the structure of olfactory and the levels of plasma hormones can be altered by temporary nasal obstruction. For the first time we have demonstrated that olfactory bulb atrophy induces by the nasal obstruction can be explained by a change in the hormonal status observed in the experimental groups. This could indicate that our model of temporary nasal obstruction could be an appropriate model for looking at potential changes in hormones and other physiological parameters of rhinitis or other temporary obstructive nasal breathing pathology.

References

1. Armengot M, Hernández R, Miguel P, Navarro R, Basterra J (2008) Effect of total nasal obstruction on nocturnal oxygen saturation. *Am J Rhinol* 22: 325–328.
2. Craig TJ, Ferguson BJ, Krouse JH (2008) Sleep impairment in allergic rhinitis, rhinosinusitis, and nasal polyposis. *Am J Otolaryngol* 29: 209–217.
3. Rombaux P, Liistro G, Hamoir M, Bertrand B, Aubert G, et al. (2005) Nasal obstruction and its impact on sleep-related breathing disorders. *Rhinology* 43: 242–250.
4. Udaka T, Suzuki H, Kitamura T, Shiomori T, Hiraki N, (2006) Relationships among nasal obstruction, daytime sleepiness, and quality of life. *Laryngoscope* 116: 2129–2132.
5. McGuire M, MacDermott M, Bradford A (2002) Effects of chronic episodic hypoxia on rat upper airway muscle contractile properties and fiber-type distribution. *Chest* 122: 1012–1017.
6. Balbani AP, Weber SA, Montovani JC (2007) Update in obstructive sleep apnea syndrome in children. *Braz J Otorhinolaryngol* 71: 74–80.
7. Dempsey JA, Veasey SC, Morgan BJ, O'Donnell CP (2010) Pathophysiology of sleep apnea. *Physiol Rev* 90: 47–112.

8. Jefferson Y (2010) Mouth breathing: adverse effects on facial growth, health, academics, and behavior. *Gen Dent* 58: 18–25.
9. Meisami E (1976) Effects of olfactory deprivation on post natal growth of the rat olfactory bulb utilizing a new method for production of neonatal unilateral anosmia. *Brain Res* 107: 437–444.
10. Schlenker WL, Jennings BD, Jeiroudi MT, Caruso JM (2000) The effects of chronic absence of active nasal respiration on the growth of the skull: a pilot study. *Am J Orthod Dentofacial* 117: 706–713.
11. Bettlejewski S (1998) Physiology and surgery of the nose. *Otolaryngol Pol* 52: 159–162.
12. Keck T, Leiacker R, Meixner D, Kühnemann S, Rettinger G (2001) Warming inhaled air in the nose. *HNO* 49: 36–40.
13. deAlmeida VL, Alvaro RA, Haider Z, Rehan V, Nowaczyk B, et al. (1994) The effect of nasal occlusion on the initiation of oral breathing in preterm infants. *Pediatr Pulmonol* 18: 374–378.
14. Subtelny JD (1980) Oral respiration: facial maldevelopment and corrective dentofacial orthopedics. *Angle Orthod* 50: 147–164.
15. Laws SC, Stocker TE, Ferrell JM, Hotchkiss MG, Cooper RL (2007) Effects of altered food intake during pubertal development in male and female Wistar rats. *Toxicol Sci* 100: 194–202.
16. Gomez F, Abdeljalil L, De Kloet ER, Armario A (1996) Hypothalamic–pituitary–adrenal response to chronic stress in five inbred rat strains: differential responses are mainly located at the adrenocortical level. *Neuroendocrinology* 63: 327–337.
17. Waguespack AM, Reems MR, Butman ML, Cherry JA, Coppola DM (2005) Naris occlusion alters olfactory marker protein immunoreactivity in olfactory epithelium. *Brain Res* 1044: 1–7.
18. Gelhaye M, Martrette JM, Legrand-Frossi C, Trabalon M (2006) Myosin heavy chain expression and muscles adaptation to chronic oral breathing in rat. *Respir Physiol Neurobiol* 154: 443–452.
19. Loranca A, Salas M (2001) Social play development in pre-weaning olfactory deprived or stimulated rats. *Brain Res* 7: 150–159.
20. Najbauer J, Leon M (1995) Olfactory experience modulated apoptosis in the developing olfactory bulb. *Brain Res* 674: 245–251.
21. Brunjes P, Shurling DC (2003) Cell death in the nasal septum of normal and naris-occluded rats. *Brain Res Dev Brain Res* 146: 25–28.
22. Farbman A, Brunjes PC, Rentfro L, Michas J, Ritz S (1998) The effect of unilateral naris occlusion on cell dynamics in the developing rat olfactory epithelium. *J Neurosci* 8: 3290–3295.
23. Bauer S, Rasika S, Han J, Mauduit C, Raccurt M, et al. (2003) Leukemia inhibitory factor is a key signal for injury-induced neurogenesis in the adult mouse olfactory epithelium. *J Neurosci* 23: 1792–1803.
24. Wu HH, Ivkovic S, Murray RC, Jaramillo S, Lyons KM, et al. (2003) Autoregulation of neurogenesis by GDF11. *Neuron* 37: 197–207.
25. Klossovsky BN, Kosmarskaya EN (1963) Excitatory and inhibitory state of the brain. National Science Foundation, Washington D.C.
26. Powell TP (1967) Transneuronal cell degeneration in the olfactory bulb shown by Golgi method. *Nature* 215: 425–426.
27. Risen AH (1975) The developmental neuropsychology of sensory deprivation, Academic press, New York.
28. Morimoto M, Morita N, Ozawa H, Yokoyama K, Kawata M (1996) Distribution of glucocorticoid receptor immunoreactivity and mRNA in the rat brain: an immunohistochemical and in situ hybridization study. *Neurosci Res* 26: 235–269.
29. Galeeva A, Treuter E, Tuohimaa P, Peltto-Huikko M (2002) Comparative distribution of the mammalian mediator subunit thyroid hormone receptor-associated protein (TRAP220) mRNA in developing and adult rodent brain. *Eur J Neurosci* 16: 671–683.
30. Koibuchi N, Iwasaki T (2006) Regulation of brain development by thyroid hormone and its modulation by environmental chemicals. *Endocr J* 53: 295–303.
31. Van den Hove DL, Steinbusch HW, Bruschetini M, Gazzolo D, Frulio R, et al. (2006) Prenatal stress and neonatal rat brain development. *Neurosciences* 137: 145–155.

Copyright: © 2015 Padzys GS, et al. This is an open-access article distributed under the terms of the Creative Commons Attribution License, which permits unrestricted use, distribution, and reproduction in any medium, provided the original author and source are credited.

Citation: Padzys GS, Martrette JM, Trabalon M (2015) Impact of Early Nasal Obstruction in Histological Development of and Physiological State. *Int J Oral Craniofac Sci* 1(2): 034-038.