

Simona Vallarelli<sup>1</sup>, Stefania Stucci<sup>1\*</sup>,  
Marco Tucci<sup>1</sup>, Nicola Quaranta<sup>2</sup>,  
Donatella Russo<sup>3</sup>, Marco Moschetta<sup>4</sup>  
and Franco Silvestris<sup>1</sup>

<sup>1</sup>DIMO, Department of Biomedical Sciences and  
Clinical Oncology University of Bari 'Aldo Moro',  
Italy

<sup>2</sup>Department of Ophthalmology and Otolaryngology,  
University of Bari 'Aldo Moro', Italy

<sup>3</sup>Department of Radiation Oncology, V. Fazzi  
Hospital, Lecce, Italy

<sup>4</sup>Department of Medicine, Section of Diagnostic  
Imaging, University of Bari 'Aldo Moro', Italy

**Dates:** Received: 25 January, 2016; Accepted: 20  
February, 2016; Published: 22 February, 2016

\*Corresponding author: Stefania Stucci, MD,  
Medical Oncology Unit, DIMO, University of Bari 'Aldo  
Moro', P.za Giulio Cesare, 11 - 70124 Bari, Italy, Tel:  
+39.080.547.8674; Fax: +39.080.547.8831; E-mail:  
stuccistefania@gmail.com

[www.peertechz.com](http://www.peertechz.com)

ISSN: 2455-1759

## Case Report

# Adenocarcinoma of Ceruminous Glands: Role of the VMAT

### Abstract

Adenocarcinoma of the ceruminous glands is a rare malignancy arising from the glands of the external auditory canal. In most patients it is usually diagnosed as locally advanced disease with a major obstacle for radical surgery. Here, we describe two cases of patients suffering of sudden hearing loss and ipsilateral facial hemiparesis due to tumors arising from the ceruminous glands with primary intracranial involvement and subsequent middle ear infiltration. The patient with local-advanced disease underwent surgery followed by adjuvant treatment, whereas the other patient with advanced disease only to palliative therapy. However, both of them received volumetric-modulated arc radiotherapy (VMAT) resulting in complete remission as adjuvant treatment in the first patients while extending the survival as palliation in the second one. Thus, VMAT appears a suggested approach in this tumor which management is still poorly defined.

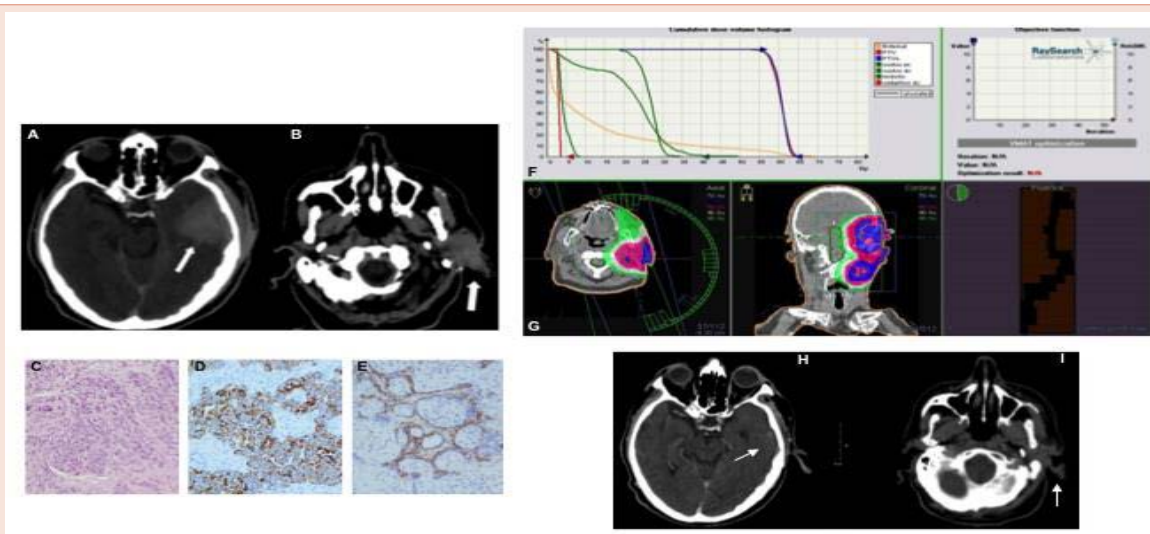
## Introduction

Adenocarcinoma of the ceruminous glands originates from the apocrine sweat glands located within the external auditory canal [1-3]. Its incidence is undefined and the clinical presentation is mostly characterized by general symptoms. Although the diagnosis of malignant ceruminoma is generally provided by the pathologist, both computed tomography (CT) scan and nuclear magnetic resonance (NMR) are commonly utilized for diagnosis [4,5]. The tumor shows poor prognosis and the majority of studies suggest that the best clinical result is provided by the radical excision followed by radiation [6], based on the ineffectiveness of chemotherapy in terms of clinical response rate (RR) and overall survival (OS). However, it has been experienced that the intensity-modulated radiation therapy (IMRT) such as VMAT (volumetric-modulated arc therapy) is of great effort for the treatment of this tumor in relation to minor side effects and better safety of peritumoral structures as compared to the conformational irradiation [7]. Two patients with malignant ceruminoma were admitted at the Medical Oncology Unit of the University of Bari 'Aldo Moro' and both treated with VMAT for adjuvant and palliative treatment.

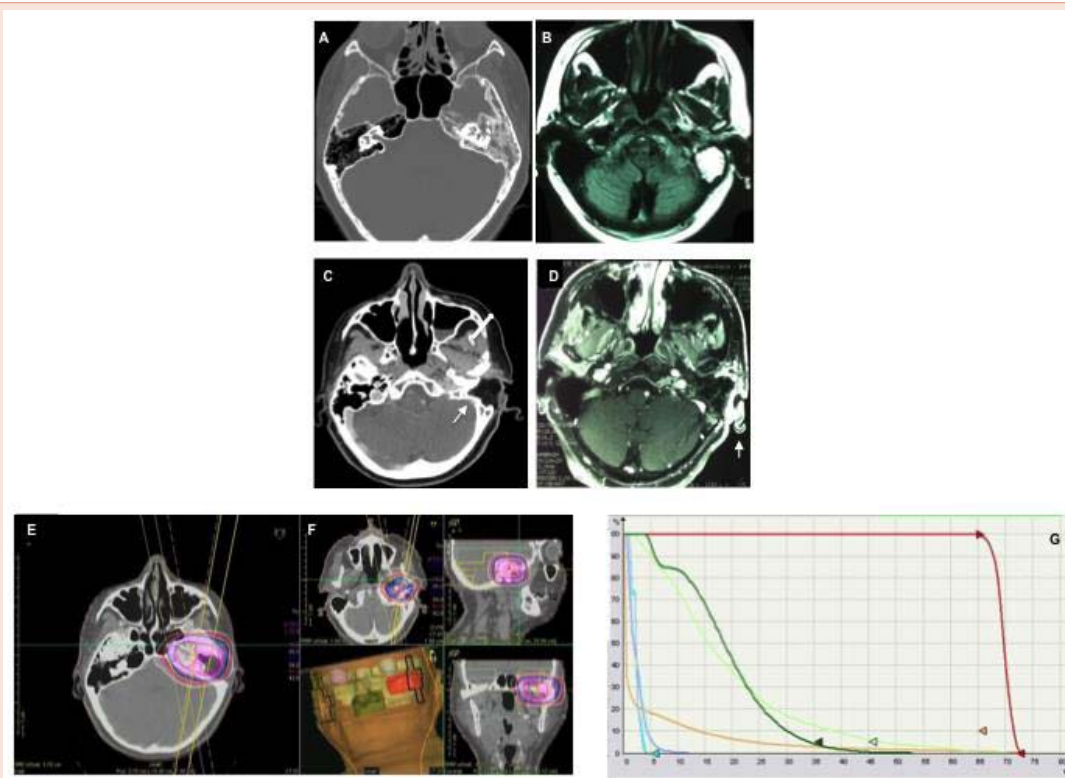
## Case Presentation

The patients has given their informed consent for the case report to be published. A 71-year-old male (patient n.1) suffering of headache, left facial nerve hemiparesis and lagophthalmos associated to ipsilateral sudden-hearing loss was admitted in our department. Blood tests were normal and the patient underwent whole-body CT-scan revealing a mass with irregular margins and hypervascularity of 5x5 cm localized nearby the left pre-auricular area and invading

the middle cranial fossa with extension up to the external auditory canal and the tympanic cavity as well as to the petrous bone. In addition, the tumor infiltrated the parotid gland leading to medial dislocation of the temporal horn although the ventricular system was not enlarged (Figure 1, panels A,B) whereas the NMR revealed the metastatic local colonization of cervical, submandibular and retro-nuchal nodes. The patient was biopsied in several parts including the mastoid, middle ear, dural tissue and middle cranial fossa whose microscopic examination identified the presence of poorly differentiated spindle cells showing a high number of nucleoli and vacuoli with a trabecular-like organization (panel C). The diagnosis of poorly differentiated adenocarcinoma of the ceruminous gland with meningeal infiltration was confirmed by immunohistochemistry showing the cytokeratin pool, as well as both the epithelial membrane antigen and S100 protein (panels D and E), whereas other ontogenetic markers as glial fibrillary acidic protein, neuron specific enolase (NSE) and epidermal growth factor receptor (EGFR) were not detected [8]. Based on the intracranial extension of the malignant cells, the patient was not eligible for radical surgery and underwent VMAT treatment extended up to five weeks for a total dose of 6000 cGy (panels F,G). This treatment induced a partial response according to the RECIST criteria [9], that was maintained up to four months with a stable tumor size of 3 cm (panels H,I) in parallel with clinical benefit. The objective RR was maintained for eight months when the patient suffered of sudden weakness of the right arm associated to burning pain of the thoracic spine. New radiological assessments including NMR and both brain and spinal-cord CT-scan confirmed the clinical progression by pathologic tissue with high contrast-enhancement in the extradural and left insulo-parietal level in parallel with infiltration of the skull in the omolateral temporal-occipital region. The spine examination showed the occurrence of metastatic vertebral lesions with intradural infiltration at both cervical and dorsal levels. Moreover, other pathologic tissue involved the right pedicles of D5 and D7 as well as the lumbar spine leptomeninges. Thus, the



**Figure 1: Diagnosis and palliative treatment in patient 1.** CT scan demonstrated the presence of malignant tissue of 5x5 cm showing high contrast enhancement and arising from the left external auditory canal (arrows in panel A and B). Microscopic examination by hematoxylin-eosin staining (C) demonstrated the presence of high number of nucleoli within poorly differentiated cells organized in trabeculae. Immunohistochemistry revealed the diffuse expression of cytokeratin pool and strong detection of epithelial membrane antigen in proximity to the outer cell layer (D and E). Right panels illustrated the VMAT planning and response evaluation. Dose coverage of both primary and nodal volumes was considered adequate as shown by the red and blue curves on the dose-volume histogram (DVH) as well as by isodose distribution (F and G). The CT-scan at one and three months (H and I) demonstrated the volumetric reduction of the tumoral mass up-to 3 cm of diameter (arrows) induced by VMAT.



**Figure 2: Radiological and clinical response by VMAT in patient 2.** CT scan and NMR of patient case n. 2 showed a dysomogenous tissue in the tympanic cavity and mastoid of the left ear that was partially extended to the external auditory canal (A-B). As shown in panels C and D, the post-surgical evaluation was negative for tumor relapse. The VMAT planning whose dose-distribution, 3-D reconstruction of target volume and surrounding tissues as well as DVH curves were showed in panels E, F and G.

patient was considered only for best supportive care with monthly bisphosphonates and palliative rehabilitation.

A 59-year-old female (patient n. 2) affected by chronic left catarrhal otitis was hospitalized for hearing loss, itch and purulent secretion of the left ear. Physical examination of the external auditory canal revealed a reddish bleeding polypoid lesion surrounding the external auditory canal. The patient underwent both CT-scan and NMR that showed an irregular mass spread within the tympanic cavity up to the ossicular chain, involvement of the mastoid with partial extension toward the external auditory canal (Figure 2, panel A,B). The patient underwent mastoidectomy and radical excision of the lesion whose histological examination showed a poorly differentiated carcinoma with adenomatous features and cytokeratin, CAM and epithelial membrane antigen expression. By contrast, smooth muscle actin and CEA were negative. The tumor was radically removed by surgery based on CT-scan and NMR that were negative for residual disease and distant metastatic lesions (panels C,D). The patient was candidate for adjuvant treatment with VMAT radiation receiving a total dose of 70 Gy (panels E,F,G). The post-radiation follow-up was negative for the tumor relapse and the patient is still asymptomatic after 30 months of adjuvant treatment.

## Discussion

The external ear canal is delimited by the temporo-mandibular joint, the mastoid air cells and the parotid space since it is covered by a slim squamous mucosa holding a fibrous stroma that contains both sebaceous and ceruminous glands with a modified apocrine sweat differentiation [8].

The pathogenic mechanisms leading to malignant transformation of ceruminous glands are still unknown [10] and their most common histologic variants include cells with both high-grade anisocytosis and pleomorphism with features resembling secretory cells [11-13]. Ear pain associated with blood-serum otorrhea and bleeding are common symptoms causing headache, hearing loss, tinnitus, infection and weakness, whereas the advanced disease causes neurological, ocular and vestibular signs that depend on the primitive tumor localization [14].

Here we described two patients, one of them suffering of left peripheral facial nerve paralysis with ipsilateral lagophthalmos and hearing loss. These symptoms occurred as result of the invasion of the tumor of middle cranial fossa, tympanic cavity and petrous temporal area that is explained on the basis of high malignancy characterized by high proliferative rate and propensity to invade both Eustachian tube and middle fossa dura [10]. The second patient was affected by hearing loss and otorrhea without signs of peripheral facial nerve paralysis as consequence of the partial infiltration of the external ear canal.

The diagnosis is provided by high-definition coronal and axial CT-scan for the identification of the parotid lodge and the characterization of cervical node involvement, whereas NMR discriminates the potential infiltration of soft tissues surrounding the primary site [5].

The American Joint Committee on Cancer (AJCC) does not

classify the adenocarcinoma of ceruminous glands, thus other staging systems have been proposed [15-17]. They include the 'Cincinnati Surgical Staging' that is based on intraoperative and radiographic parameters [18], whereas the 'Pittsburg Staging System' (PSS) correlates the radiologic findings with both clinical and histological features [19-20]. Although the PSS is currently used for staging the squamous cells external ear neoplasms [21], it has been used applied in our patients. Thus, according to these criteria, the patients were fitted in stage III and II, respectively.

Malignant ceruminomas are rare, thus no standard protocol about the treatment is adopted. The high risk of recurrence after surgery and the difficulties in total removal of the mass for its invasiveness and hypervascularity suggest to perform irradiation after tumor resection.

Surgery and external-beam radiation provide the best clinical response in these tumors and their combination extends the survival driving a long-term prognosis [6]. Recent studies demonstrated the effectiveness of the extended wide resection of the temporal bone, since perineural invasion and bone extension are critical factors limiting the local recurrence as well as the metastatization [22]. Adjuvant radiation appears of great impact on OS and should be considered also in case of recurrent disease whereas is not indicated at diagnosis with the exception of ceruminous adenocarcinoma [23-24].

Based on the neoplastic intracranial invasion, the first patient was not eligible for surgery and thus was included in a palliative program aimed to reduce symptoms and restrain the mass expansion, whereas the second achieved radical response by surgery. Head and neck tumors are efficiently treated by IMRT that avoids over-dosing of nearby organs. The clinical indication of this technique is however limited by the long time necessary for delivery of the therapeutic dose. In this context, VMAT delivers the same dose in shorter time with response rates similar to IMRT [25]. The VMAT treatment in the first patient decreased the primary lesion of approximately 60% resulting in parallel reduction of neurological symptoms. Notwithstanding the radiologic and clinical control of the primary site, the patient experienced clinical relapse occurring with atypical metastatic localization of tumor cells within the lumbar meninges and spine, probably by contiguity. The outcome was severely worsened by this complication and only therapeutic options as bisphosphonates were used for the pain control. In the second case, the VMAT treatment induced the complete remission and the OS was higher than 30 months.

## Conclusions

VMAT controls both signs and symptoms related to adenocarcinoma of ceruminous glands. Therefore, VMAT could be considered the best option for an integrated approach after the surgery and our experience in these case reports encourages to apply the same procedure to get more data and improve the current treatment of malignant ceruminoma.

## References

1. Barrs DM (2001) Temporal bone carcinoma. *Otolaryngol Clin North Am* 34: 1197-1218.
2. Devaney KO, Boschman CR, Willard SC, Ferlito A, Rinaldo A (2005) Tumor of the external ear and temporal bone. *Lancet Oncol* 6: 411-420.



3. Fenniche S, Haouet S, Mdimagh H, Chatti S, Maamouri M, et al. (1995) Tumors of the ceruminous glands. *Ann Pathol* 15: 147-149.
4. Freedlander E, Chung FF (1983) Squamous cell carcinoma of the pinna. *Br J Plast Surg* 36: 171-175.
5. Ong CK, Pua U, Chong VF (2008) Imaging of carcinoma of the external auditory canal: a pictorial essay. *Cancer Imaging* 20: 191-198.
6. Schwager K, Pfreundner L, Hoppe F, Baier G, Willner J, et al. (2001) Carcinoma of the external ear canal and middle ear as interdisciplinary challenge for ear surgery and radiotherapy. *Laryngorhinootologie* 80: 196-202.
7. Fung-Kee-Fung SD, Hackett R, Hales L, Warren G, Singh AK (2012) A prospective trial of volumetric intensity-modulated arc therapy vs conventional intensity modulated radiation therapy in advanced head and neck cancer. *World J Clin Oncol* 3: 57-62.
8. Crain N, Nelson BL, Barnes EL, Thompson LD (2009) Ceruminous Gland Carcinomas: A Clinicopathologic and Immunophenotypic Study of 17 Cases. *Head and Neck Pathol* 3: 1-17.
9. Eisenhauer EA, Therasse P, Bogaerts J, Schwartz LH, Sargent D, et al. (2009) New response evaluation criteria in solid tumours: revised RECIST guideline (version 1.1). *Eur J Cancer* 45: 228-247.
10. Hicks GW (1983) Tumors arising from the glandular structures of the external auditory canal. *Laryngoscope* 93: 326-340.
11. Wetli CV, Pardo V, Millard M, Gerston K (1972) Tumors of ceruminous glands. *Cancer* 29: 1169-1178.
12. Fligiel Z, Kaneko M (1975) Extramammary Paget's disease of the external ear canal in association with ceruminous gland carcinoma. A case report. *Cancer* 36: 1072-1076.
13. Thompson LD, Nelson BL, Barnes EL (2004) Ceruminous adenomas: a clinicopathologic study of 41 cases with a review of the literature. *Am Surg Pathol* 28: 308-318.
14. Lynde CW, McLean DI, Wood WS (1984) Tumors of ceruminous glands, *J Am Acad Dermatol* 11: 841-847.
15. Goodwin WJ, Jesse RH (1980) Malignant neoplasm of the external auditory canal and temporal bone. *Arch Otolaryngol* 106: 675-679.
16. Stell PM, McCormick MS (1985) Carcinoma of the external auditory meatus and middle ear: prognostic factors and a suggested staging system. *J Laryngol Otol* 99: 847-850.
17. Clark LJ, Narula AA, Morgan DA, Bradley PJ (1991) Squamous cell carcinoma of the temporal bone: a revised staging. *J Laryngol Otol* 105: 346-348.
18. Pensak ML, Gleich LL, Gluckman JL, Shumrick KA (1996) Temporal bone carcinoma: contemporary perspectives in the skull base surgical era. *Laryngoscope* 106: 1234-1237.
19. Arriaga M, Curtin H, Takahashi H, Hirsch BE, Kamerer DB (1999) Staging proposal for external auditory meatus carcinoma based on preoperative clinical examination and computed tomography findings. *Ann Otol Rhinol Laryngol* 99: 714-721.
20. Arriaga M, Curtin HD, Takahashi H, Kamerer DB (1991) The role of preoperative CT scan in staging external auditory meatus carcinoma: radiologic-pathologic correlation study. *Otolaryngol Head Neck Surg* 104: 6-11.
21. Zanoletti E, Lovato A, Stritoni P, Martini A, Mazzoni A, et al. (2015) A critical look at persistent problems in the diagnosis, staging and treatment of temporal bone carcinoma. *Cancer Treat Rev* 41: 821-826.
22. Dong F, Gidley PW, Ho T, Luna MA, Ginsberg LE, et al. (2008) Adenoid cystic carcinoma of the external auditory canal. *Laryngoscope* 118: 1591-1596.
23. Moore MG, Deschler DG, McKenna MJ, Varvares MA, Lin DT (2007) Management outcomes following lateral temporal bone resection for ear and temporal bone malignancies. *Otolaryngol Head Neck Surg* 137: 893-898.
24. Kinney SE, Wood BG (1987) Malignancies of the external ear canal and temporal bone: surgical techniques and results, *Laryngoscope* 97: 158-164.
25. Holt A, Van Gestel D, Arends MP, Korevaar EW, Schuring D, et al. (2013) Vliet-Vroegindeweyji, Multi-institutional comparison of volumetric modulated arc therapy for head and neck cancer: a planning study. *Radiat Oncol* 8: 8-26.

**Copyright:** © 2016 Vallarelli S, et al. This is an open-access article distributed under the terms of the Creative Commons Attribution License, which permits unrestricted use, distribution, and reproduction in any medium, provided the original author and source are credited.

**Citation:** Vallarelli S, Stucci S, Tucci M, Quaranta N, Russo D, et al. (2016) Adenocarcinoma of Ceruminous Glands: Role of the VMAT. *Arch Otolaryngol Rhinol* 2(1): 009-012. DOI: 10.17352/2455-1759.000013