

Mohamed Tarek Hafez^{1*}, Khaled Abdel Wahab¹, Sameh Roshdy¹, Fayez Shahatto¹, Waleed el Nahas¹, Mohamed El Metwally¹, Fathy Denewer², Omar Farouk¹ and Adel Denewer¹

¹Surgical oncology unit, Mansoura oncology center, Mansoura University, Egypt

²General surgery, Mansoura insurance hospital, Egypt

Dates: Received: 06 June, 2016; Accepted: 25 June, 2016; Published: 28 June, 2016

***Corresponding author:** Dr. Mohamed T Hafez, Lecturer of Surgical Oncology Oncology Center, Mansoura University, Egypt, Tel: 00201211700004; E-mail: MTHAFEZ@yahoo.com

www.peertechz.com

ISSN: 2455-1759

Keywords: Mandibular reconstruction; Microvascular; Free flap

Research Article

Versatility in Mandibular Reconstruction after Ablative Tumor Surgery, Single Center Experience

Nowadays, reconstruction after mandibular tumor resections requires high level of complexity that not only puts into consideration the type of the bone flap to acquire accepted cosmetic and functional outcome, but also, decreasing the donor-site morbidity and the probability of using prosthesis, promoting higher quality of life [14].

The aim of this study is to assess the feasibility and versatility of mandibular reconstruction using three different vascularized osteocutaneous flaps; fibular free flap, iliac crest free flap and pedicled sternocleidomastoid clavicular flap.

Patients and Methods

Patients' characteristics

This is a retrospective study studying patients admitted to our surgical oncology department in Mansoura oncology center, Mansoura University diagnosed with mandibular tumors or intraoral tumors infiltrating the mandible between June 2011 & February 2016. Ethics approval was obtained from the Ethics Committee board of the Faculty of Medicine, Mansoura University.

Forty patients were enrolled in this study. Sixteen patients were males and 24 were females, their ages ranged from 19 – 63 years. All tumors were primary except seven cases were recurrent after successful surgical resection. The pathologic diagnosis was ameloblastoma in 24 patients, intra oral carcinomas infiltrating the mandible 12 patients and skin Sq.C.C infiltrating the mandible in 4 patients. All Patient Characteristics are shown in Table 1. 18 patients had Fibular Free Flaps (Figure 1), 10 patients had Iliac Crest Free

Introduction

Mandibular reconstruction using vascularized osteocutaneous flaps is necessary to improve functional outcomes, such as jaw movement and mastication, and aesthetics after the wide resection of the mandible [1].

Bone grafts had been widely used for reconstruction, with the advent of microsurgery, such as rib [2], metatarsal [3], radial [4], scapular [5], iliac [6], and fibular [7,8].

Using the fibula for reconstruction of mandibular defects through microvascular technique was first described by Hidalgo in 1989 [9]. This microvascular flap depends on peroneal artery and the accompanying veins. This flap is characterized by rich vascularity with a long and wide pedicle as the vascular nourishment to this bone comes through both segmental and intraosseous ways, so, it can withstand multiple osteotomies without fear from any ischemic complications [10]. This makes reconstruction of large defects after radical tumor resection more easy.

Thirty years ago, iliac crest was the first choice for surgeons in reconstruction of the mandible after tumor resections. The resemblance of the iliac crest to the contour of the mandible made it suitable for such reconstruction [10]. In the earlier series, the superficial circumflex iliac vessels were utilized in the free microvascular anastomosis for the conjoined skin flap with iliac bone. Later, Taylor et al. proved the advantage of utilizing the deep circumflex system [11].

Sternocleidomastoid clavicular flap was first reported by Colney for reconstruction of mandibular defects in 1972, using the medial fragment of the clavicle [12]. Later, some reconstructive surgeons talked about some modifications of this technique to improve the outcome of this free microvascular flap [13].

Table 1: Patients Characteristics.

	Number (Total 40)	%
Gender :		
Male	16	40%
Female	24	60%
Mean age in years (Range)	40.5 (19 – 63)	
Tumor pathology:		
Adamantinoma (Ameloblastoma)	24	60%
Intra-oral carcinomas infiltrating the mandible	12	30%
Skin Sq.C.C infiltrating the mandible	4	10%
Primary versus recurrent:		
Primary	33	82.5%
Recurrent	7	17.5%
Reconstruction methods:		
Fibular Free Flaps	18	45%
Iliac Crest Free Flaps	10	25%
Pedicled Sternocleidomastoid Myo-osseous (Clavicular) Flap	12	30%

Flaps (Figure 2) and 12 patients had Pedicled Sternocleidomastoid Myo-osseous (Clavicular) Flap (Figures 3,4).

The general medical condition and suitability for prolonged and multiple operations, as well the willingness and the psychological background were addressed before embarking on a prolonged and demanding treatment plan, in our study, we did not exclude patients who are smoking (10 patients were smokers), or diabetics (5 patients were diabetics), however, patients with a grave prognosis, Raynaud syndrome, scleroderma, other collagen vascular diseases, critically ill, sever cardiovascular or respiratory disease or have uncontrolled coagulopathy, were excluded, as these conditions may increase post-operative morbidity or mortality .

In our work, we always did an ultrasonic Doppler flow meter to assess the vascular patency of the neck area, as well as of the donor-lower flap (in case of fibular free flaps). This also enabled us to evaluate any incidental variations in the anatomy, so as to decrease the postoperative affection of vascularity to the flap, the neck and the leg. We used Multi slice Computed Tomography (CT) scans of the head and neck (recipient area) as well, for understanding the expected defect. Also, Panoramic X-ray of the jaw was essential in planning the resection limit.

Mandibular tumor resection

In all patients, the safety margins of resection were assessed by intra-operative frozen section to ensure the complete tumor resection with free safety margin (Figure 3a-c). Among the 24 patients having ameloblastoma, most of the mandibular defects were lateral defects near the angle (16 patients with lateral defects), and 2 patients had central mandibular defects, 4 patients with (lateral and central) mandibular defects and lastly 2 patients with hemimandibular defects (with preserved temporomandibular joint at time of resection). At the recipient area, after tumor resection, the length of the defect was accurately measured by using preoperative panoramic radiographs (Figure 5), CT estimation (Figure 6) and intra-operative ruler (Figure 1b). The length of the defect in combination with the location is the guide for us to select the most appropriate graft configuration.

Harvesting of the flaps

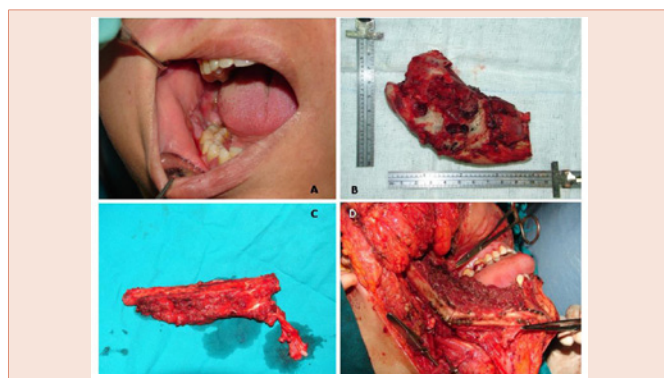


Figure 1: Fibular free flap. **A:** preoperative view; **B:** complete resection with free safety margin; **C:** the fibular free flap after its harvest; **D:** the final view after flap fixation.

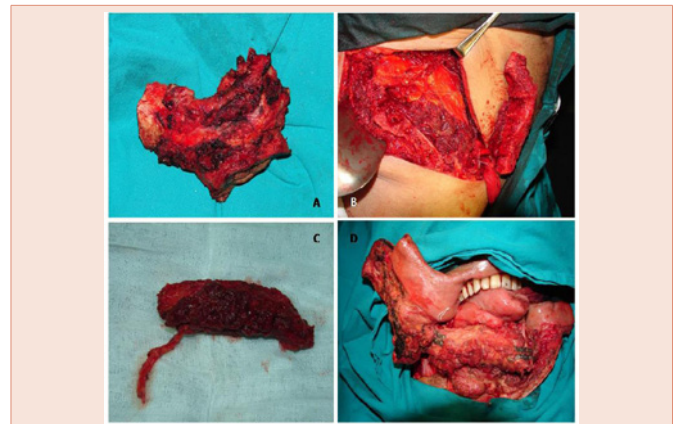


Figure 2: Iliac crest free flap. **A:** Mandibular tumor after resection; **B:** Harvest of the iliac crest flap and its bed; **C:** Iliac crest flap after its harvest; **D:** Final view of mandibular reconstruction.

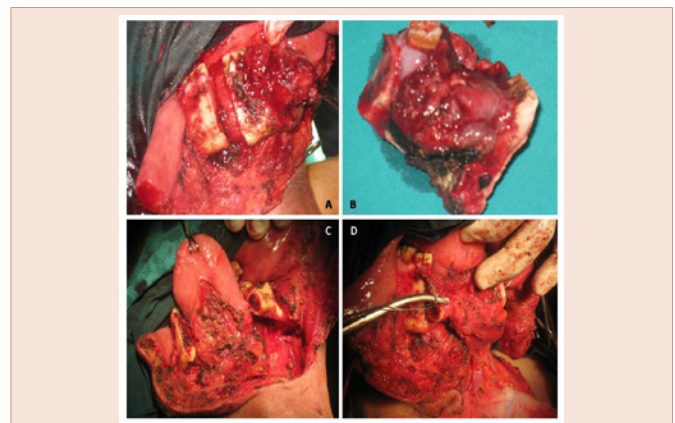


Figure 3: Pedicled sternocleidomastoid myo-osseous (clavicular) Flap. **A:** Resection of mandibular tumor; **B:** complete resection with free safety margin; **C:** Mandibular view after resection; **D:** Fixation of the pedicled sternocleidomastoid myo-osseous (clavicular) Flap.

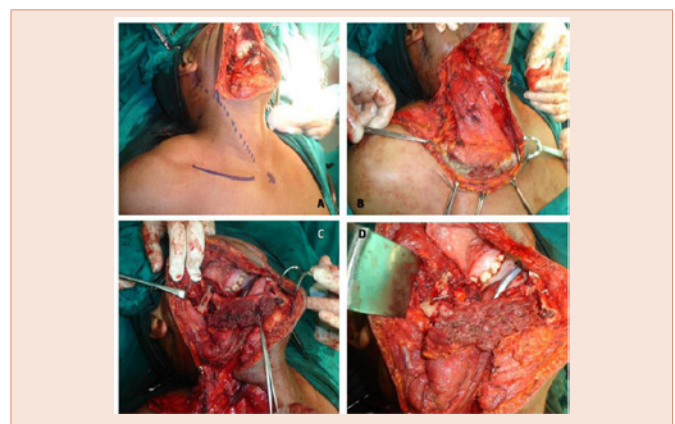


Figure 4: Patient with pedicled sternocleidomastoid myo-osseous (clavicular) Flap. **A:** Marking site of incision after finishing mandibular tumor resection; **B:** Dissection around clavicle; **C:** Transfer of flap; **D:** Fixation of pedicled sternocleidomastoid myo-osseous (clavicular) Flap.

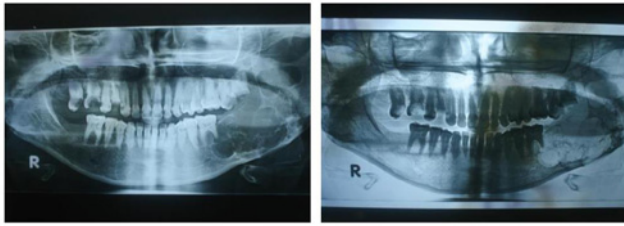


Figure 5: Preoperative panoramic x-rays view of left mandibular ameloblastoma.

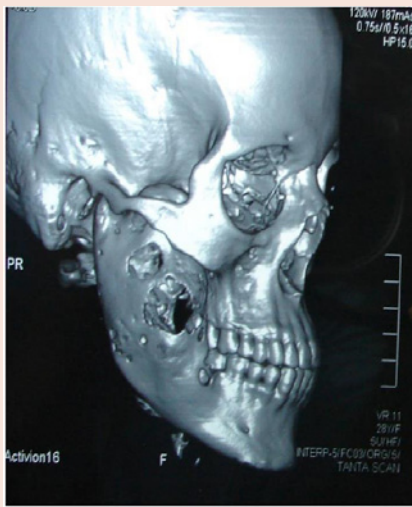


Figure 6: Preoperative CT view of right mandibular ameloblastoma.

Fibular free flap: We used the lateral approach, where the plane between the peroneal muscles and the soleus was developed and the anterior compartment was entered and after osteotomies of the fibula, dissection of the graft and the vascular pedicle was carried out with release of the flexor hallucis longus and posterior tibial muscles. Proximal and distal osteotomies were performed at the appropriate locations to produce a graft of the desirable size with a sharp bone-cutting instrument. The peroneal vessels were identified, ligated and freed distally. After exposing and freeing the origin of the peroneal vessel pedicle, the tourniquet may be deflated with the graft remaining in situ until preparation of the recipient site is complete, to reduce the total time of graft ischemia. If the recipient site is ready, the graft is harvested at this point.

Iliac crest free flap: In our work, we used to harvest myoosseous flap without raising a skin island, beginning just lateral to the femoral artery. Firstly, we begin with performing a skin incision. This is followed by cutting of internal oblique muscle down to fascia transversalis. Then, we search for the pulse of the DCIA and, at this stage, we had to expose and dissect the vascular pedicle. As soon as the pedicle had been exposed, we perform an extension along the length of the iliac crest reaching the external oblique muscle. Then, we try to feel the lateral edge of the iliac crest bone, and also, we cut the muscles at the gluteal side of the pelvis. The abdominal wall

muscles were retracted in a cranial direction and bluntly undermined medial to the iliac crest, keeping the plane of dissection superficial to the pedicle. An important point is to keep about 2 cm distance from the inner rim of the iliac crest, where the abdominal muscles were transected with scissors from a caudal to a cranial direction.

Then, osteotomy starts distally at the iliac crest after cutting of the abdominal muscles that covers the bone. We always use the oscillating saw cuts through the inner and outer cortical bone until the desired depth of bone segment is achieved. While doing this, the soft tissues are retracted with broad hooks to protect the peritoneum and to visualize the blade during the osteotomy. The vascular pedicle is transected and ligated at the distal osteotomy. Osteotomy is continued by cutting the bone bicortically in an anterior direction, keeping a parallel distance from the upper rim of the iliac crest. The osteotomized bone segment is elevated, and residual muscle fibers are transected. Perfusion of the flap is maintained until the recipient vessels are ready for anastomosis. Finally, the wound is closed.

Pedicle Sternocleidomastoid myo-osseous clavicular flap: In this study we depended on the pedicle sternocleidomastoid myo-osseous clavicular flap to be the first choice reconstructive option in those patients with poor recipient neck vessels or limited mandibular defect not more than 10 cm. We used vertical S shaped incision over the sternocleidomastoid muscle. The clavicle was stabilized and retracted anteriorly using bone holding forceps, then it was cut using Gigli saw starting laterally close to the trapezius border. After making the lateral osteotomy, freeing of the clavicle from subclavius, pectoralis minor and costoclavicular ligaments was performed. Medially, we cut the clavicle as close as possible to the sternoclavicular joint. We have routinely identified and secured the spinal accessory nerve at the posterior border of sternocleidomastoid. After blunt dissection of the posterior surface of the sternocleidomastoid, the clavicle attached to the sternocleidomastoid is free to be rotated for mandibular reconstruction.

Mandibular defect reconstruction

In cases with free flaps, the circulation was usually reestablished by direct anastomosis to regional arteries and their companion veins. These are most often exposed through an incision proximal to, yet connected with the defect. Heparin solution (5000 units in 100 cc of saline) and vasodilating solutions (Xylocaine) are used during surgery to clear the vessels ends and to prevent spasm. Vessel anastomoses were performed under 5X loop magnification with 8.0 nylon sutures. The arterial anastomosis was usually performed first to minimize ischemia time. In our study; the dominant Blood Supply was; posterior auricular, occipital arteries for the upper third of the mandibular reconstruction, inferior thyroid artery for the middle third and transverse cervical, suprascapular arteries for lower third.

The free bone grafts was fixed with mini plates and screws (Figures 1d,2d) in 25 patients and with wire in 15 patients (Figures 3d,4d).

While the patient is still under the effect of general anesthesia, we always perform a final assessment of the viability of the flap through clinical observation, and vascular flow is confirmed with doppler examination. The location of Doppler signal in the flap was marked with a stitch for postoperative monitoring.

One intravenous bolus of heparin (5000 units in adults) was administrated at the time of completion of the anastomoses, and one aspirin tablet per day postoperatively for 3 weeks.

Follow up

All patients with free flaps were monitored for one week by colour Doppler on the site of anastomosis marked on the skin. For cases with fibular septocutaneous flap, monitoring of the skin paddle inside the oral cavity was done by pin pricking. All patients start oral fluids on the 7th day postoperative.

Results

All flaps survived; no total or partial flap loss, yielding an overall success rate of 100 % (Figure 7). Average follow-up was 16.2 months (range: 2 - 30), during it, we observed local recurrence in 4 cases. We observed satisfactory speech and acceptable masticatory functions among all patients without any dental implants.

Of 40 patients included, 16 patients (40%) experienced minor complications (Table 2). Three patients had donor site hematoma; one was from the fibular free flap group who developed it at the 4th day, and the other two patients were from iliac crest free flap group, all needed evacuation. Incisional hernia at the donor site of iliac crest free flap occurred in one patient and was managed conservatively. One patient with fibular free flap showed wound gap and needed 2ry suture. Three patients among the fibular free flap group had donor sit infection which was managed conservatively.

As regards the recipient site complications, most occurred in the fibular free flap group; two patients had bleeding from vascular anastmosis during the first 2 days and managed conservatively, one patient developed hematoma at the 6th day and managed by evacuation, two patients had donor sit infection which was managed conservatively, one patient developed oro-cautaneous fistula as a result of tension suturing and it was treated conservatively for 15 days,

Table 2: Complications.

		Fibular free flaps (18)	Iliac crest free flaps (10)	Pedicled sternocleidomastoid myo-osseous (clavicular) flap (12)
Donor:	Hematoma	1	2	0
	Incisional hernia	0	1	0
	Wound gaping	1	0	0
	Infection	3	0	0
Recipient:	Bleeding from vascular anastmosis	2	0	0
	Hematoma	1	0	0
	Infection	2	0	0
	Oro-cautaneous fistula	1	0	0
	Mild facial asymmetry	1	2	0

and one patient had mild facial asymmetry, while it was experienced in two patients among the iliac crest free flap group.

Pedicled sternocleidomastoid myo-osseous (clavicular) flap group showed no complications at all.

Discussion

Mandibular reconstruction is always considered as a difficult and challenging mission, especially if the mucosa will be excised in association with the mandible [14].

In 1973, free fibular flap was proposed as a good option for microvascular techniques by both Ueba and Fujikama in Japan and O'Brien and Morrison in Melbourne, Germany [15,16].

The vascularised fibula first reported by Hidalgo has been a preferred donor site because of its length and versatility [9]. Fibular free flap is characterized by satisfactory cosmetic and functional outcomes and acceptable level of post-operative morbidity. It is considered as the first option for patients who need mandibular reconstruction [14,17].

Owing to many articles, microvascular free fibular flap is considered the best option for reconstruction of mandibular defects, and, so, was then considered standard procedure in an increasing number of microsurgical centers around the world, because of its straightforward dissection which facilitates a two-team approach [8,9,14,18-20].

Hidalgo reported 100% success rate using the microvascular fibular free flap [9]. Also, Cordeiro and his team found a similar success rate of 100% on using this flap [21]. Bhuju et al., reported the results of 63 fibular free flaps; all the flaps were surviving well and the success rate was 100% and facial asymmetry was reported in 12% patients of benign and 50% patients of malignant group. These results agreed with our study results as regards the success rate of 100%, however we reported more better facial symmetry (only 1/18 = 5.5%) developed facial asymmetry which was mild [17].

We did not report long term disabilities related to donor site in this study, as other authors reported [8,17,22].

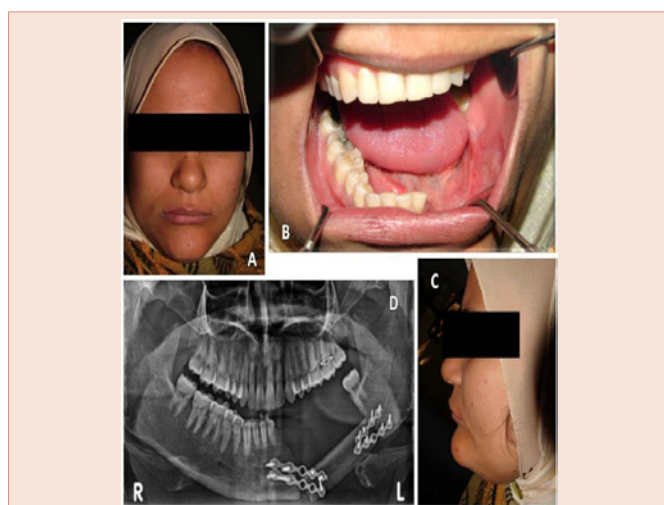

Figure 7: Six weeks postoperative of female patient 32 years with ameloblastoma in the right mandible after fibular free flap reconstruction; A: Frontal view; B: Intraoral view; C: Digital panoramic view; D: lateral view.

Moreover, using free fibular microvascular flap is considered the best option for reconstruction defects of long bone [14], where, using it, we can attain a length up to 30 cm of bone length which is enough for reconstructing any length of the mandible. Therefore, it remains the first choice for the edentulous mandible or for extensive mandibular resections [10], whereas the iliac crest finds its use for a curved bone defect [14].

In contrary, Brown et al. proposed the iliac crest free flap as a feasible option in dentate patients because of the superior bone height, which provide enough support for implants [23].

The easiness of using the sternocleidomastoid muscle flap depended mainly on the way the neck dissection was performed, i.e. with or without inclusion of the muscle [13]. In our work, the pedicled sternocleidomastoid myo-osseous clavicular flap was preserved to be the first choice reconstructive option in those patients with poor recipient neck vessels or limited mandibular defect not more than 10 cm .

Some authors reported that using iliac bone for reconstruction of mandibular defects caused higher morbidity when it is compared to the free fibular flap [24]. However, in this work, there were no significant differences between the different surgical procedures used in mandibular reconstruction as regards to morbidities which all were minor problems. This may be due to good selection of cases for each procedure especially when choosing free flap techniques that were subjected to strict inclusion and exclusion criteria. The immediate post-operative complications are best avoided by a careful patient history, experienced surgeon hands and proper medications like anticoagulants, antibiotics, analgesics and anti-inflammatory agents [25].

Conclusion

Fibular and Iliac crest free flaps should be first considered as regard mandibular reconstruction. Both flaps are versatile and reliable with minimum donor site morbidity. The choice of the flap depends mainly on defect size and location. We recommend fibular free flaps in defects when bony length is required. We recommend iliac crest free flap in defects at the mandibular angle and in defects which need more soft tissue bulk. Pedicled sternocleidomastoid myo-osseous clavicular flap is a quick and simple technique. It should be preserved for cases in which free flap reconstruction is contraindicated or as a backup flap after failure of free flap reconstruction.

References

1. Yamanaka Y, Yajima H, Kirita T, Shimomura H, Tamaki S, et al. (2010) Mandibular reconstruction with vascularised fibular osteocutaneous flaps using prefabricated stereolithographic mandibular model. *Br J Plast Surg* 63: 1010, 1751-1753.
2. Serafin D, Riefkohl R, Thomas I, Georgiade NG (1980) Vascularized rib-periosteal and osteocutaneous reconstruction of the maxilla and mandible: an assessment. *Plast Reconstr Surg* 66: 718-727.
3. MacLeod AM, Robinson DW (1982) Reconstruction of defects involving the mandible and floor of the mouth by free osteocutaneous flaps derived from the foot. *Br J Plast Surg* 35: 239-246.
4. Soutar DS, Scheker LR, Tanner NSB, McGregor IA (1983) The radial forearm flap: a versatile method for intra-oral reconstruction. *Br J Plast Surg* 36: 1-8.
5. Toet L, Bosse JP, Moufarrege R, et al. (1981) The scapula crest pedicled bone graft. *Intern J Microsurg* 3: 257-261.
6. Taylor GI (1982) Reconstruction of the mandible with free composite iliac bone grafts. *Ann Plast Surg* 361-376.
7. Wei FC, Seah CS, Tsai YC, et al. (1994) Fibula osteoseptocutaneous flap for reconstruction of composite mandibular defects. *Plast Reconstr Surg* 93: 294-304.
8. Hidalgo DA, Pusic AL (2002) Free flap mandibular reconstructions: a 10-year follow-up study. *Plast Reconstr Surg* 110: 438-449.
9. Hidalgo DA (1989) Fibula free flap: a new method of mandible reconstruction. *Plast Reconstr Surg* 84: 71-79.
10. Goh BT, Lee S, Tideman H, Stoelting PJ (2008) Mandibular reconstruction in adults: a review. *Int J Oral Maxillofac Surg* 37: 597-605.
11. Taylor GI, Townsend P, Corlett R (1979) Superiority of the deep circumflex iliac vessels as the supply for free groin flaps. *Clinical work. Plast Reconstr Surg* 64: 745-759.
12. Conley J (1972) Use of composite flaps containing bone for major repair in head and neck. *Plast Reconstr Surg* 49: 522-526.
13. Tiwari R (1994) Mandibular reconstruction with conventional bone graft. In: Soutar DS, Tiwari R, eds: *Excision and Reconstruction in Head and Neck Cancer*. Edinburgh: Churchill Livingstone 59-85.
14. Papadopoulos NA, Schaff J, Robert Sader, Kovacs L, Deppe H, et al. (2008) Mandibular reconstruction with free osteofasciocutaneous fibula flap: A 10 years' experience. *Injury* S75-S82.
15. Fonceka RJ (2000) *Oral and Maxillofacial Surgery*. Philadelphia: Saunders Company 364-365.
16. Wolff KD, Hözle F (2005) *Raising of Microvascular Flaps-A Approach*. Berlin: Springer-Verlag Berlin Heidelberg 107-137.
17. Bhuju K G, Xing S, Liu H (2008) Evaluation of mandibular reconstruction with free vascularized fibular flap. *J Biomed Res* 22: 23-27.
18. Hidalgo DA, Rekow A (1995) A review of 60 consecutive fibula free flap mandible reconstructions. *Plast Reconstr Surg* 96: 585-596.
19. Santamaria E, Wei FC, Chen HC (1998) Fibula osteoseptocutaneous flap for reconstruction of osteoradionecrosis of the mandible. *Plast Reconstr Surg* 101: 921-929.
20. Wei FC, Seah CS, Tsai YC, Liu SJ, Tsai MS (1994) Fibula osteoseptocutaneous flap for reconstruction of composite mandibular defects. *Plast Reconstr Surg* 93: 294-304.
21. Cordeiro P, Disa JJ, Hidalgo DA, Hu QY (1999) Reconstruction of the mandible with osseous free flaps: A 10-year experience with 150 consecutive patients. *Plastic and Reconstr Surg* 104: 1314-1320.
22. Abdel WAA (2003) Osteocutaneous free fibular flap for anatomical reconstruction of the mandible following tumor resection. *J Egypt Natl Canc Inst* 15: 243-251.
23. Brown JS, Magennis P, Rogers SN, Cawood JI, Howell R, et al. (2006) Trends in head and neck microvascular reconstructive surgery in Liverpool (1992-2001). *Br J Oral Maxillofac Surg* 44: 364-370.
24. Shpitzer T, Neligan PC, Gullane PJ, Boyd BJ, Gur E, et al. (1999) The free iliac crest and fibula flaps in vascularized oromandibular reconstruction: comparison and long-term evaluation. *Head Neck* 21: 639-347.
25. Babak JM, Cordeiro PG (2003) Avoiding and dealing with complications after head and neck microvascular reconstruction. *Semin Plast Sur* 17: 267-274.

Copyright: © 2016 Hafez MT, et al. This is an open-access article distributed under the terms of the Creative Commons Attribution License, which permits unrestricted use, distribution, and reproduction in any medium, provided the original author and source are credited.

Citation: Hafez MT, Wahab KA, Roshdy S, Shahatto F, el Nahas W, et al. (2016) Versatility in Mandibular Reconstruction after Ablative Tumor Surgery, Single Center Experience. *Arch Otolaryngol Rhinol* 2(1): 030-034. DOI: 10.17352/2455-1759.000019