

Xiaoli Li¹, Zhenghui Wang^{2*},
Zhuangqun Yang³ and Min Xu¹

¹Department of Dermatology, The Second Hospital, Xi'an Jiaotong University, Xi'an 710004, China

²Department of Otolaryngology-Head and Neck Surgery, The Second Hospital, Xi'an Jiaotong University, Xi'an 710004, China

³Department of Plastic and Burns Surgery, The First Hospital, Xi'an Jiaotong University, Xi'an 710061, China

Dates: Received: 04 July, 2015; Accepted: 24 August, 2015; Published: 26 August, 2015

***Corresponding author:** Zhenghui Wang, Department of Otolaryngology-Head and Neck Surgery, The Second Hospital, Xi'an Jiaotong University, Xi'an 710004, China, Tel: +86 029 87679866; Fax: +86 029 87678421; E-mail: ehui4298@163.com

www.peertechz.com

ISSN: 2455-1759

Keywords: Hemifacial microsomia; Cephalometric analysis

Research Article

A Cephalometric Analysis of Hemifacial Microsomia

Abstract

Objective: The purpose of the present study was to analyze the facial asymmetry systematically using the cephalometric method, so as to demonstrate the difference on both sides of Hemifacial microsomia(HFM) in adult.

Study Design: Twelve adults of HFM were chosen, and the muscles and velocity of conduction of facial nerve were measured using the electromyographic machine. We collected all the patients' cephalometric radiographs in the anterior and posterior projections and analysed the size and symmetry of orbit, maxilla and mandible.

Results: We found the dysfunction of muscles and facial nerves on the affected side of HFM. The main differences on both sides were the mandible and the changes in the orbit, but the maxilla had no significant difference.

Conclusion: The quantitative analysis supports the objective data for clinic and the hard tissues and soft tissues must be considered in order to help with the treatment of HFM.

Introduction

Hemifacial microsomia, or HFM, is the most frequently encountered form of isolated facial asymmetry [1,2]. Affecting approximately one in 5,000 births and ranking second only to cleft lip and palate among the most common facial anomalies, HFM is a congenital malformation in which there is a deficiency in the amount of hard and soft tissues on one side of the face (Figure 1), [3,4]. It is a primary syndrome of the first branchial arch, involving underdevelopment of the temporomandibular joint, mandibular ramus, mastication muscles and the ear. The disorder may be from mild to severe; involvement limited to one side is most common, but bilateral involvement also occurs with more severe expression on one side. The condition overlaps with Goldenhar syndrome [5]. A wide spectrum of abnormalities have been described, and many terms used to designate the condition emphasize the nosologic problems encountered trying to establish rigid diagnostic criteria [6-8]. The causes of HFM (oculoauriculovertebral spectrum) are unknown.

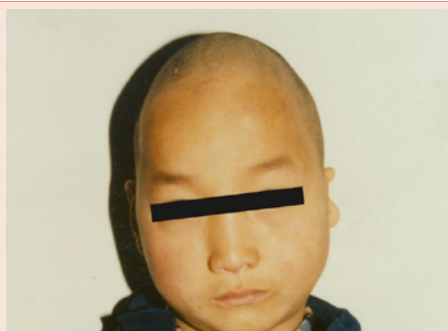

Figure 1: A boy with HFM on the left affected side.

Clinical and genetic evidence to date strongly suggests that the condition is etiologically heterogeneous [8].

Auricular anomalies, ranging from pre auricular tags to anotia, have been documented [9,10]. Mandibular anomalies range from mild reduction in mandibular size but with near normal morphology to complete absence of the ramus [10]. The masticatory muscles on the affected side have been shown to exhibit varying degrees of hypoplasia or even to be altogether absent [11-13].

Several studies have attempted to correlate between the severities of the individual characteristics of HFM. Figueroa and Pruzansky [9] found a significant relationship between severity of ear and severity of jaw malformations in a large sample of HFM subjects, but striking exceptions were encountered. Similar observations were made by Vento et al. [12]. Kane et al. [13], found that the extent of hypoplasia of specific muscles of mastication predicts the extent of dysplasia of the mandible, whereas the reverse is not true. Markio Takashima et al. [14] and Clara E. Huisinga Fischer et al. [15], had examined the difference in the degrees of right-left disproportion between the masticatory muscles to determine whether specific muscles are affected in HFM. Both Farias and Vargervik [16] and Silvestri et al. [17], found a positive relationship between agenesis of teeth on the affected side and the severity of jaw malformation. In addition, Farias and Vargervik [16] found a relationship between delayed tooth development on the affected side and the degree of mandibular involvement, whereas Loevy and Shore [18], did not find such a relationship in their study of 89 HFM patients. Thus, the spectrum of severity for each of the major phenotypic characteristics of HFM is highly variable, and the interrelationships of the severity of the traits have so far not shown precise and consistent correlations. These studies only analyzed the ear or mandibular, or disproportion of the masticatory muscles in HFM. No previous studies have, however, attempted to analyze the possible relationship between the severity

of both ear, orbit, mandibular, and the degree of disproportion of the masticatory muscles in HFM adult subjects. The purpose of the present study was to analyze the facial asymmetry on hard and soft tissues systematically using the cephalometric method, so as to demonstrate the difference of hard and soft tissues of non-affected side and affected side of HFM. Trying to find the possible relationship of hard and soft tissues will provide the objective help for clinical surgery.

Materials and Methods

Subjects

All procedures were approved by the Ethics Committee of Xi'an Jiaotong University (Xi'an, China). The study group consisted of 12 adults (9 male and 3 female, mean age 19 years 7 months, age ranges from 18 to 23 years) with hemifacial microsomia. All patients had ear loss on affected side and none of them had undergone facial surgery. Nine of the patients had affected mandibles on the right side, and the others had affected mandibles on the left side.

Data collection

We measured all the patients' three masticatory muscles (Masseter, Lateral Pterygoid, Medial Pterygoid), mimetic muscles (zygomaticus, sphincter of eye, quadratus muscle of upper lip) and the velocity of conduction of facial nerve (four branches) from both sides by the electromyographic machine (MEN-3102, Japan), and analyzed the action potential, insertion potential and the velocity of conduction of per patients. We collected all the patients' cephalometric radiographs in the anterior-posterior projections (A-P position) using cephalometric X-machine (TEXCOCP-323, Japan) (Figure 2) and a panoramic radiograph of the jaws (PRNEX-E, X-100E, Japan). We then delineated the radiograph shadows on the vegetable parchment, measured them using the rule of 0.5mm precision. All the data were collected and measured by one person.

According to the cephalometric method of Grummons¹⁹, the line of crista galli and anterior nasal spine (ANS) was considered a perpendicular reference line (midline) (Figures 3,4). The line connecting the midpoint of zygomaticofrontal suture on both sides

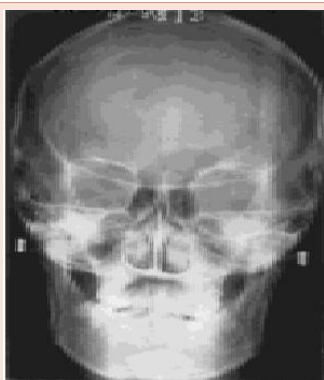


Figure 2: The A-P cephalometric radiographs of right hemifacial microsomia.

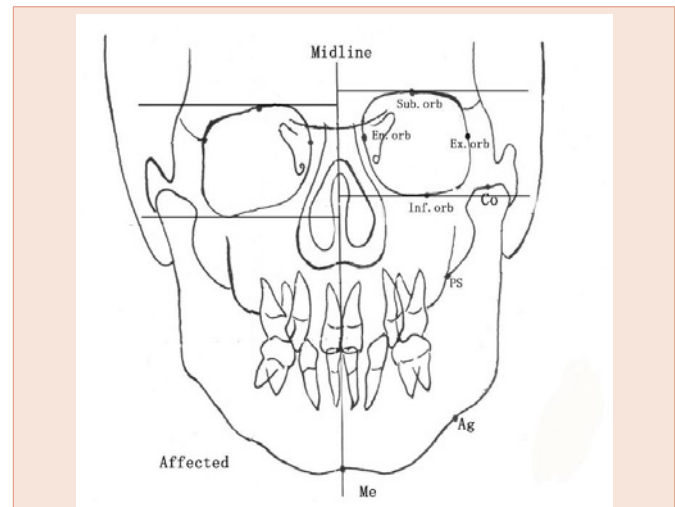


Figure 3: The described measurement points of cephalometric radiographs.

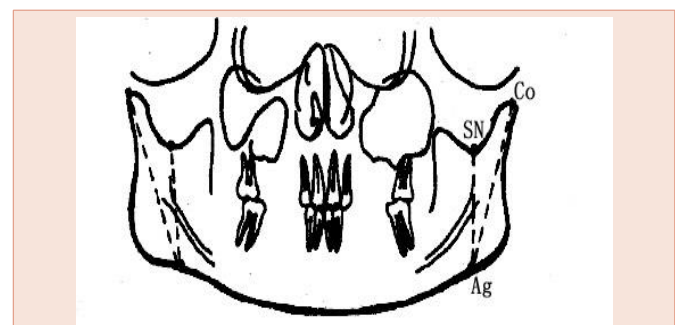


Figure 4: The described measurement points of panoramic radiograph.

was considered a horizontal line. We chose four points of acromioclavicular joint (Co), antegonial notch of mandible (Ag), simoid notch (Sn) and menton (Me) to measure the length of mandibular ascending ramus (Co-Ag), mandibular body (Ag-Me), general mandible (Co-Ag) and the height of mandibular ascending ramus (Sn-Ag). The orbital height and width were measured by choosing supra-orbital point (sup. orb), infra-orbital point (inf. orb), entorbital point (en. orb) and extra-orbital point (ex. orb). Then we measured the height difference of vertical from sup. orb and inf. orb to the midline of affected and unaffected sides, and the distance from en. orb to midline. The distance from palatine shelf (PS) to the midline and from PS to Inf. orb described the width and height of maxilla respectively.

The data were analyzed using the SPSS 10.0 statistical software (SPSS, Chicago, IL, USA). Student's t test were carried out with the relative differences between the affected and unaffected sides. A 5% level of significance was chosen for these tests.

Results

The appearance of electromyogram

The result of insertion potential of 48 mimetic muscles on both

sides showed normal on the whole on the unaffected side of all the patients, and there were pathological insertion potential of 13 muscles on the affected side, at a percentage of 27.08%(13/48).

During the contraction of masticatory muscles, the wave amplitude of action potential on the affected side decreased 30.4% as compared to the normal side. The wave amplitude of action potential on the affected side ranged from 200uV^t to 300uV^t, the percentage of mixed phase and confusing phase was about 29.6% and 70.4% respectively.

Of all the 48 facial nerves in the patients on both sides, the velocity of conduction of 15 nerves decreased on the affected side, and there were abolition of reflex of 2 nerves among them. The mean velocity

of conduction on the affected side decreased 35.4% as compared to the normal side.

The delineate results of radiogram

According the points described, the length of mandibular ascending branch, mandibular body and general mandible were measured and **Table 1** shows the difference of mandible on both sides with cephalometric radiographs, and there was significant difference (P<0.01). And **Table 2** shows the difference of mandible with panoramic radiograph by choosing the simoid notch, there was also significant difference (P<0.01). No significant difference (P>0.05) was observed from changes of maxilla with cephalometric radiographs (**Table 3**).

Table 1: The difference of mandible on both sides with cephalometric radiograph.

Patient No.	Co-Me			Co-Ag			Ag-Me		
	unaffected-d side	affected side	differen -ce	unaffected side	affected side	differen -ce	unaffected-d side	affected side	differen-ce
1	118	112	6	66	63	3	70	61	9
2	112	85	27	74	50	24	52	45	7
3	120	111.5	8.5	68	60	8	68	61.5	6.5
4	122.5	121.5	1	77	75	2	64	55.5	8.5
5	447	106	44	72	65	7	56.5	49	7.5
6	121	113	8	68.5	64	4.5	60	56.5	3.5
7	117	115	5	76.5	7.	3.	55.5	54.5	1
8	112.5	122	0.5	75.5	74	1.5	56	54	2
9	103	94.5	8.5	79	66	13	47.5	32	15.5
10	92.5	91	1.5	63.5	63	0.5	50.5	46	4.5
11	92	90	2	66.5	64.5	2	53	48.5	4.5
12	119	103	16	76	70.5	5.5	61	54	7
	t=3.11 P<0.01			t=3.26 P<0.01			t=5.179 P<0.01		

Co: acro- condyle Ag: Antegonial notch of mandible Me: menton.

Table 2: The difference of mandible on both sides with panoramic radiograph.

Patient No.	Co-Ag			simoid notch(Sn)-Ag		
	unaffected side	affected side	difference	unaffected side	affected side	difference
1	81	78	3	57	55	2
2	82	65	17	61	53	8
3	87	82	5	63	59	4
4	85.5	82	3.5	66	60.5	5.5
5	78	76	2	66.5	60.5	6
6	77	73.5	3.5	55	52	3
7	90	86	4	65	62	3
8	90	87	6	73.5	56.5	17
9	85	63	22	65	52	13
10	78	74	2	54	52	2
11	78	73	5	55	53	2
12	84	63	21	66	59	7
	t=3.75 P<0.0.1			t=4.43 P<0.0.1		



The mean height difference of vertical from sup.orb and inf.orb to the midline on both sides are 1.08mm and 2.78mm respectively (Table 4), suggesting the position of orbit on the affected side is lower set than the unaffected side. Table 5 shows the mean angle between the line of midpoint of zygomaticofrontal suture and the midline on affected side is 89.29°, there was no significant difference (P>0.05) when compared with the usual angle 90° of normal people.

The difference of orbital height Table 6 and width Table 7 shows no significant difference (P>0.05) on both sides of hemifacial microsomia. While there was significant difference (P<0.01) of the distance from en.orb to midline on both sides (Table 8).

Discussion

The involvement of various structures of hemifacial microsomia and the great variability of expression of the defects have been well discussed in the literature [5,6,9]. The skeletal and soft tissue deformity in HFM has been shown to deteriorate progressively with age on the affected side, resulting in increasing degree of disproportion between the affected and unaffected side [20]. The predominant features are progressive underdevelopment of the mandible, zygoma, and malar bone and associated soft tissues. The present article chooses, for the first time, the adult of 18-25 years old, precludes the effect of growth factor and plombs the blank study in adult HFM on hard and soft tissues.

Table 3: The difference of maxilla on both sides with panoramic radiograph.

	unaffected side		affected side		P
	mean	standard error	mean	standard error	
height	40.70	2.17	39.15	5.76	>0.05
width	36.17	6.10	35.28	3.14	>0.05

Table 4: The height difference of vertical from sup.orb and inf.orb to the midline (mm).

	1	2	3	4	5	6	7	8	9	10	11	12	mean
sup.orb	0	1.5	0	0	1.0	1.5	4.5	1.0	0.5	1.5	0.5	0.9	1.08
inf.orb	4.5	1.0	8.5	1.8	2.5	3.5	4.8	0	0.5	3.0	0.5	2.8	2.78

Table 5: The angle between the line of midpoint of zygomaticofrontal suture and midline in affected side (°).

	1	2	3	4	5	6	7	8	9	10	11	12	mean
included angle	88.5	90	90	88	89	88	90	89	90	90	89	90	89.29

Table 6: The difference of orbital height from sup.orb to inf.orb on both sides (mm).

	1	2	3	4	5	6	7	8	9	10	11	12	mean
affected side	40	27	26.5	26	33.5	17	23	34	25.5	26	23.5	28.7	27.72
unaffected side	44.5	30	36	28	35	24	23.5	35.5	27	28	23.5	31.6	30.55
difference	-4.5	-3	-9.5	-2	-1.5	-5	-0.5	-1.5	-1.5	-1.5	-2	-2.9	-2.83*

* P>0.05

Table 7: The difference of orbital width from en.orb to ex.orb on both sides (mm).

	1	2	3	4	5	6	7	8	9	10	11	12	mean
affected side	38.5	29.5	34	33	34	28.5	31.5	33	33.5	38.5	31.5	31.5	33.08
unaffected side	35.5	31	33	35	34	29	30	32	33	38.5	31	33.8	32.98
difference	3	-1.5	1	-5	0	-0.5	1.5	1	0.5	0	0.5	-2.3	0.1*

*P>0.05

Table 8: The difference of distance from en.orb to midline on both sides (mm).

	1	2	3	4	5	6	7	8	9	10	11	12	mean
affected side	13	14	16	16	13	14	14	14	13.5	15.5	15	13.7	14.28
unaffected side	17	13	15.5	16	13	13	17	14	17	15	18.5	16.4	15.76
difference	-4	1	0.5	0	0	1	-3	0	-3.8	0.5	-3.5	-2.4	-1.48*

*P<0.05

Because the exact etiology of HFM has not yet been determined, there are many theories based on embryologic, clinical and laboratory studies. Lauritzen et al. [21], considered reasons of hemifacial microsomia was the deformity of bone and temporomandibular joint. Guyaron et al. [22], suggested the main deformity was in soft tissues and repaired the facial deformity with an omental flap. While we found the underdevelopment of bone and soft tissues through long-term observation. The results of electromyogram show the dysfunction of mimetic muscles, masticatory muscles and facial nerves on affected side, which was consistent with dysfunction of the facial nerve and facial muscles coexist with HFM [11]. The changes of maxilla with cephalometric radiographs show no significant difference, possible concerned with the different degrees of maxillary deformity in the group.

Our results of mandible on both sides with cephalometric radiographs show significant difference. The deformity of mandible was often seen and prominently appeared in HFM. No matter the degree of deformity, there is underdevelopment of the mandible and it maybe be the reason that many previous studies were about the mandible.

The mean height difference of vertical from sup.orb and inf.orb to the midline on both sides are 1.08mm and 2.78mm respectively, suggesting the position of orbit on the affected side is lower set than on the unaffected side and the underdevelopment of jaw on the affected side may results in the moving down of orbits. Compared the angle between the line of midpoint of zygomaticofrontal suture and the midline on both sides, there was no significant difference. These results suggest no intortion of orbit in lateral axis and longitudinal axis in spite of the deformity of affected side in HFM.

The results of orbital height and width of both sides show no significant difference, demonstrate the orbital size is not visibly effected by the facial deformity on affected side and the volume of orbit is normal on the whole, which is consistent with no visible exophthalmos in clinic we see. We found the significant difference of orbital size in individual patient, the maximal difference of orbital height was 9.5mm and the maximal difference of orbital width was 3.0mm in the group. However there was still no marked exophthalmos and maybe it was due to the underdevelopment of eyeball on affected side or other reasons. Because of the sample size of subjects in the group, it is worth further study.

Our results of distance from en.orb to midline on both sides show significant difference and the enlarged distance of en.orb to midline on affected side show the extro-moving of orbit from appearance. In clinic we had found the appearance of the widening of orbital distance and asymmetry on both sides. It was prominent enlargement of en.orb to midline on affected side, which was consistent with our results.

The degree of deformity in HFM is different in various ages and affected by the state of growth and development. In present study we regarded the adults as the subjects and couldn't judge the degree of deformity of various ages. Our results of cephalometric analysis in the study suggest the position of orbit in HFM moves outside and

down. The move shows lateral axis of orbit on affected side inclines in outside and inferior direction, however the volume and angle between the line of midpoint of zygomaticofrontal suture and midline of orbit show no significant difference. These results demonstrates the underdevelopment of the mandible and associated soft tissues in the patients and different degrees of deformity of skull, zygoma and malar bone. All the factors result in the moving outside and down of orbital situs. The quantitative analysis supports the objective data for clinic and help effectively diagnose and rehabilitate patients who have HFM. In clinic we must consider the hard tissues and soft tissues, so as to succeed in treatment of HFM.

Acknowledgments

The study was supported by the Foundation of The Second Hospital of Xi'an Jiaotong University. We would like to thank the department of electromyogram and department of the radiology for their cooperation.

References

- Moore KL, Persaud TV (1993) Before we are born: Essentials of embryology and birth defects. 4th ed. Philadelphia: Saunders 118.
- Dimitroulis G, Dolwick MF, Van Sickels JE (1994) Orthognathic surgery: A synopsis of basic principles and surgical techniques. Oxford: Butterworth-Heinemann 78.
- Berry G (1989) Note on congenital defect (coloboma) of the lower lid. Lond Ophthalmol Hosp Rep 12: 255.
- Branchial arch and orofacial disorders. (1990) In: Gorlin RJ, Cohen MM Jr., Levin LS, eds. Syndromes of the head and neck. New York: Oxford University Press 641-652.
- Gorlin RJ, Cohen MM, Levin LS (1990) Syndromes of the Head and Neck. Oxford: Oxford University Press 666-673.
- Cohen MM Jr (1995) Perspectives on craniofacial asymmetry. IV. Hemiasymmetries. Int J Oral Maxillofac Surg 24: 134-141.
- Cohen MM Jr (1997) The Child With Multiple Birth Defects. New York: Oxford University Press 171-177.
- Cohen MM Jr., Rollnick BR, Kaye CI (1989) Oculoauriculovertebral spectrum: an updated critique. Cleft Palate J 26: 276-286.
- Figueroa AA, Pruzansky S (1980) The external ear, mandible and other components of hemifacial microsomia. J Maxillofac Surg 10: 200-211.
- Pruzansky S (1969) Not all dwarfed mandibles are alike. Birth Defects 5: 120-129.
- Marsh JL, Baca D, Vannier MW (1989) Facial musculoskeletal asymmetry in hemifacial microsomia. Cleft Palate J 26: 292-302.
- Vento AR, LaBrie RA, Mulliken JB (1991) The O.M.E.N.S. classification of hemifacial microsomia. Cleft Palate Craniofac J 28: 68-76.
- Kane AA, Lo LJ, Christensen GE, Vannier MW, Marsh JL (1997) Relationship between bone and muscles of mastication in hemifacial microsomia. Plast Reconstr Surg 99: 990-997.
- Takashima M, Kitai N, Murakami S, Furukawa S, Kreiborg S, et al. (2003) Volume and shape of masticatory muscles in patients with hemifacial microsomia. Cleft Palate Craniofac J 40: 6-12.
- Huisinga-Fischer CE, Vaandrager JM, Prah-Andersen B, van Ginkel FC (2004). Masticatory muscle right-left differences in controls and hemifacial microsomia patients. J of Craniofacial Surgery 15: 42-46.
- Farias M, Vargervik K (1988) Dental development in hemifacial microsomia. I. Eruption and agenesis. Pediatr Dent 10: 140-143.



17. Silvestri A, Natali G, Fadda MT (1996) Dental agenesis in hemifacial microsomia. *Pediatr Dent* 18: 48–51.
18. Loevy HT, Shore SW (1985) Dental maturation in hemifacial microsomia. *J Craniofac Genet Dev Biol Suppl* 1: 267–272.
19. Grummons DC, Kappeyne van de Coppello MA (1987) A frontal asymmetry analysis. *J Clin Orthod* 21: 448-465.
20. Murray JE, Kaban LB, Mulliken JB (1984) Analysis and treatment of hemifacial microsomia. *Plast Reconstr Surg* 74: 186–199.
21. Lauritzen C, Munro IR, Ross RB (1985) Classification and treatment of hemifacial microsomia. *Scand J Plast Reconstr Surg* 19: 33-39.
22. Guyaron B, McMahon J (1981) Foreign-body granuloma following bilateral facial reconstruction with an omental flap. *Plast Reconstr Surg* 81: 771-774.

Copyright: © 2015 Li X, et al. This is an open-access article distributed under the terms of the Creative Commons Attribution License, which permits unrestricted use, distribution, and reproduction in any medium, provided the original author and source are credited.

Citation: Li X, Wang Z, Yang Z, Xu M (2015) A Cephalometric Analysis of Hemifacial Microsomia. *Arch Otolaryngol Rhinol* 1(1): 028-033. DOI: 10.17352/2455-1759.000005