

Thasvir Singh^{1,2*}, Christopher Angel³,
Sepehr Tabrizi⁴, Alyssa Cornall^{4,6}, John
Clement² and Arun Chandu²

¹Oral and Maxillofacial Surgery, the Royal
Melbourne Hospital, Parkville, Victoria 3050,
Australia

²Melbourne Dental School, Faculty of Medicine,
Dentistry and Health Sciences, the University of
Melbourne, Melbourne 3010, Victoria, Australia

³Peter MacCallum Cancer Centre - East Melbourne,
St Andrews Place, East Melbourne 3002, Victoria,
Australia

⁴Regional HPV Laboratory Network, Department
of Microbiology and Infectious Diseases, The Royal
Women's Hospital, Victoria, Australia

⁵Department of Obstetrics and Gynecology,
University of Melbourne, Parkville, Victoria,
Australia

⁶Murdoch Children's Research Institute, Royal
Children's Hospital, Flemington Road Parkville,
Victoria, Australia

Dates: Received: 22 April, 2016; Accepted: 06 May,
2016; Published: 11 May, 2016

*Corresponding author: Thasvir Singh, Oral
and Maxillofacial Surgery Office C/- 2 North, The
Royal Melbourne Hospital, Parkville 3050, Victoria,
Australia, Tel: +61 3 9342 8892; 61402579677; E-mail:
singhtm@xtra.co.nz

www.peertechz.com

ISSN: 2455-1759

Research Article

Ameloblastoma, Human Papillomavirus, and p16- is there An Association?

Abstract

Background: The aetiology of the ameloblastoma is still unclear. Several studies have searched for the presence of human papillomavirus (HPV) in ameloblastomas, however the results have been mixed. Our aim is to clarify this possible association, and to determine if p16 is a reliable surrogate marker for the presence of HPV in these tumours.

Methods: Forty-one cases of ameloblastoma and 1 ameloblastic carcinoma were identified and underwent immunohistochemical (IHC) testing for p16 and polymerase chain reaction (PCR) testing to detect HPV DNA.

Results: 80.5% of the benign ameloblastomas were 'overall positive' for p16 (56.1% strong positive, and 24.4% moderately positive) and 19.5% 'overall negative'. The single case of ameloblastic carcinoma also stained strongly positive for p16. PCR did not detect HPV DNA in any of the 42 cases.

Conclusions: We did not find any positive HPV ameloblastomas within the samples evaluated. Despite most ameloblastomas being p16-positive, p16 cannot be used as a marker of HPV within these tumours.

Introduction

Ameloblastoma is a benign odontogenic tumour with four main subtypes [1], solid/multicystic, unicystic, desmoplastic, and peripheral. In general, most ameloblastomas are locally aggressive, and can grow to a considerable size resulting in significant morbidity, and even mortality [2]. They have a propensity to recur if treated inadequately, and thus radical surgical management is the mainstay of treatment [3-14]. Despite clinicians recognising the entity for over a century, the aetiology of this tumour is still unclear. It is thought to develop from epithelial remnants of the dental lamina/enamel organ, and various theories on causative agents have been proposed in the literature including trauma, dental extraction, severe oral sepsis, and viruses such as the human papillomavirus (HPV) [15-21].

HPV is a DNA virus that has come under renewed scrutiny due to its recently discovered association with oropharyngeal squamous cell carcinoma (OPSCC) [22-24]. HPV-positive OPSCC has an improved prognosis compared with HPV-negative tumours. With further research HPV-positive tumours may result in de-escalated chemoradiotherapy or bioradiotherapy treatment options, in an effort to reduce acute and long-term treatment related toxicities [25-29]. In OPSCC, p16 immunohistochemistry is used as a reliable surrogate marker for HPV infection [29-36].

A possible association between ameloblastoma and HPV has attracted some attention from researchers over the years. HPV may

gain access to intraosseous lesions via contact with the overlying oral mucosa, surgical manipulation of the surrounding structures prior to tumour development, and early onset exposure to the HPV during invagination of the enamel organ. Although sexual contact would be extremely unlikely during the stages of dental development, perinatal or salivary transmission of HPV is possible [37-39]. Contamination of the tumour specimen by HPV either during the respective process, or post-operatively, is also possible. Several case reports and studies have explored this relationship (Table 1), but no firm conclusions have been reached. Use of p16 immunohistochemistry in ameloblastoma has not been thoroughly investigated.

This study aims to establish whether HPV DNA is associated with ameloblastomas, and to determine if p16 is a reliable surrogate marker for the presence of HPV in these tumours.

Table 1: Summary of results from publications involving HPV and Ameloblastoma.

Study	Number of Cases	Method(s) used	HPV-Positive Ameloblastomas
1989 Kahn	10	ABC	3/10 (30%)
1992 Kahn	1*	ISH	1/1 (100%)
1993 van Heerden et al.	1	ISH	1/1 (100%)
2000 Sand et al.	12	PCR	5/12 = (42%)
2003 Namin et al.	50	PCR	20/50 (40%)
2005 Migaldi et al.	18	IHC, ISH, PCR	2/18 (11%) weak positive on PCR only
2010 Correnti et al.	18	IHC, PCR	6/18 (33%) on PCR only

ABC (Avidin-Biotin Immunoperoxidase Complex), ISH (In-Situ Hybridisation), PCR (Polymerase Chain Reaction), IHC (Immunohistochemistry).
* This one case was a peripheral ameloblastoma.
= HPV positive at primary surgery.

Materials and Methods

Ethical approval for this study was granted by The Melbourne Health Human Research Ethics Committee. Forty-nine cases of ameloblastoma were retrieved from The Royal Melbourne Hospital databases over an 11-year period (2001-2012). The histopathological slides and patient case notes were evaluated by an oral and maxillofacial surgical registrar and specialist oral and maxillofacial pathologist. Using the World Health Organization classification system [1], the diagnosis of each was confirmed and subtyped accordingly. Forty-two cases were included in the study, with 7 cases excluded due to insufficient clinical and/or pathological information.

p16 Immunohistochemistry (IHC)

Formalin fixed paraffin embedded (FFPE) tissue of the 42 ameloblastomas were cut into 4µm thick sections and then placed onto Superfrost® Plus Microscope Slides (Thermo Scientific, Lower Saxony, Germany) prior to being tested with p16 antibody (Roche CINtec®, Ventana Medical Systems, Inc, Arizona, USA) at a 1:3 dilution. Sections were dewaxed through a series of xylene solutions (x3) followed by absolute ethanol (x2), 70% ethanol and distilled water. Antigen retrieval was performed using a high pH antigen retrieval solution and IHC staining was performed on the Leica BOND-MAX™ automated IHC stainer (Leica Biosystems, Melbourne, Australia) using Bond™ Polymer Refine Detection system. Negative and positive controls (basaloid squamous cell carcinoma in lymphoid tissue) for were also processed using the same method for each specimen slide.

To grade the tumours for p16 positivity, 10 randomized areas of the tumour were evaluated for the number of positive cells under high magnification (400x) [40-42]. P16 negative cells were also counted in the same areas and a percentage formulated by dividing the number of positive cells by the number of total cells (1000). This percentage was classified at different levels to grade the tumour's positivity (Table 2). To account for any inaccuracy in grading, tumours were also graded as overall negative (<25%) and overall positive (25 – 100%).

Polymerase Chain Reaction (PCR) detection of HPV DNA

The 42 FFPE tissue blocks were cut into three 7µm sections (without hydration) and underwent preparation for PCR. One of the sections from each block was de-waxed with histolene and ethanol, and digested with proteinase K on a heat block overnight [43]. Where sections were resistant to complete tissue digestion, physical disruption of tissue with vortexing and beads were applied. DNA was extracted from digested tissues on an automated system - the MagnaPure LC (R) (Roche Diagnostics GmbH, Penzberg, Germany)

Table 2: Grading of p16-positive cells [40-42].

Percentage of Positive Tumour Cells	Grading
<5%	0 = Negative
5-24%	1 = Weak Positive
25-50%	2 = Moderate Positive
>50%	3 = Strong Positive
<25%	Overall Negative
25 – 100%	Overall Positive

using the DNA-I kit (blood cells high-performance protocol). An 110bp section of the human beta-globin gene was detected by quantitative real-time PCR to confirm successful DNA extraction [44]. Samples were screened for the presence of HPV DNA using the DNA ELISA Kit HPV SPF10, version 1 (Labo Bio-medical Products BV, Rijswijk, The Netherlands) and ELISA-positive samples were further tested for HPV genotype on the RHA kit HPV SPF10-LiPA25, version 1 (Labo Bio-medical Products BV).

Statistical analysis

A database was constructed and Minitab® Statistical Software (Pennsylvania, USA) was used for statistical analysis. Fisher's exact tests were prepared for the PCR results relative to the p16 grading, and statistical significance was determined by $p < 0.05$.

Results

Forty-one cases of benign ameloblastoma were identified and one case of ameloblastic carcinoma (AC). Solid/multicystic ameloblastoma was the most common subtype (34 cases), followed by unicystic ameloblastoma (6 cases), and peripheral ameloblastoma (1 case). There were no established cases of desmoplastic ameloblastoma or metastasizing ameloblastoma. Males (63%) were affected slightly more than females, and the mandible was involved in 80.5% of the cases.

P16 Immunohistochemistry

Of the 41 benign ameloblastomas, 33 (80.5%) were deemed overall positive for p16, including 23 (56.1%) strongly positive (Figure 1), and 10 (24.4%) moderately positive tumours. Only 8 tumours (19.5%) were graded as overall negative for p16, with 2 tumours (4.9%) being totally negative and 6 tumours (14.6%) weakly positive. Thus 95.1% of benign ameloblastomas had some positive reaction to p16 IHC staining, with the majority of these being strong or moderately positive (Figure 2).

The single case of AC (in a 40 year-old female, with 3 episodes of tumour recurrence, managed with multiple surgical procedures and radiotherapy) was strongly positive for p16.

PCR detection of HPV DNA

All 42 lesions (including the PA and AC) were negative for the presence of HPV DNA on PCR testing. All samples were positive for internal control indicating adequate amplifiable DNA present in the samples assessed.

Discussion

High-risk (HR) mucosal HPV genotypes are found associated with precancerous and cancerous mucosal lesions. HPV infects epithelial cells causing changes to the host's genome by a similar mechanism to that of genital cancer (e.g. genital squamous cell carcinoma). Essential to the process of cell cycle deregulation and HPV-induced carcinogenesis is the action of E5, E6, and E7 proteins, which are transcribed from respective genes on viral genome. In HR HPV infected lesions, E7 utilizes several pathways to disrupt the activity of CDK (cyclin-dependent kinase) inhibitors p21 and p27, and destabilize the Rb tumour suppressor protein. This in turn

causes overexpression of p16, another CDK inhibitor, which has been correlated as a surrogate marker for presence of HPV and E7 activity [32].

PCR is a highly sensitive technique for detecting HPV DNA, and it can be utilized with either fresh or FFPE tissue specimens [45,46]. Because of this high sensitivity, PCR may detect HPV from the environment, which can be falsely attributed to the lesion.

IHC uses p16 protein as a surrogate marker for HPV presence in OPSCC, and similarly has a sensitivity close to 95-100% [29-31]. Furthermore IHC has several advantages over PCR including that it is relatively cheap to perform, p16 monoclonal antibodies are readily available in most laboratories [32], and the test can be conducted on FFPE tissue samples using light microscopy. In OPSCC, there is high level of p16-positivity [30,32,33,47,48], but for other head and neck tumours the scoring of P16 positivity is more challenging as an internationally recognized p16 grading system has not been developed for samples from these sites. The “cut-off” for a positive reaction is largely arbitrary with many investigators using cut off points of 25, 50, 70, or 75% of cells testing positive [29,33-36]. Even

those lesions with partial p16 staining (<50%) are shown to harbour HPV RNA [32,47], and thus a minimum cut-off of 50% is thought to be sufficient in determining HPV positivity in most OPSCC cases, with a good correlation shown between incisional biopsy and final tumour specimens [49].

However, some p16 positive OPSCC and oral SCC tumours do not have evidence for the presence of HPV DNA on PCR or ISH (up to 13.9%) [30,50], thus p16 is being expressed by other mechanisms [32,51]. In the absence of HPV infection, p16 normally functions as a CDK inhibitor and G1/S cell cycle phase checkpoint regulator, and thus overexpression may also reflect its increased production during tumourigenesis. Despite 80.5% of the ameloblastomas in our study being overall positive for p16, HPV DNA was not detected via PCR and thus would be considered ‘p16-positive HPV-negative’ tumours. This is consistent with other tumours such as sinonasal undifferentiated carcinomas (SNUC) and subtypes of non-small cell carcinoma of the lung [32,52,53]. Nonetheless, multivariate survival analysis of OPSCC shows that p16 positivity correlates with better survival compared to p16-negative tumours independent of HPV status [29-32,34,36,50]. Thus while p16 may not be a specific marker for HPV infection, it may help in the prognostic stratification of these patients. It is unproven whether the same holds true for ameloblastoma following treatment (e.g. tumour recurrence).

Despite the likely increasing incidence of HPV infection in the community [54], there is a lack of consistent data regarding the virus’s association with odontogenic lesions, including ameloblastoma [1]. In the closest experimental model available, mice inoculated with Polyoma virus developed ameloblastoma-like tumours [19,20].

Furthermore when polyoma virus-infected tooth buds were transplanted into uninfected mice, ameloblastoma developed in close to 40% of the cases compared to 0% of the control cases (uninfected transplanted tooth buds) [20].

Further studies of clinical cases have failed to show a conclusive causal relationship between HPV and ameloblastoma (Table 1). In 1989 Kahn investigated the presence of HPV in 10 ameloblastomas from patients aged 19 years or younger to 10 ameloblastomas from an older (control) group [16]. Three cases of the younger group tested positive for HPV antigen (30%), including 1 peripheral ameloblastoma where the adjacent oral mucosa also tested positive for HPV. In contrast all cases in the control group were negative for HPV. The author raised the possibility of HPV contributing towards the development of ameloblastoma. Kahn also published a case report where HPV was detected in a PA using ISH [55], and was soon followed by van Heerden et al. in 1993 [17], who used the same method to detect HPV-18 DNA in a conventional intraosseous ameloblastoma. HPV DNA was only found in a verrucoid-appearing lesion in a cystic area of the tumour lining and thus it may be possible that the HPV secondarily infected the tumour, rather than acting as a true aetiological agent.

Sand et al. used PCR to detect HPV DNA in 5/12 (42%) ameloblastomas, with genotypes 6, 11 and 18 identified (Table 1). Interestingly most of their recurrent tumours were found to be HPV-

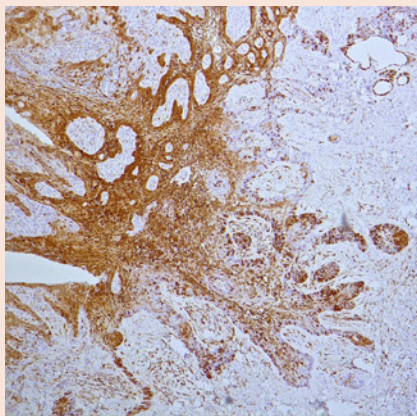


Figure 1: Low power view of a solid/multicystic ameloblastoma that has undergone immunohistochemical staining for p16. This tumour was graded as a strong-positive (>50% of tumour cells positive for stain).

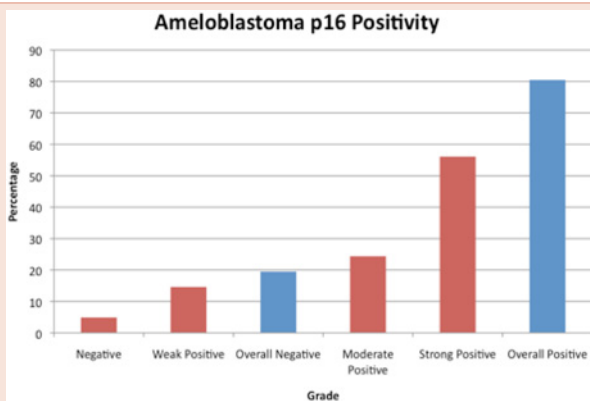


Figure 2: Summary of immunohistochemistry results from 41 benign ameloblastomas stained for p16.

positive on their second surgery but not after their initial surgery, and thus surgical manipulation may have had an influence on these results [56]. Namin et al., compared 50 ameloblastomas to 50 matched tooth follicles via PCR and found a statistically significant difference (40% and 9% respectively, $p < 0.025$) between the 2 groups [57], however there no high risk types were identified.

More recently Correnti et al., compared 18 intraosseous ameloblastomas to 10 normal oral mucosal sites (controls) using a variety of techniques including IHC and nested-PCR [15]. Although IHC did not reveal HPV in any of the ameloblastoma samples, PCR revealed 6/18 (33%) of cases positive with HPV, with HPV Type 6 the most commonly found (66%). None of the positive cases were related to recurrence of the tumour, and all controls were negative for HPV. Four of the 6 positive cases were UA (66.7%) and thus raises the possibility of HPV proliferation in the cyst lining (e.g. dentigerous cyst).

Migaldi et al. did not identify any HPV DNA in 18 ameloblastomas using a variety of techniques including IHC, ISH, and conventional PCR [58]. Laser capture microdissection and nested PCR methods were also used, with the advantage of reducing the chances of contamination from the adjacent oral mucosa by using microscopic identification of a specific cell population (ameloblastoma tumour cells). Two cases of the 18 ameloblastomas showed weak positive findings but genotyping did not reveal HPV 16 or 18 (high risk types). Since their techniques markedly reduced the risk of contamination compared to other studies, their results can be seen as being more reliable than other studies. Like Migaldi et al., our results also do not support an association between HPV and ameloblastoma.

In conclusion, although the vast majority of ameloblastomas in our study were positive for p16 using IHC, they were negative for HPV DNA, therefore p16 cannot be used as a surrogate marker for HPV in ameloblastoma. Interpreting the results and methods used by other studies in the literature, it appears contamination, surgical manipulation, or secondary infections are more likely reasons for any positive results rather than true infection by HPV. The significance of overexpression of p16 in ameloblastoma tumourigenesis is uncertain.

Acknowledgements

The authors declare that there is no conflict of interest, would like to acknowledge the Australia and New Zealand Association of Oral and Maxillofacial Surgeons (ANZAOMS) Research and Education Foundation Inc. and Trust for their research grant. The authors also acknowledge the contribution of A/Prof Nastri, A/Prof Wiesenfeld, and Wim H. Quint.

References

- Gardner D, Heikinheimo K, Shear M, Philipsen H, Coleman H (2005) Ameloblastoma. In: World Health Organization Classification of Tumours: Pathology and Genetics of Head and Neck Tumours. Lyon, France: International Agency for Research on Cancer.
- Nastri AL, Wiesenfeld D, Radden BG, Eveson J, Scully C (1995) Maxillary ameloblastoma: a retrospective study of 13 cases. *Br J Oral Maxillofac Surg* 33: 28-32.
- Carlson ER, Marx RE (2006) The ameloblastoma: primary, curative surgical management. *J Oral Maxillofac Surg* 64: 484-494.
- Sachs SA (2006) Surgical excision with peripheral ostectomy: A definitive, yet conservative, approach to the surgical management of ameloblastoma. *J Oral Maxillofac Surg* 64: 476-483.
- Pogrel MA, Montes DM (2009) Is there a role for enucleation in the management of ameloblastoma? *Int J Oral Maxillofac Surg* 38: 807-812.
- Siar CH, Lau SH, Ng KH (2012) Ameloblastoma of the jaws: a retrospective analysis of 340 cases in a Malaysian population. *J Oral Maxillofac Surg* 70: 608-615.
- Bianchi B, Ferri A, Ferrari S, Leporati M, Copelli C, et al. (2013) Mandibular resection and reconstruction in the management of extensive ameloblastoma. *J Oral Maxillofac Surg* 71: 528-537.
- França LJ, Curioni OA, Paiva DL, Vianna DM, Dedivitis RA, et al. (2012) Ameloblastoma demographic, clinical and treatment study - analysis of 40 cases. *Braz J Otorhinolaryngol* 78: 38-41.
- Eckardt AM, Kokemuller H, Flemming P, Schultze A (2009) Recurrent ameloblastoma following osseous reconstruction—a review of twenty years. *J Craniomaxillofac Surg* 37: 36-41.
- Nakamura N, Higuchi Y, Mitsuyasu T, Sandra F, Ohishi M (2002) Comparison of longterm results between different approaches to ameloblastoma. *Oral Surg Oral Med Oral Pathol Oral Radiol Endod* 93: 13-20.
- Li Y, Han B, Li LJ (2004) Prognostic and proliferative evaluation of ameloblastoma based on radiographic boundary. *Int J Oral Sci* 4: 30-33.
- Hertog D, Bloemena E, Aartman IHA, van der Waal I (2012) Histopathology of ameloblastoma of the jaws; some critical observations based on a 40 years single institution experience. *Med Oral Patol Oral Cir Bucal* 17: e76-e82.
- Chaine A, Pitak-Arnnop P, Dhanuthai K, Ruhin-Poncet B, Bertrand JC, et al. (2009) A treatment algorithm for managing giant mandibular ameloblastoma: 5-year experiences in a Paris university hospital. *Eur J Surg Oncol* 35: 999-1005.
- Chana JS, Chang YM, Wei FC, Shen YF, Chan CP, et al. (2004) Segmental mandibulectomy and immediate free fibula osteoseptocutaneous flap reconstruction with endosteal implants: an ideal treatment method for mandibular ameloblastoma. *Plast Reconstr Surg* 113: 80-87.
- Correnti M, Rossi M, Avila M, Perrone M, Rivera H (2010) Human papillomavirus in ameloblastoma. *Oral Surg Oral Med Oral Pathol Oral Radiol Endod* 110: e20-24.
- Kahn MA (1989) wAmeloblastoma in young persons: A clinicopathologic analysis and etiologic investigation. *Oral Surg Oral Med Oral Pathol* 67: 706-715.
- van Heerden WFP vRE, Raubenheimer EJ, Venter EH (1993) Detection of human papillomavirus DNA in an ameloblastoma using the in situ hybridization technique. *J Oral Pathol Med* 22: 109-112.
- Forsberg A (1954) A contribution to the knowledge of the histology, histogenesis, and etiology of adamantinoma. *Acta Odontol Scand* 12: 39-64.
- Stanley HR, Dawe CJ, Law LW (1964) Oral Tumors Induced by Polyoma Virus in Mice. *Oral Surg Oral Med Oral Pathol* 17: 547-558.
- Main JH, Dawe CJ (1966) Tumor induction in transplanted tooth buds infected with polyoma virus. *J Natl Cancer Inst* 36: 1121-1136.
- Fleming HS (1963) Se Polyoma-Virus Tumor and the Teeth. *J Dent Res* 42: 1405-1415.
- Gillison ML, Koch WM, Capone RB, Spafford M, Westra WH, et al. (2000) Evidence for a causal association between human papillomavirus and a subset of head and neck cancers. *Journal of National Cancer Institute* 92: 709-720.
- Lewis JS Jr. (2012) Introduction: Human papillomavirus in head and neck cancer: an update for 2012 with a focus on controversial topics. *Head Neck Pathol* 6: S1-2.

24. Kreimer A, Clifford G, Boyle P, Franceschi S (2005) Human papillomavirus types in head and neck squamous cell carcinomas worldwide: a systematic review. *Cancer Epidemiol Biomarkers Prev* 14: 467-475.
25. Chaturvedi AK (2012) Epidemiology and clinical aspects of HPV in head and neck cancers. *Head Neck Pathol* 6: S16-24.
26. Ragin CC, Taioli E (2007) Survival of squamous cell carcinoma of the head and neck in relation to human papillomavirus infection: review and meta-analysis. *Int J Cancer* 121: 1813-1820.
27. Ang K, Sturgis E (2012) Human papillomavirus as a marker of the natural history and response to therapy of head and neck squamous cell carcinoma. *Semin Radiat Oncol* 22: 128-142.
28. Hafkam H, Manni J, Haesevoets A, Voogd A, Schepers M, et al. (2008) Marked differences in survival rate between smokers and nonsmokers with HPV 16-associated tonsillar carcinomas. *Int J Cancer* 122: 2656-2664.
29. Ang KK, Harris J, Wheeler R, Weber R, Rosenthal DI, et al. (2010) Human papillomavirus and survival of patients with oropharyngeal cancer. *N Engl J Med* 363: 24-35.
30. Lewis JS Jr., Thorstad WL, Chernock RD, Haughey BH, Yip JH, et al. (2010) p16 positive oropharyngeal squamous cell carcinoma: an entity with a favourable prognosis regardless of tumor HPV status. *Am J Surg Pathol* 34: 1088-1096.
31. Ukpo OC, Flanagan JJ, Ma XJ, Luo Y, Thorstad WL, et al. (2011) High-risk human papillomavirus E6/E7 mRNA detection by a novel in situ hybridization assay strongly correlates with p16 expression and patient outcomes in oropharyngeal squamous cell carcinoma. *Am J Surg Pathol* 35: 1343-1350.
32. Lewis JS Jr. (2012) p16 Immunohistochemistry as a standalone test for risk stratification in oropharyngeal squamous cell carcinoma. *Head Neck Pathol* 6: S75-82.
33. Reimers N, Kasper HU, Weissenborn SJ, Stutzer H, Preuss SF, et al. (2007) Combined analysis of HPV-DNA, p16 and EGFR expression to predict prognosis in oropharyngeal cancer. *Int J Cancer* 120: 1731-1738.
34. Shi W, Kato H, Perez-Ordóñez B, Pintilie M, Huang S, et al. (2009) Comparative prognostic value of HPV16 E6 mRNA compared with in situ hybridization for human oropharyngeal squamous carcinoma. *J Clin Oncol* 27: 6213-6221.
35. Singhi AD, Westra WH (2010) Comparison of human papillomavirus in situ hybridization and p16 immunohistochemistry in the detection of human papillomavirus-associated head and neck cancer based on a prospective clinical experience. *Cancer* 116: 2166-2173.
36. Rischin D, Young RJ, Fisher R, Fox SB, Le QT, et al. (2010) Prognostic significance of p16INK4A and human papillomavirus in patients with oropharyngeal cancer treated on TROG 02.02 phase III trial. *J Clin Oncol* 28: 4142-4148.
37. Merckx M, Liesbeth WV, Arbyn M, Meys J, Weyers S, et al. (2013) Transmission of carcinogenic human papillomavirus types from mother to child: a meta-analysis of published studies. *Eur J Cancer Prev* 22: 277-285.
38. Rombaldi RL, Serafini EP, Mandelli J, Zimmermann E, Losquiavo KP (2009) Perinatal transmission of human papillomavirus DNA. *Virology* 6: 83.
39. D'Souza G, Agrawal Y, Halpern J, Bodison S, Gillison ML (2009) Oral sexual behaviors associated with prevalent oral human papillomavirus infection. *J Infect Dis* 199: 1263-1269.
40. Artese L, Lessi G, Piattelli A, Rubini C, Goteri G, et al. (2008) p16 Expression in Odontogenic Cysts. *Dent Res J* 5: 61-64.
41. Artese L, Piattelli A, Rubini C, Goteri G, Pernotti V, et al. (2008) p16 Expression and Odontogenic Tumours. *Tumori* 94: 718-723.
42. Mendelsohn AH, Lai CK, Shintaku IP, Elashoff DA, Dubinett SM, et al. (2010) Histopathologic findings of HPV and p16 positive HNSCC. *Laryngoscope* 120: 1788-1794.
43. Tan SE, Garland SM, Rumbold AR, Tabrizi SN (2010) Human papillomavirus genotyping using archival vulval dysplastic or neoplastic biopsy tissues: comparison between the INNO-LiPA and linear array assays. *J Clin Microbiol* 48: 1458-1460.
44. Cornall AM, Roberts JM, Garland SM, Hillman RJ, Grulich AE, et al. (2013) Anal and perianal squamous carcinomas and high-grade intraepithelial lesions exclusively associated with "low-risk" HPV genotypes 6 and 11. *Int J Cancer* 133: 2253-2258.
45. Nuovo G (2011) In situ detection of human papillomavirus DNA after PCR amplification. *Methods Mol Biol* 688: 35-46.
46. Venuti A, Paolini F (2012) HPV detection methods in head and neck cancer. *Head Neck Pathol* 6: S63-74.
47. Lewis JS Jr., Chernock RD, Ma XJ, Flanagan JJ, Luo Y, et al. (2012) Partial p16 staining in oropharyngeal squamous cell carcinoma: extent and pattern correlate with human papillomavirus RNA status. *Mod Pathol* 25: 1212-1220.
48. Kong C, Narasimhan B, Cao H, Kwok S, Erickson J, et al. (2009) The relationship between human papillomavirus status and other molecular prognostic markers in head and neck squamous cell carcinomas. *Int J Radiat Oncol Biol Phys* 74: 553-561.
49. Ma C, Lewis J Jr. (2012) Small biopsy specimens reliably indicate p16 expression status of oropharyngeal squamous cell carcinoma. *Head Neck Pathol* 6: 208-215.
50. Harris SL, Thorne LB, Seaman WT, Hayes DN, Couch ME, et al. (2011) Association of p16(INK4a) overexpression with improved outcomes in young patients with squamous cell cancers of the oral tongue. *Head Neck* 33: 1622-1627.
51. Perrone F, Ghoghini A, Cortelazzi B, Bossi P, Licitra L, et al. (2011) Isolating p16-positive/HPV-negative oropharyngeal cancer: an effort worth making. *Am J Surg Pathol* 35: 774-777.
52. Tong J, Sun X, Cheng H, Zhao D, Ma J, et al. (2011) Expression of p16 in nonsmall cell lung cancer and its prognostic significance: a meta-analysis of published literatures. *Lung Cancer* 74: 155-163.
53. Wadsworth B, Bumpous J, Martin A, Nowacki M, Jenson A, et al. (2011) Expression of p16 in sinonasal undifferentiated carcinoma (SNUC) without associated human papillomavirus (HPV). *Head Neck Pathol* 5: 349-354.
54. Näsman A, Attner P, Hammarstedt L, Du J, Eriksson M, et al. (2009) Incidence of human papillomavirus (HPV) positive tonsillar carcinoma in Stockholm, Sweden: an epidemic of viral-induced carcinoma? *Int J Cancer* 125: 362-366.
55. Kahn MA (1992) Demonstration of Human Papillomavirus DNA in a peripheral ameloblastoma by in situ hybridisation. *Hum Pathol* 23: 186-191.
56. Sand L, Jalouli J, Larsson PA, Magnusson B, Hirsch JM (2000) Presence of human papilloma viruses in intraosseous ameloblastoma. *J Oral Maxillofac Surg* 58: 1129-1134.
57. Namin AK, Azad TM, Eslami B, Sarkarat F, Shahrokhi M, et al. (2003) A study of the relationship between ameloblastoma and human papilloma virus. *J Oral Maxillofac Surg* 61: 467-470.
58. Migaldi M, Pecorari M, Rossi G, Maiorana A, Bettelli S, et al. (2005) Does HPV play a role in the etiopathogenesis of ameloblastoma? An immunohistochemical, in situ hybridization and polymerase chain reaction study of 18 cases using laser capture microdissection. *Mod Pathol* 18: 283-289.

Copyright: © 2016 Singh T, et al. This is an open-access article distributed under the terms of the Creative Commons Attribution License, which permits unrestricted use, distribution, and reproduction in any medium, provided the original author and source are credited.

Citation: Singh T, Angel C, Tabrizi S, Cornall A, Clement J, et al. (2016) Ameloblastoma, Human Papillomavirus, and p16-is there An Association?. *Arch Otolaryngol Rhinol* 2(1): 020-024. DOI: 10.17352/2455-1759.000016