

A Zidane<sup>1\*</sup>, A Aarsalane<sup>1</sup>, A Elktaibi<sup>2</sup> and I Gharassi<sup>2</sup>

<sup>1</sup>Department of Thoracic Surgery, Military hospital Avicenne, Faculty of medicine and pharmacy Mohamed VI. Cady Ayyad University, Morocco  
<sup>2</sup>Department of Pathological anatomy, Military hospital Avicenne, Faculty of medicine and pharmacy Mohamed VI. Cady Ayyad University, Morocco

**Dates:** Received: 05 January, 2016; Accepted: 04 March, 2016; Published: 07 March, 2016

**\*Corresponding author:** Dr, Abdelfettah Zidane, Department of Thoracic Surgery, Military Hospital Avicenne, PB 40000, Marrakech. Morocco, Tel: 0 (212) 650 218 592; E-mail: zidaneaf@yahoo.fr

[www.peertechz.com](http://www.peertechz.com)

**Keywords:** Pulmonary blastoma; Lung tumor; Pathology

## Case Report

# Classical Biphasic Pulmonary Blastoma: A Case Report

### Abstract

Pulmonary blastomas are a rare aggressive neoplasms comprising 0.25-0.5% of all primary lung tumors and portend a poor prognosis. Recent World Health Organisation (WHO) reclassifications separated well differentiated fetal adenocarcinoma and pleuropulmonary blastoma from classic biphasic pulmonary blastoma which is now among carcinomas with pleomorphic, sarcomatoid or sarcomatous elements. The clinical and radiologic features are nonspecific. Surgery is the standard treatment and the efficacy of adjuvant chemotherapy and radiotherapy has not yet been established. We present a case of classic biphasic pulmonary blastoma in a 52-year old male and review the literature.

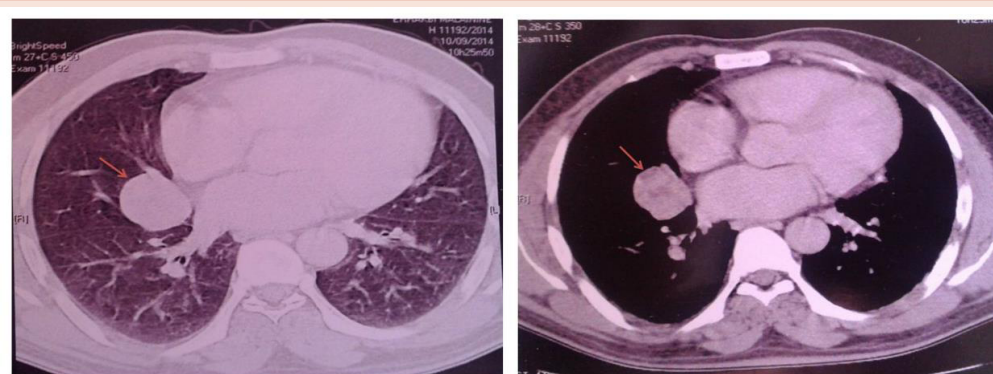
## Introduction

Pulmonary blastomas are a rare aggressive neoplasms comprising 0.25-0.5% of all primary lung tumors. They display a biphasic histology with mesenchymal and epithelial components whose features mimic embryological lung tissues before 4 months gestation. Since the first report by Barrett & Barnard [1], in 1945, over a hundred cases of pulmonary blastoma are reported in the literature. They are currently subdivided in three categories: well differentiated fetal adenocarcinoma, pleuropulmonary blastoma and classic biphasic pulmonary blastoma (CBPB). Surgery is the standard treatment and the efficacy of adjuvant chemotherapy and radiotherapy has not yet been established. We present a new case of this rare lung cancer.

## Observation

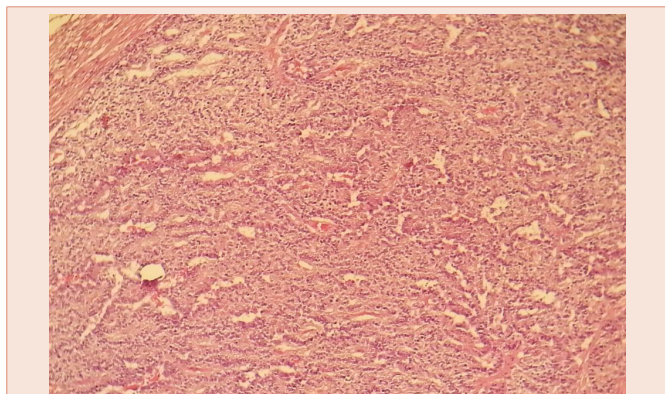
A 52-year-old man presented to the outpatient department with right chest pain of 3 months duration. He denied hemoptysis, dyspnea, fever or weight loss. His past medical history was significant

for left pleural tuberculosis treated in 1988. On examination he looked well, had no clubbing. Baseline investigations were done, which included complete blood count, renal function tests, and liver function tests; all were within the normal range. Chest X-ray showed a well-demarcated mass projected over the right hilum. A subsequent chest computed tomography scan with intra-venous contrast (Figures 1,2) confirmed a well-defined 3.8 × 2.5 cm mass arising from the medial segment of the middle lobe. It demonstrated heterogeneous contrast enhancement with few necrotic foci. The mass abutted the mediastinal pleura with no sign of invasion of left atrium. There was no evidence of lymphadenopathy. The liver and adrenal glands appeared normal. CT guided biopsy was done and the smear revealed a biphasic neoplasm composed of epithelial and mesenchymal components suggestive of pulmonary blastoma. CT abdomen and bone scintigraphy showed no evidence of distant metastasis. The patient underwent a middle lobectomy with hilar and mediastinal lymph node dissection. The histopathology of the specimen confirmed the diagnosis of pulmonary blastoma without involvement of the lymph nodes. Post-operative course was uneventful and the patient was discharged on the 4th postoperative day. Due to the lack of certain poor prognostic factors like tumor size



**Figure 1:** CT scan showing a well-defined 3.8 × 2.5 cm mass arising from the medial segment of the middle lobe with heterogeneous contrast enhancement and few necrotic foci.

A) Axial chest CT in pulmonary window; B) Axial chest CT in mediastinal window.



**Figure 2:** Photomicrography showing a microscopic appearance of the mass with fetal-type glandular structures mixed with primitive blastematosus stroma (Hematoxylin and Eosin × 250).

more than 5 cm and involvement of mediastinal lymph nodes, it was decided to keep patient under observation. There was no evidence of recurrence or distant metastasis in one year of follow up.

## Discussion

Pulmonary blastoma comprises only 0.25–0.5% of malignant lung neoplasms. This tumor was first recognized by Barrett and Barnard [1], in 1945 and was termed embryoma of the lung due to its histologic similarity to fetal lung tissue. Historically, the term pulmonary blastoma had included both pure fetal adenocarcinomas, pleuropulmonary blastomas as well as the classic biphasic blastomas. However recent World Health Organization (WHO) reclassifications, separated well differentiated fetal adenocarcinoma which consists only of an epithelial component and is categorized as a variant of adenocarcinoma of the lung and pleuropulmonary blastoma of childhood which consists only of mesenchymal cells, from CBPB which is characterized by a histological heterogeneity of mixed epithelial and mesenchymal malignancies and is now among carcinomas with pleomorphic, sarcomatoid or sarcomatous elements. Classical pulmonary blastoma is the most common of these three subtypes [2,3].

In CBPB, the average age at diagnosis is 40 years with an increased frequency in males. 82% of them have a history of tobacco use [4]. They frequently appear as large tumors. So, the majority of these patients are symptomatic. Cough, chest pain, haemoptysis, dyspnea and respiratory distress are common presenting features.

Pulmonary blastoma usually presents as a well-defined lesion on the chest radiography. The majority of the lesions are large (ranging from 2.5 to 25 cm), solitary, peripheral mass. Only 25% exhibits endobronchial Growth. On CT, pulmonary blastoma is seen as a mixed solid and cystic lesion with variable contrast enhancement and a necrotic centre. The tumor is usually limited to one lung, with all pulmonary lobes equally affected [5]. In their series, Van Loo et al. [6], found an upper lobe predominance, with 27 tumors located in the upper lobes, while 19 tumors were located in the lower lobes and 1 in the middle lobe. The role of PET-CT in the radiological staging of pulmonary blastoma is still unknown.

Although establishing a preoperative diagnosis of pulmonary blastoma by examining histologic or cytologic specimen is difficult due to the challenging nature of the histology, the possibility of pulmonary blastoma should be considered when a two-cell pattern consisting of both epithelial and mesenchymal components is observed. A preoperative diagnosis is only obtained in one third of cases.

The histogenesis of CBPB is still under discussion. Some authors proposed an endodermal or mesenchymal origin, while others suggested that both components are derived from a single pluripotential cell [7]. Microscopically, the tumor is a biphasic neoplasm with a mixture of malignant epithelial and stromal cells. The malignant epithelial component resembles well-differentiated fetal adenocarcinoma with primitive tubular glands that mimic fetal bronchioles and the stroma consists of loose undifferentiated mesenchyme and may have variable degrees of nuclear atypia. Epithelial component is strongly keratin and TTF-1 positive whereas stromal component is negative for both keratin and TTF-1.

Surgical resection is the mainstay of treatment for localized disease. Koss et al. [8], reported a mean survival of 33 months in 66 resected cases compared to 2 months in 17 patients with unresected disease. Liman et al. [9], reported that resection of small tumors which do not have any lymph node involvement can provide better survival without any additional treatment. Limited resections do better than pneumonectomies, but wedge resection should be avoided. Unfortunately, 43% of tumors recur within 1 year with a propensity for sites such as brain and Mediastinum [8]. Recurrence tends to occur within 1 year after diagnosis or not at all [9].

Radiation therapy given as a single therapy has induced an objective response in a few case reports. So, in most centers, it's used to treat irresistible cases that do not respond to other forms of treatment [10].

The vague role of chemotherapy in the adjuvant setting is probably due to rarity of this malignancy and seems to be individualized in reported cases. Various combinations of chemotherapeutic drugs have been tried as neoadjuvant and adjuvant treatment. However, several case reports document the use of platinum-based adjuvant treatment [11,12].

Overall survival is 25% at 1 year, 16% at 5 years and only 8% survive 10 years. In one survey of 83 cases, the mean survival of approximately 33 months was reported for the patients who underwent surgery and achieved negative margins [13]. The factors contributing to the unfavorable prognosis are the biphasic type, tumor recurrence, metastatic disease on presentation, tumor size over 5 cm, and frequent lymph node involvement [14]. In our case, due to the lack of certain poor prognostic factors like tumor size more than 5 cm and involvement of mediastinal lymph nodes, it was decided to keep patient under observation and there was no evidence of recurrence or distant metastasis in one year of follow up.

## Conclusion

A classic biphasic pulmonary blastoma is a rare malignant lung neoplasms with a poor prognosis. Despite its rarity and lack



of radiological specificity, it must be part of diagnostics to evoke in cases of solitary pulmonary mass. No therapeutic guidelines exist. To date, surgical excision is the treatment of choice whenever possible. The role of adjuvant treatment is still debated; this case suggests a wait-and-watch approach when resection is complete without adverse prognostic factors. The recurrence rate is high; therefore a careful follow-up is required. However, a large series of case studies is required to improve our understanding of this rare lung cancer.

## References

1. Barnard WG (1952) Embryoma of lungs. *Thorax* 7: 299–301.
2. Koss M, Travis W, Moran C (1996) Pulmonary sarcomas, blastomas, carcinosarcomas and teratomas. *Spencer's histopathology of the lung*. 5th ed. New York, NY: McGraw Hill 1092-1100.
3. Mistry JH, Pawar SB, Mehta H, Popov AF, Mohite PN (2013) Primary pulmonary blastoma of monophasic variety: diagnosis and management. *J Cardiothorac Surg* 8:144.
4. Larsen H, Sorensen JB (1996) Pulmonary blastoma: a review with special emphasis on prognosis and treatment. *Cancer Treat Rev* 22: 145–160.
5. Robert J, Pache JC, Seium Y, de Perrot M, Spiliopoulos A (2002) Pulmonary blastoma: report of five cases and identification of clinical features suggestive of the disease. *Eur J Cardiothorac Surg* 22: 708–711.
6. Van Loo S, Boeykens E, Stappaerts I, Rutsaert R (2011) Classic biphasic pulmonary blastoma: A case report and review of the literature. *Lung Cancer* 73: 127-132.
7. Bodner SM, Koss MN (1996) Mutations in the p53 gene in pulmonary blastomas: immunohistochemical and molecular studies. *Hum Pathol* 27: 1117–1123.
8. Koss MN, Hochholzer L, O'Leary T (1991) Pulmonary blastomas. *Cancer* 67: 2368–2381.
9. Liman ST, Altinok T, Topcu S, Tastede AI, Uzar A, et al. (2006) Survival of biphasic pulmonary blastoma. *Respir Med* 100: 1174–1179.
10. Surmont VF, van Klaveren RJ, Nowak PJ, Zondervan PE, Hoogsteden HC, et al. (2002) Unexpected response of a pulmonary blastoma on radiotherapy: a case report and review of the literature. *Lung Cancer* 36: 207–211.
11. Robert J, Pache JC, Seium Y, De Perrot MA (2002) A Spiliopoulos, Pulmonary blastoma: report of five cases and identification of clinical features suggestive of the disease. *Eur J Cardiothor Surg* 22: 708-711.
12. Walker RI, Suvama K, Matthews S (2005) Pulmonary blastoma: presentation of two atypical cases and review of the literature. *British J Radiol* 78: 437-440.
13. Adluri RKP, Boddu SR, Martin-Ucar A, Duffy JP, Beggs FD, (2006) Pulmonary blastoma: a rare tumor with variable presentation. *Eur J Cardiothor Surg* 29: 236-239.
14. Cutler CS, Michel RP, Yassa M, Langleben A (1998) Pulmonary blastoma: case report of a patient with a 7-year remission and review of chemotherapy experience in the world literature. *Cancer* 82: 462-467.

**Copyright:** © 2016 Zidane et al. This is an open-access article distributed under the terms of the Creative Commons Attribution License, which permits unrestricted use, distribution, and reproduction in any medium, provided the original author and source are credited.

**Citation:** Zidane A, Arsalane A, Elktaibi A, Gharassi I (2016) Classical Biphasic Pulmonary Blastoma: A Case Report. *Arch Pulmonol Respir Care* 2(1): 007-009. DOI: <http://dx.doi.org/10.17352/aprc.000008>