

Andrea Cavallaro¹, Giorgio Maria Paolo Graziano², Marco Cavallaro³ and Antonino Graziano^{4*}

¹Surgical and Breast Unit Azienda Policlinico Ct, Italy

²University of Catania, Medical School, Italy

³Radiology unit ASP Ragusa, Italy

⁴Aggregate Professor, University of Catania Azienda Policlinico Dpt Sciences Surgery and advanced technologies "G Ingrassia", via S Sofia 86, Catania. Cap 95125, Italy

Dates: Received: 18 September, 2015; Accepted: 13 October, 2015; Published: 15 October, 2015

***Corresponding author:** Prof. Antonino Graziano, Aggregate Professor, University of Catania Azienda Policlinico Dpt Sciences Surgery and advanced technologies "G Ingrassia", via S Sofia 86, Catania. Cap 95125, Italy, Email: graziano@policlinico.unict.it

www.peertechz.com

ISSN: 2454-2968

Keywords: Stent; Intestinal occlusion

Research Article

The Stent Evolution in Colo-Rectal Emergencies

Summary

Introduction: The appearance of a framework for occlusive colorectal tumor raises complex issues and difficult. We need to ensure a resumption of normal bowel function in patients often in extreme conditions. Emergency surgery flounders in a derivation and a resection with restoration of intestinal transit. The progress of digestive endoscopy can now make available a medical procedure can solve the framework occlusive both as palliation both as a bridge to safer surgery. The purpose of this study is to evaluate the indications and limitations of the method of colon prosthesis with self-expandable stents.

Materials and methods: From 1996 to 2004 at the surgical clinic III - University Policlinic of Catania - were performed 162 interventions for colorectal pathology of which 82 for benign disease and the remaining 80 for malignant disease. In four of these cases of neoplastic occlusions (one in which the precarious clinical condition and high anesthetic risk high - ASA 5 - in a metastatic patient made problematic the surgical indication and 3 in which the significant intestinal distension induced to believe priority prosthetic re-canalization) recovery of bowel function was made possible with an attachment of metal self-expandable prosthesis. These 4 patients were compared with the same number of patients in overlapping conditions in which the re-channeling has been obtained by surgical methods in emergency. This has highlighted, despite its low numbers, at least a trend of lower risk in favor of the prosthesis, while recognizing that the endoscopic procedure involves a considerable wealth of complications. It emphasizes collaboration, critical, of course, with the endoscopist, even with the radiologist who, in addition to laying the groundwork for the definition of indications, is directly implicated in the satisfactory development of the procedure during and after his implementation.

Conclusions: In patients with blocking colorectal tumor is feasible to implement an attempt endoscopic decompression useful to the recovery of the intestinal canalization.

Introduction

The appearance of a framework for occlusive colorectal tumor raises the issue of how the therapy should be accurate and timely, and its goal is to rebalance the overall clinical condition of the patient, and to restore the re-canalization of bowel function with a therapeutic approach in relation to the specific clinical situation. The occluded patient is usually admitted to a department of emergency surgery and underwent surgical treatment in relation to the anatomical and clinical situation occurring. This intervention may be a derivation and/or a resection and whether or not followed by the restoration of intestinal continuity. The choice is obviously complex and difficult in emergency. For this reason, *initially*, the positioning of self-expandable metal prostheses has emerged as a possible palliative treatment in emergency-urgency [1-3], utilized for the solution of the framework of extreme acute occlusion, in patients in severe general conditions with extensive neoplasm disease. Initially, therefore, the prosthesis was placed in alternative to emergency surgery that is burdened with rates of mortality and morbidity, significantly higher than those in elective colorectal surgery. In fact, palliation with prosthesis provides results comparable to those of emergency surgery but at lower risk (halved) compared to decompressed colostomy, the ileo-colic derivation or Hartman procedure [9,11]. In patients not amenable to curative resection [7,8] or deemed too risky for causes of local and general disorders, the indications in the palliative treatment of malignant strictures of the colon and rectum, are determined

primarily by the occlusion of a tumor locally advanced or with distant metastases, or from a patient with clinical conditions so complex that make the operative risk unacceptable. But beyond these cases, it soon became apparent that, even in patients not extreme, the affixing of a prosthesis can be used to ensure normal bowel function before surgery, and therefore to obtain an optimal rehydration of the patient, a reduction gas expansion of the bowel, with improved intestinal trophism loops upstream and lower risk for the anastomosis. That affixing can make the indicated treatment in one time of the occlusive status. In these cases, therefore, the prosthesis of acute occlusion can be a procedure able to move the patient to a virtually elective surgical procedure, This represent a bridge to surgery, without a doubt the best procedure in every sense (bridge to surgery) [14], The purpose of this study is to evaluate the indications and limitations of this method on the basis of a comparison of the endoscopic procedure and emergency surgery. *This, despite numbers too small, certainly not useful for statistical evaluation, however, can indicate an operative trend and gives an idea of the possibilities of the endoscopic technique.*

Materials and Methods

From 1996 to 2004 at the surgical clinic III - University Policlinic of Catania were treated 162 interventions for colorectal pathology moving from the emergency room. Of these cases, 82 were benign diseases (diverticulitis, volvulus, and intussusception), the remaining 80 were cancer diseases. Given their provenance of urgency, in 75

cases the patients presenting with a severe bowel obstruction for which it was necessary to adopt an emergency procedure. In 3 cases was present sigmoid volvulus with septic shock, n 2 necrosis and bowel perforation for femoral strangled hernia and peritonitis. These cases, suffering with the intestinal wall, were all surgically treated in emergency. In 4 of the 75 cases occluded by cancer occurred to our observation, we have tried alternative routes to emergency surgery in the period 2002/04. In the first case we have adopted the procedure of palliative endoscopic placement of a self-expandable stent for cancer of the rectum-sigma locally advanced in a very elderly patient in poor general condition with pulmonary repetitions. The patient lived a couple of months, but fully ducted. The success of the procedure, has led us to extend the indications of the use of stents to patients not in poor general condition, in that mode which has since been called "bridge to surgery". Three other patients had indeed placed the stent and, after an average of 16 days, underwent definitive surgical treatment in channeling state, with a chance to make preoperative bowel cleaning. The clinical postoperative evolution of these patients was a subclinical dehiscence in case 3 and a burrowing led by drainage in case 1, both healed without major problems. Uneventful the case 2. These patients were all treated in the early 2000. *After we have not got to continue the procedure for both the endoscopist transfer to another hospital and hints for both negative the Dutch experience that was maturing.* We now, years later, given the renewed interest in the procedure, compare our 4 patients with prostheses with as many cases of our series emergency surgery, stratified by age, sex, site of occlusion and comorbidity similar the previous, but not undergoing "re-canalization" stents, and treated in emergency with surgical resection / anastomosis and ileostomy. While, as mentioned, in re-canalized endoscopic bridge were only a postoperative subclinical dehiscence and a fistula, both healed without special measures, in historians patients instead there were two important clinical dehiscence that required the first a) repackaging of the anastomosis and the positioning of multiple drainages, the other b) an intervention of Hartman, after disassembly of the anastomosis, and then a double stoma and both a third intervention to restore intestinal continuity. In 4 cases underwent stent only in the first case (palliation) the clinical condition at admission were precarious and high anesthetic risk (ASA 5) while the occlusion was caused by metastatic tumor. The other three were in better clinical conditions, such as to consider feasible the adoption of the stent as a bridge to surgery. In all cases the re-canalization, both palliative both preoperative, of bowel function was made possible by affixing of a self-expandable metallic prosthesis (Figure 1). The devices used for localized stenosis in the left colon, for anatomical reasons, were of the Evolution type. Today the covered stents are also available, perhaps more suitable for palliative action, while for the short period of the bridge to surgery, open stents that pass in the working channel of the endoscope (TTS), are still eligible.

In Figures are shown the prosthesis (Figure 1) the direct [2] radiology, the endoscopic aspect (Figure 4).

The diagnostic study of the patient occluded is obtained by performing a CT scan (Figure 3) to evaluate the location, extent and nature of the stenosis, the state of the intestinal wall, the amount of air-fluid levels in order to have an overall picture of the situation (to exclude a bowel perforation, a suffering loop, a closed-loop dilatation).

It should also assess the extent of the disease for the objective palliative or bridge to surgery of the procedure [13,14]. The indication for stent placement is decided after specialists consultation (surgeon, radiologist, endoscopist and anesthesiologist). The onset of occlusive symptoms, their severity and gas dilatation of bowel, are the elements that allow you to assess the extent of the occlusion and within how many hours must be backed attempt of endoscopic decompression. In most cases the endoscopic procedure can be performed within 6-8 hours after admission. The anesthesia care required for patients with critical conditions, is that of sedation which may be sufficient for a dose of benzodiazepines. In other cases one resorts to most important sedation. In the course of endoscopic insufflation worsens abdominal distension favoring the onset of further pain and vomiting. For this reason, the SNG and aspiration of intestinal contents, where possible,

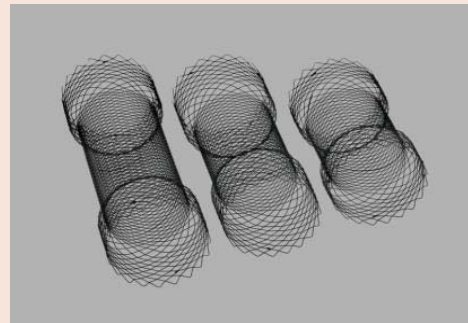


Figure 1: Self-expandable metallic prosthesis.

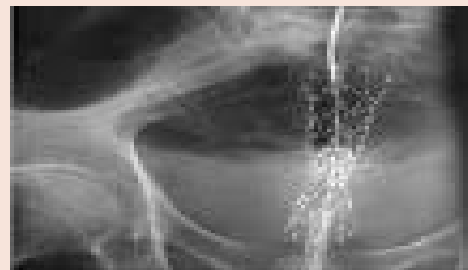


Figure 2: Radiological control.

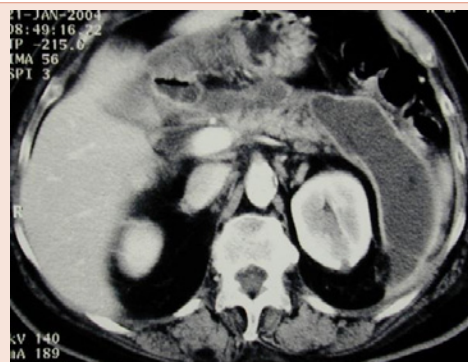

Figure 3: CT scan.

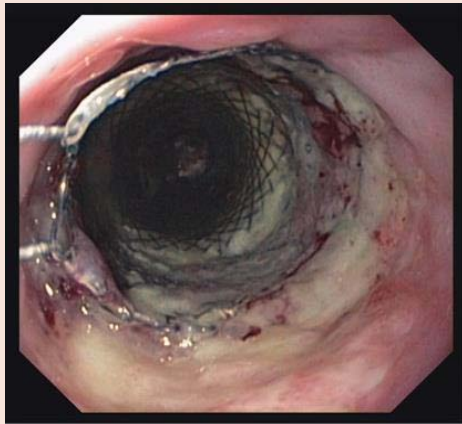


Figure 4: Endoscopic prosthesis.

can help. Subsequently, reached the stenosis, the endoscopist to overcome the stricture using guide-wire and catheter. Once you've crossed the stenosis under radiological contrast graphic control, the guide-wire remains in situ and through a catheter is seeking to defend the section of the colon upstream, in order to avoid a further risk of (late) perforation, taking into account that already the dilatation of the stenosis before the true procedure (pre-dilatation) represents a serious risk factor for intestinal perforation. The stent should have a length of at least 3-4 cm greater than that of the stenosis in order to allow a good fit even in very angled positions where a stent too short could put on the opposite wall increasing the risk of dislocation and perforation of the wall. After the stent adaptation in the stenosis, the release of the prosthesis is under radiological and endoscopic control (Figures 2, 4), come on slowly and gradually. To underline the importance of collaboration with the radiologist responsible not only as for the study of the occlusion, as for the evaluation of the viability of the loop occluded, the size of the obstacle, the overcoming of the stenotic tract with the stent, the absence of perforative complications close of the procedure, the evolution of the channeling (reduction of distension and levels) and the onset of any late complications (in particular the dislocation of the prosthesis).

Discussion

The treatment of a framework of intestinal occlusion usually requires emergency surgery. The latter, despite the usual gastric drainage and an attempt necessarily short of fluid and electrolyte balance, poses different general (ventilatory failure, pH disquilibrium, electrolyte imbalance, etc) and local (intestinal distension, thickening and edema of tissues upstream occlusion, direct damage of tissues in case of strangulation) problems. General alterations jeopardize the evolution of the postoperative course especially involving the cardio-respiratory system, local ones instead can disrupt the evolution of the healing process of the intestinal sutures consequent to the restoration of intestinal continuity after resection loop bowel cancer. Frequently you choose not to carry out the intestinal reconstruction, sends it back to a second intervention. At least we resort to an external user of intestinal transit, to "protect" the suture or better with the objective to reduce the consequences of a serious intestinal

suture dehiscence. These complex problems which in part must also be related to the severity of the occlusive or to the compromise of peritoneum, typically early in the case of strangled occlusion, have long led to the study of measures to improve the consequences of the occlusive or even attempts to solve the framework occlusive same with pharmacological or instrumental methods in cases where there is faced squares occlusive in the absence of throttling. For these reasons, the radiological study using computerized axial tomography is indispensable to define the characters of the occlusion [7], and in particular to judge on the conditions anatomical / radiological of the intestinal tract concerned. Early pharmacological attempts have recommended the use, especially in left colic locations, to cortisone and antineoplastic enemas that may allow reducing edema one, though incomplete, re-channeling. This can allow you to program the intervention under less dramatic conditions. In the early 2002 date the first attempts reanalyze the intestine with endoscopic expandable prosthesis that can achieve true rechanneling, that arises a) as actual treatment for palliation of inoperable patients for gravity of the general conditions or for the presence of repeats neoplastic scattered b) as a "bridge to surgery" in patients in which the resolution of the occlusion allows a radical resection of the tumor with general risk reduction of anesthesia and local risk reduction of surgery. There is no doubt that the resolution of the occlusive picture improves ventilatory conditions, allowing, with the reduction of gas, to expand diaphragmatic excursions; therefore improve the pH towards normality and you can replenish the loss of fluids and salts; the resumption of transit improves intestinal trophism of upstream and downstream loops, so reducing edematous thickening of the walls upstream. This saves resection portions of the intestinal tract upstream occlusion; sutures become safer because the margins tackled become more congruent; finally is also possible, channeling recovery, colon cleansing, which helps reduce the risk of dehiscence of the sutures. The procedure allows greater attention and more time for a radical dissection [13,14]. The prosthesis therefore makes it less risky choice to adopt a onetime surgical procedure. Even in difficult cases, a protective ileostomy allows a simple and safe working towards closing the automatic staplers and relegating to extreme situations the adoption of Hartman's intervention [11]. The current interest (2010/2012) for the procedure, that the increased endoscopic experience makes the reach of every good endoscopic center, the superiority of teamwork (surgeon, endoscopist, radiologist, anesthesiologist), brings out the our initial experience, in effect abandoned after a few cases for both the publication of the Dutch study and the transfer the endoscopist to another hospital. It should of course an accurate assessment of the major risks that the prosthesis involves (perforation, hemorrhage, displacement and new occlusion, etc), and obtain the patient's informed consent. The drilling especially represents approximately 20% of all prosthetic complications. It may be related to the rigidity of the guide wire that passes through the wall of colon, or to dilation presenting able to smash the wall or even cancer or to, and is within 48/72 hours late, the upward trend of the prosthesis itself in scirrous cancers. Even bevacizumab in palliative applications may contribute to perforation at a distance. In the latter, re-stenosis may occur by neoplastic proliferation; coated implants may delay the problem, but tend more than others to dislodge.

Despite everything, no doubt the positive experience of the four cases occurred under our observation (are high, over 90%, the possibilities for proper placement and effectiveness reanalyzing prosthesis) may lead to the conclusion that the prosthetic want palliative want to bridge, may represent a therapeutic option in most armory available to health for better and more appropriately address these health emergencies, because the incidence of complications does not appear in the literature, even in large series, aggregate exceed 5%.

Conclusions

Most severity of the complications occurred in the series made in emergency surgery compared to the series undergoing stent, as well as the consideration that in these serious complications often need further surgery lead us to consider that in patients with colorectal tumor blocking is feasible to implement an attempt endoscopic decompression useful to the recovery of the intestinal channeling overcoming the state of necessity and reporting clinical parameters to an acceptable condition for subsequent excision (bridge to surgery) [14]. Especially in those cases where the clinical conditions do not allow any type of intervention, the procedure is a valid alternative to palliative colostomy. It is necessary to acquire more experience on large series, make a rigorous evaluation of the benefits and risks of the procedure, and obtain from bioengineering new and more suitable materials, to offer patients an adequate answer to their problems.

References

1. Deans GT, Krukowski ZH, Irwin ST (1994) Malignant obstruction of the left colon. *Br J Surg* 81: 1270-1276.
2. Adler DG, Merwat SN (2006) Endoscopic approaches for palliation of luminal gastrointestinal obstruction. *Gastroenterol Clin North Am* 35: 65-82.
3. Harris GJ, Senagore AJ, Lavery IC, Fazio VW (2001) The management of neoplastic colorectal obstruction with colonic endoluminal stenting devices. *Am J Surg* 181: 499-506.
4. Khot UP, Lang AW, Murali K, Parker MC et al. (2002) Systematic review of the efficacy and safety of colorectal stents. *Br J Surg* 89: 1096-1102.
5. Keymling M (2003) Colorectal stenting. *Endoscopy* 35: 234-238.
6. Sebastian S, Johnston S, Geoghegan T et al. (2004) Pooled analysis of the efficacy and safety of self-expanding metal stenting in malignant colorectal obstruction. *Am J Gastroenterol* 99: 2051-2057.
7. Lopez-Kostner F, Hool GR, Lavery IC (1997) Management and causes of acute large-bowel obstruction. *Surg Clin North Am* 77: 1265-1290.
8. Riedl S, Wiebelt H, Bergmann U, Hermanek P Jr (1995) [Postoperative complications and fatalities in surgical therapy of colon carcinoma. Results of the German multicenter study by the Colorectal Carcinoma Study Group]. *Chirurg* 66: 597-606.
9. Dionigi G, Villa F, Rovera F, Boni L, Carrafiello G, et al. (2007) Colonic stenting for malignant disease: review of literature. *Surg Oncology* 16: S153-155.
10. Saida Y, Sumiyama Y, Nagao J (2003) Self-expandable metallic stent in the treatment of colorectal obstruction. *Nippon Geka Gakkai Zasshi* 104: 554-557.
11. Berretta S, Barbagallo E, Bonanno S, D'Agata A, Berretta M, et al. (2000) nostra esperienza sull'intervento di Hartman nelle emergenze colo rettali *Minerva chirurgica* 55: 247-252.
12. Graziano A et al (2007) risk factor of anastomotic complication in rectal cancer. *POLICLINICO. SEZIONE CHIRURGICA* 114: 3-11.
13. F Bianchini, M Celoni, Scabini M, Capelli P (2006) Uso in elezione ed in urgenza delle protesi intestinali. *Ann It Chir* 78: 291-294.
14. Giannesi S, Paroli GM, Fedi M, Riccadonna S, Gori A, (2013) Le protesi colo rettali come bridge to surgery nelle occlusioni intestinali acute. *Min Chir* 68: 299-306.
15. Francesco Stipa, Bruno Bascone, Andrea Cimitan, Giuseppe Villotti, Antonio Burza, et al. (2006) Il trattamento endoscopico/laparoscopico dell'occlusione neoplastica del colon sinistro. *Chir Ital* 58: 197-201.
16. Graziano A (2007) J pouch colon anal reconstruction after anterior resection for cancer *Acta Chirurgica Mediterranea* 23: 97-100,
17. Cavallaro A, Lauretta A, Cavallaro M, Pennisi S, CavallaroM (2006) [Surgery on gastrointestinal stromal tumor CD117+ (G.I.S.T.): personal experience]. *Annali Italiani di Chirurgia* 77: 137-141.