

Meriem N Mrabent¹, Noria Harir¹,
Ferial Sellam^{1*}, Soumia Zeggai¹,
Abdenacer Tou², Mustapha
Diaf¹, Rachida Salah¹ and Soraya
Moulesshou¹

¹Laboratory of Molecular Microbiology, Proteomics and Health, Departement of Biology, Djillali Liabes University of Sidi bel Abbes, Algeria

²Department of Pathology, Hospital of Sidi bel Abbes, Algeria

Dates: Received: 12 September, 2015; Accepted: 26 October, 2015; **Published:** 28 October, 2015

***Corresponding author:** Ferial Sellam, PhD., Department of Biology, Djillali Liabes University of Sidi bel Abbes, (Ex ITMA), Algeria candidate in Cellular Biology and Pathology, E-mail: mayflowerboat@live.fr

www.peertechz.com

ISSN: 2454-2968

Keywords: Breast cancer; Man; Overexpression; ER; PR; HER2

Research Article

HER2 Status in Male Breast Carcinoma: a Single North African Institution Experience of 10 Cases and Review of the Literature

Abstract

Background: To investigate clinic-pathological characteristics, hormonal receptors and HER2 receptor of male breast cancer.

Materials and methods: Retrospective study of 10 cases between 2010 and 2013. The studied parameters were: tumor size, histological type, histological grade, lymph node status, hormonal status and overexpression of HER2.

Results: The average age of our patients was 60.2 years, in 70% of cases; the histological size that was found was T4; and infiltrating ductal carcinoma was diagnosed in all cases. The grades classification was as follow: grade 2 (30%) and grade 3 (70%). 70% of cases had lymph node metastasis. Estrogen and progesterone receptors (ER,PR) were positive in 60% of tumors. Overexpression of HER2 was positive (Score3) in one case. Luminal B was the most common subtype in our study.

Conclusion: Male breast cancer is a rare disease with a poor prognosis despite the recent increase in incidence in recent years. The diagnosis is often delayed and injuries are treated in advanced stages.

Introduction

Breast cancer in men is a rare disease and makes up approximately 1% of all cases of breast cancer [1,2]. The rarity of this entity precludes prospective randomized trials. During 2014 in the USA, about 2,360 new cases of invasive breast cancer were diagnosed in men and about 430 men died from the disease [3]. The etiology of male breast cancer is unclear, but hormone levels and testicular abnormalities play a role in the development of this disease [4,5]. Other recognized risk factors include radiation exposure, family history of breast cancer, Klinefelter syndrome, and different benign breast conditions [4,5].

Previous reports have suggested that cancers of the male breast are more likely than female breast cancers to have a ductal histology and are significantly more likely to express hormone receptors [6,7]. Early reports suggested equivalent or even higher rates of human epidermal growth factor receptor 2 (HER2) overexpression in male breast cancer versus female breast cancer [8,9]. Overexpression of the oncoprotein HER2 observed in 10-15% of patients could justify prescribing trastuzumab. In the context of the considerable progress achieved in the recent years concerning female's breast cancer management, it seems important to review the acquired data and to exploit these advances in order to improve male breast cancer care [10]. In this study we will explore the following pathological parameters: histological type, tumor size, histological grade, lymph node status, hormonal and HER2 status of male breast cancer from western Algeria and compared them with different literatures data.

Material and Method

This cross sectional study was done at the department of pathology at Sidi Bel Abbes University Hospital in Western Algeria from 2010 to 2013. The Male patients with breast cancer were selected for the study. The cases were stained with hematoxyline and eosin (H&E) for routine histological examination. An absolute confidentiality of the patients' vital information was maintained for ethical purposes and an ethical approval was obtained from institutions in which the study was carried out. We used immunohistochemistry to evaluate the expression of HER2, ER, and PR receptor.

Immunohistochemical expression of HER2 was evaluated according to the published scoring guidelines of the 'HerceptTest' (Dako, Carpinteria, CA). Herceptest of score 3+ was considered as positive. Four subtypes were defined: 1) Luminal A; oestrogen receptor (ER) + and/or progesterone receptor (PR) +, HER2 -, grade 1 or grade 2 tumours, 2) Luminal B; ER + and/or PR + and HER2 + tumours or ER+ and/or PR+ and HER2- grade 3 tumours, 3) HER2+; ER -, PR- and HER2 + tumours, 4) Triple negative; ER-, PR-,HER2- tumours.

Graph and circles were done using the SPSS Inc. software (Version20).

Results

10 patients with breast cancer were included; and all of them were men. Median age was about 60.2 years (range, 42-80); The most

affected age groups were 52-61 years (40%) followed by 62 -71 age group (30%) (Figure 1).

Infiltrating ductal carcinoma was diagnosed in all cases. 7 cases of tumors were mainly diagnosed in grade 3 (70%); 3 cases in grade 2 (30%) and lymph node metastasis in 7 cases (70%). T3 and T4 constitute 30% and 70% respectively of the stages (Table 1). The percentage of positive hormonal status was observed in 6 cases (60%), HER2 was +3 in one case (10%), and +2 in 4 cases (40%) of the patients (Figures 2,3). The most common subtype was luminal B (40%) followed by triple negative (30%), luminal A (20%) and HER2+ (10%) subtypes. The Distribution of molecular subtypes of male breast cancer is represented in Table 2.

Discussion

The mean age at diagnosis for male breast cancer in the general population varies in different studies between 62 and 71 years, which is about 5-10 years older than the average age at diagnosis for women [1]. The age frequency distribution in women among the general

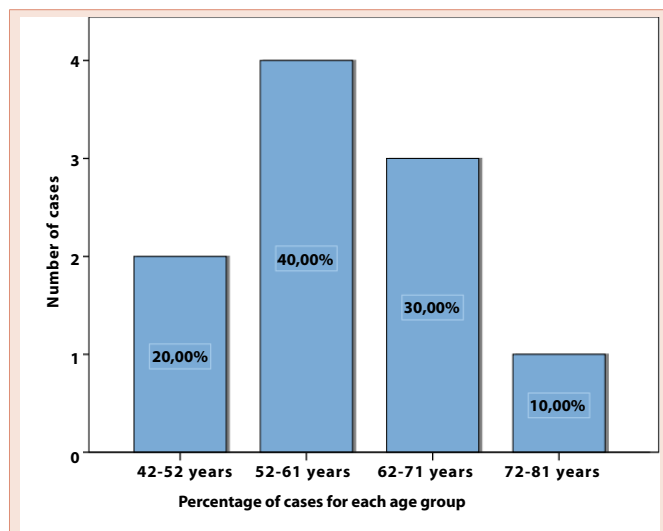


Figure 1: The distribution of cases by age group.

Table 1: Clinico-pathological Features of male Breast Cancer (n=10).

Histology	Infiltrating ductal carcinoma	10 (100%)
Tumor Size	T3	3 (30%)
	T4	7 (70%)
Lymph Node	Negative	3 (30%)
	Positive	7 (70%)
Tumor Grade	Grade2	3 (30%)
	Grade3	7 (70%)
ER*	Negative	4 (40%)
	Positive	6 (60%)
PR**	Negative	4 (40%)
	Positive	6 (60%)
HER2***	Negative	9 (90%)
	positive	1 (10%)

*: Estrogen Receptor.
 **: Progesterone Receptor.
 ***: Human Epidermal Growth factor Receptor 2.

Table 2: Distribution of four molecular subtypes of male Breast cancer (n=10).

Group	No (%)
Luminal A (ER/PR+HER2-)	2 (20%)
Luminal B (ER/PR+HER2+)	4 (40%)
Triple negative (ER/PR-HER2-)	3 (30%)
HER- 2 +ive (ER/PR-HER2+)	1 (10%)
Total	10 (100%)

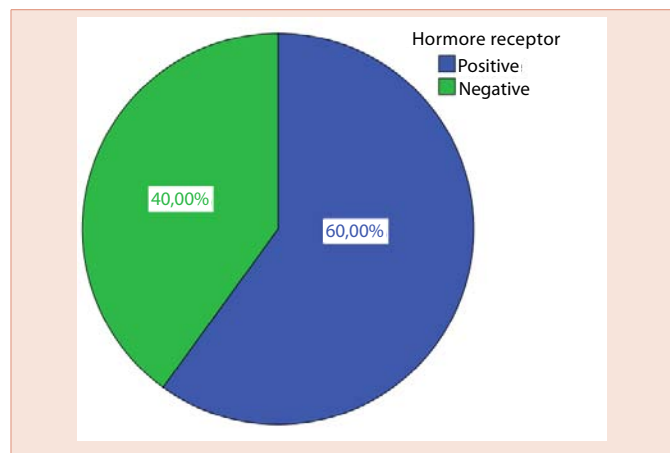


Figure 2: The distribution of cases by hormonal status.

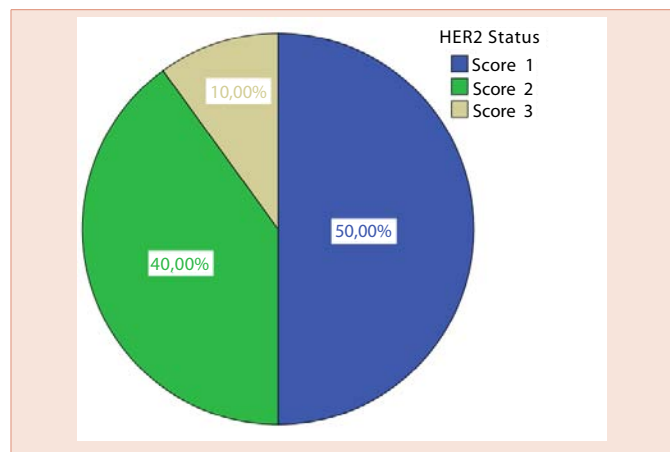


Figure 3: The distribution of cases by HER2 status.

population is bimodal with peaks at 52 and 71 years, whereas in men it is unimodal with a peak age 71 years [11]. The mean age in our study was about 60.2 years (range 42-81 years), which is slightly decreased comparing to other countries. The most predominant histological type in male patients was infiltrating ductal carcinoma, accounting for 85-90% [12]. In our study, infiltrating ductal carcinoma was diagnosed in 100% of cases, this is consistent with published literature [12,13].

The distribution of histological grade according Scarff Bloom Richardson classification was of 30% grade 2 and 70% Grade 3. The T3-T4 lesions represented respectively 30% and 70% of patients, and there was lymph node metastasis in 70% of the cases. Other studies reported that grade I was of 12 to 20%, grade 2 was of 49 to 61% and grade 3 was 22 to 32% grade [13,14]. T3-T4 lesions was in 30% of patients [13,14] there were also clinical axillary invasion in 30 to 50% of the whole cases [13,15,16].

Male breast cancers are significantly more likely in males than in females' breast cancer to express HR. More than 90% of male breast cancers express ER/PR [1,17,18] in contrast to female breast cancers; 60%-70% of female breast cancers are ER or PR positive. In our study expression of ER and PR was in 60% of cases which is less than reported [17,18]. Patients that present a negative hormonal status can't benefit from hormonal treatment [18].

HER2 proto-oncogene is less likely to be overexpressed in cancers of the male breast [19,20]. Recent studies that used standardized methodology have shown a lower rate of HER2 overexpression in men (2%-15%) in comparison with female breast cancers (18-20%) [19,20]. Early reports had suggested equivalent rates of HER2 overexpression between male and female breast cancers [20,21]. A recent series of 75 patients found that only 5% of male breast cancers overexpressed HER2 [22]. Similarly of our result Bloom and colleagues found that only 1 of 58 male breast cancers overexpressed HER2 [19]. Patients presenting a positive HER2 status should be treated with trastuzumab in order to improve their survival [10].

Luminal B was the most common subtype in this population, followed by triple negative, luminal A and HER2 + subtypes. Sánchez Muñoz et al reported that Luminal B was the most common subtype in the male breast cancer patients [23]. Other studies reported a lower proportion of luminal B and triple negative and a higher proportion of Luminal A and HER2 + in male breast cancer [24-28].

Many questions remain regarding the causes, consequences, and optimal care of breast cancer in men. More work is required to further elucidate biological underpinnings, risks and benefits of specific treatments, and quality of life in men with breast cancer. The European Organization for Research and Treatment of Cancer is planning a prospective registry that will collect tissue specimens and diagnostic and treatment information in order to answer critical clinical questions in male breast cancer. We have reason for optimism that future research efforts will facilitate the development of interventions that improve the prognosis of individuals in this unique and understudied population [29].

Conclusion

Our study showed that large tumor size, high tumor grade and lymph node involvement were more common in male breast cancer, these poor prognosis results have a considerable impact on the evolution of the disease and survival. Public awareness of the disease should be improved and an appropriate system for early detection and adequate treatment strategies implemented. Moreover, men presenting with breast symptoms should be examined in the same manner as women to facilitate early detection and better treatment outcomes.

Acknowledgment

The authors would like to thank the members of pathology department of Sidi bel Abbes hospital for their invaluable support, guidance, and educational insight.

Ethical approval:

All procedures performed in studies involving human participants were in accordance with the ethical standards of the institutional and/or national research committee and with the 1964 Helsinki declaration and its later amendments or comparable ethical standards.

References

- Giordano SH, Cohen DS, Buzdar AU, Perkins G, Hortobagyi GN (2004) Breast carcinoma in men: a population-based study. *Cancer* 101: 51-57.
- Burstein HJ, Harris JR, Morrow M (2011) Malignant tumors of the breast. In: DeVita VT Jr, Lawrence TS, Rosenberg SA: *Cancer: Principles and Practice of Oncology*. 9th ed. Philadelphia, Pa: Lippincott Williams & Wilkins 1401-1446.
- American Cancer Society. *Cancer Facts and Figures* (2014). Atlanta, GA: American Cancer Society.
- Giordano SH, Buzdar AU, Hortobagyi GN (2002) Breast cancer in men. *Ann Intern Med* 137: 678-687.
- Korde LA1, Zujewski JA, Kamin L, Giordano S, Domchek S, et al. (2010) Multidisciplinary meeting on male breast cancer: summary and research recommendations. *J Clin Oncol* 28: 2114-2122.
- Anderson WF, Althuis MD, Brinton LA, Devesa SS (2004) Is male breast cancer similar or different than female breast cancer? *Breast Cancer Res Treat* 83: 77-86.
- Stalsberg H, Thomas DB, Rosenblatt KA, et al. (1993) Histologic types and hormone receptors in breast cancer in men: a population-based study in 282 United States men. *Cancer Causes Control* 4: 143-151.
- Leach IH, Ellis IO, Elston CW (1992) c-erb-B-2 expression in male breast carcinoma. *J Clin Pathol* 45: 942.
- Gattuso P, Reddy VB, Green LK, Castelli MJ, Wick RM (1995) Prognostic factors for carcinoma of the male breast. *Int J Surg Pathol* 2: 199-206.
- Comet B, Cutuli B, Penault-Llorca F, Bonnetterre J, Belkacémi Y (2009) Male breast cancer: a review. *Bull Cancer* 96: 181-189.
- Anderson WF, Jatoi I, Tse J, Rosenberg PS (2010) Male breast cancer: a population-based comparison with female breast cancer. *J Clin Onc* 28: 232-239.
- Scott-Conner CE, Jochimsen PR, Menck HR, Winchester DJ (1999) An analysis of male and female breast cancer treatment and survival among demographically identical pairs of patients. *Surgery* 126: 775-780.
- Cutuli B, Lacroze M, Dilhuydy JM, Velten M, De Lafontan B, et al. (1995) Male breast cancer: results of the treatments and prognostic factors in 397 cases. *Eur J Cancer* 31A 1960-1964.
- Stierer M, Rosen H, Weitensfelder W, Hausmaninger H, Teleky B, et al. (1995) Male breast cancer: Austrian experience. *World J Surg* 19: 687-692.
- Lartigau E, el-Jabbour JN, Dubray B, Dische S (1994) Male breast carcinoma: a single centre report of clinical parameters. *Clin Oncol (R Coll Radiol)* 6: 162-166.
- Borgen PI, Wong GY, Vlamis V, Potter C, Hoffmann B, et al. (1992) Current management of male breast cancer. A review of 104 cases. *Ann Surg* 215: 451-457.



17. Dawson PJ, Paine TM, Wolman SR (1992) Immunocytochemical characterization of male breast cancer. *Mod Pathol* 5: 621-625.
18. Wick MR, Sayadi H, Ritter JH, Hill DA, Reddy VB, et al. (1999) Low-stage carcinoma of the male breast. A histologic, immunohistochemical, and flow cytometric comparison with localized female breast carcinoma. *Am J Clin Pathol* 111: 59-69.
19. Bloom KJ, Govil H, Gattuso P, Reddy V, Francescatti D (2001) Status of HER-2 in male and female breast carcinoma. *Am J Surg* 182: 389-392.
20. Blin N, Kardaś I, Welter C, Ryś J, Niezabitowski A, et al. (1993) Expression of the c-erbB2 protooncogene in male breast carcinoma: lack of prognostic significance. *Oncology* 50: 408-411.
21. Rayson D1, Erlichman C, Suman VJ, Roche PC, Wold LE, et al. (1998) Molecular markers in male breast carcinoma. *Cancer* 83: 1947-1955.
22. Muir D, Kanthan R, Kanthan SC (2003) Male versus female breast cancers. A population-based comparative immunohistochemical analysis. *Arch Pathol Lab Med* 127: 36-41.
23. Sánchez-Muñoz A, Román-Jobacho A, Pérez-Villa L, Sánchez-Rovira P, Miramón J, et al. (2012) Male breast cancer: immunohistochemical subtypes and clinical outcome characterization. *Oncology* 83: 228-233.
24. Ge Y, Sneige N, Eltorkey MA, Wang Z, Lin E, et al. (2009) Immunohistochemical characterization of subtypes of male breast carcinoma. *Breast Cancer Res* 11: R28
25. Nilsson C, Johansson I, Ahlin C, Thorstenson S, Amini RM, et al. (2013) Molecular subtyping of male breast cancer using alternative definitions and its prognostic impact. *Acta Oncol* 52: 102-109.
26. Deb S, Jene N, Kconfab Investigators, Fox SB (2012) Genotypic and phenotypic analysis of familial male breast cancer shows under representation of the HER2 and basal subtypes in BRCA-associated carcinomas. *BMC Cancer* 12: 510.
27. Johansson I, Nilsson C, Berglund P, Lauss M, Ringnér M, et al. (2012) Gene expression profiling of primary male breast cancers reveals two unique subgroups and identifies N acetyltransferase-1 (NAT1) as a novel prognostic biomarker. *Breast Cancer Res* 14: R31.
28. Kornegoor R, Verschuur-Maes AH, Buerger H, Hogenes MC, de Bruin PC, et al. (2012) Immunophenotyping of male breast cancer. *Histopathology* 61: 1145-1155.
29. Ruddy KJ, Winer EP (2013) Male breast cancer: risk factors, biology, diagnosis, treatment, and survivorship. *Ann Oncol* 24:1434-1443.

Copyright: © 2015 Mrabent MN, et al. This is an open-access article distributed under the terms of the Creative Commons Attribution License, which permits unrestricted use, distribution, and reproduction in any medium, provided the original author and source are credited.

Citation: Mrabent MN, Harir N, Sellam F, Zeggai S, Tou A, et al. (2015) HER2 Status in Male Breast Carcinoma: a Single North African Institution Experience of 10 Cases and Review of the Literature. *J Surg Surgical Res* 1(3): 049-052. DOI: 10.17352/2454-2968.000013