

António Menezes da Silva*

General Surgeon; President of the World Association of Echinococcosis, Member of the Directive Council of the Portuguese College of General Surgery, Portugal

Dates: Received: 10 October, 2015; Accepted: 26 October, 2015; **Published:** 28 October, 2015

***Corresponding author:** António Menezes da Silva, General Surgeon, Estrada da Luz, 59 – 8º. Dto. – 1600-152 – Lisboa – Portugal, Tel: + 351 919 851 695; E-mail: mensilvapt@yahoo.com

www.peertechz.com

ISSN: 2454-2968

Keywords: Cystic Echinococcosis; Hydatid Cyst; Cyst sterilization; Hydatidectomy; Cystectomy

Case Report

Cystic Echinococcosis in the Liver: Nomenclature and Surgical Procedures

Abstract

Cystic Echinococcosis (CE) is a zoonotic infection caused by larval form of the parasite *Echinococcus granulosus*. The adult tapeworm inhabit the small intestine of some carnivores (called definitive or final hosts), and the larval phase, or “metacestode” develops in the herbivores (intermediate hosts). The presentation form of the larval phase is the development of cysts, called hydatid cysts. Although all of us know the vital cycle of the parasite and the different aspects of the disease, the designations around the parasite, its evolution and some therapeutic procedures is not uniform. In fact we frequently see the use of inappropriate terms, based on incorrect concepts. It would be useful to use the same nomenclature and it is absolutely necessary that the nomenclature is correct and universally accepted. So, it is pertinent to remember some important points related to the CE and, above all, to clarify some aspects concerning its nomenclature, in order to understand better the therapeutic options, particularly the different surgical approaches.

Despite the cysts can be localized in any organ, liver localization is the most frequent (60-70%). The development of a hydatid cyst is slow and usually without specific clinical manifestations, so the diversity of clinical manifestations is related to the anatomical localization of the cyst, its dimension, and the antigens responsible for the systemic hypersensitivity, which can occur in sequence of cyst rupture, spontaneously or traumatic, resulting in secondary echinococcosis. The therapeutic approach has nowadays different possibilities, which will be referred in this manuscript.

Introduction

Human Echinococcosis is a zoonotic infection caused by larval forms (metacestodes) of tapeworms of the genus *Echinococcus*. Although there are different species of *Echinococcus*, only five of them – *E. granulosus*, *E. multilocularis*, *E. oligarthrus*, *E. vogeli* and *E. shiquicus* – are formally recognized currently as taxonomically relevant. To distinguish the diseases caused by these different species, the World Health Organization (WHO) proposed the designation Cystic Echinococcosis (CE) for the disease caused by *E. granulosus*, Alveolar Echinococcosis (AE) for the disease caused by *E. multilocularis*, and Polycystic Echinococcosis (PE) for the disease caused either by *E. vogeli* and *E. oligarthrus*. No human cases due to *E. shiquicus* have ever been observed.

Cystic Echinococcosis is the most frequent of them. Actually *E. granulosus* is not the sole specie causing CE: the genotypes G1-G3 are now grouped as *E. granulosus* sensu stricto, G4 as *E. equinus*, G5 as *E. ortleppi*, G6-G10 as *E. canadensis* and the ‘lion strain’ as *E. felidis*. Among these strains, *E. granulosus* sensu stricto has a broad geographical distribution with a wide host range and is the major causative agent of human CE, but *E. canadensis* has also been identified in humans in many areas of Europe and other regions too.

In the *E. granulosus* vital cycle we consider the adult tapeworm, which lives in the intestine of some carnivores (called definitive or final hosts), and the larval phase, or “metacestode”, which develops in the herbivores (intermediate hosts). The intermediate hosts, in which humans are included, are infected by ingestion of eggs within

the feces of the definitive hosts. Following ingestion of eggs the oncosphere, by lytic secretions, goes through the intestinal mucosa and into the host circulatory system (venous and lymphatic) and reaches one organ, where cystic development begins. This process involves degeneration of the oncospherical stage and emergence of the metacestode stage. The larvae change into a typical “bladder” (vesicle) with a germinal layer, called hydatid cyst, which is the presentation form of the disease in the intermediate hosts. This was other designation for CE in the past, and this is the reason why it was also referred as hydatid disease. However, this designation was also used to designate the other forms of Echinococcosis (Alveolar, Polycystic, etc.), which is wrong. All of us have frequently noticed, in published articles and in communications during scientific meetings, and also in WHO publications, to call hydatid diseases to the different forms of Echinococcosis. That is unacceptable, and it is time to finish the incorrect use of this terminology!

The parasite or “hydatid”

In primary CE the metacestodes (hydatid cysts) develop in various sites from oncospheres after ingestion of *E. granulosus* eggs. The eggs of these tapeworms excreted by carnivores may infect various species of natural intermediate host animals and humans, and may develop in almost any organ. Most patients (up to 80%) have a single organ involved and harbour a solitary cyst, localized in approximately two-thirds of cases in the liver and in about 20% in the lungs.

In secondary CE the larval tissue spreads from the primary site [1], and proliferates after spontaneous or trauma-induced cyst

rupture or after release of viable parasite material during invasive treatment procedures.

The hydatid cyst (Figure 1) is composed of two parts: the echinococcal parasite (or “hydatid”) and the “adventitia” that surrounds it, as Dévé defined it in the beginning of the last century [2], and there is no reason or legitimacy to modify this definition. “Hydatid” is the larval form of the tapeworms of the genus *Echinococcus granulosus* only.

The “adventitia” is a layer of inert tissue, of variable thickness, including with fibrosis, which results from the host’s organ reaction against the hydatid considered as a foreign body. This layer can be called “periparasite” or “perihydatid”, but never pericystic, as it is sometimes wrongly named², because it is an integrant part of the cyst. A common example of this mistake in the nomenclature is the use of the term “pericystectomy” for the excision of a cyst, when removing the adventitia. This term misleads you into thinking that this layer is not part of the cyst, assuming that the cyst includes only the parasite (hydatid) and not the adventitia, which is wrong and opposite to Dévé’s definition.

The hydatid is a sphere composed of two layers with liquid in its interior. The inner layer is called germinal and the outer layer is called laminated (Figure 1). The germinal layer (20-25 micron of thickness) is composed by embryonic cells. Its function is to elaborate the different elements of the hydatid. The laminated layer, which is formed from the previous one, is a white coloured membrane, formed by several concentric layers of polysaccharide material with chitin. Brood capsules, which contain protoscolices and scolices, develop from germinal layer through a cloning/budding mechanism which ensures the fertility of the cyst. Scolices are the final stage of protoscolices, just intussusceptions of the heads of taenias, so, they have got proboscis and hooks too. The hydatid liquid is clean and clear, “as well as the clean water from its natural source”, containing secretions from both the parasite and host and all the elements from the inner wall of the cyst – named hydatid sand, which macroscopically may appear like “thorns”, hence the Greek name of the genus “*Echino* (thorn) *coccus* (round body)”. It has an identical composition to that of the host’s serum (Na, K, Cl, CO₂, a density between 1.008 and 1.015, alkaline pH) and proteins that confer antigenic properties and might have metabolic functions.

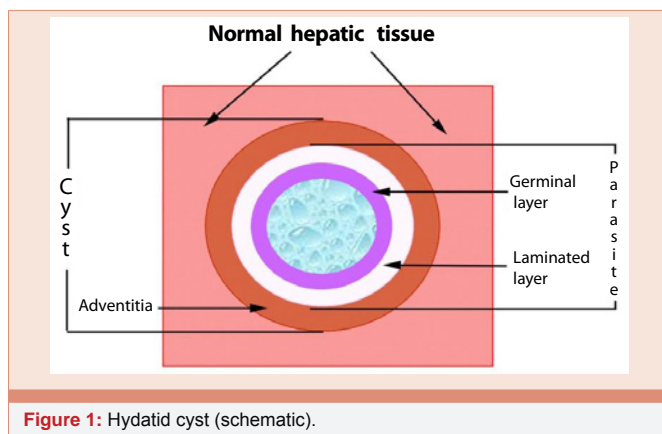


Figure 1: Hydatid cyst (schematic).

During the natural course of infection, the fate of the hydatid cysts is variable. Some cysts may grow (average increase 1 – 30 mm per year) and persist without noticeable change for many years. Others may spontaneously rupture or collapse and can completely disappear. Calcified cysts are not uncommon. Spillage of viable protoscolices after spontaneous or traumatic cyst rupture, or during interventional procedures, may result in secondary Echinococcosis. After an undefined and variable incubation period, CE may become symptomatic if active cysts exert pressure on adjacent tissue and induce other pathologic events. Usually cysts do not induce clinical symptoms until they have reached a particular size. Sudden onset of symptoms may be due to cyst rupture.

Through the slow evolution of a cyst several events can occur: the death of the parasite due to dysfunction of the germinal layer (detachment or aging); the “cyst’s wall” fissure due to detachment of the hydatid layers or micro traumatism; the transformation of protoscolices into vesicles (vesiculation), in an attempt to preserve the species. These new vesicles, which live into the hydatid fluid, must be called offspring or daughter vesicles once they arise from the “mother vesicle”. So, the term “daughter cysts” is incorrect, since the cysts do not have daughters, but only the vesicles. The daughter vesicles have the same constitution as well the same mission as the mother vesicle. So, in this way, protoscolices may evolve into either a new cyst or an adult parasite.

The long-term survival of the hydatid indicates the existence of protection mechanisms against the immune response of the host. The hydatid fluid and the cells of the germinal layer are the main responsible for the antigenic stimulation, but the laminated layer of the cyst is like a functional barrier against immune competent cells of the host. So, any damage in the germinal and laminated layers, like fissures or rupture, will increase antigenic stimulation. When this antigenic stimulation occurs, there is a continuous elevation of the various products of the immune response, and especially antibodies, for an indeterminate time. This elevation also occurs after cyst manipulation after surgery or puncture. Petrone et al. (2015), found immunological correlates associated with CE and biological cyst activity: interleukin-4 levels were significantly higher in CE patients than healthy donors, when whole blood and peripheral blood mononuclear cells were stimulated with Antigen B of *E. granulosus* [3].

Cystic echinococcosis in the liver

Liver localization is the most frequent (60 a 70%) of CE. The development of a hydatid cyst is slow and usually without specific clinical manifestations. In a considerable number of patients the “cyst” is found during an imaging examination made for other reason. In other situations it is diagnosed in asymptomatic patients during screenings in endemic regions [4-6]. The diversity of clinical manifestations is related to the anatomical localization of the cyst, its dimension, and the antigens responsible for the systemic hypersensitivity, which can occur in sequence of cyst rupture, spontaneously or traumatic, resulting in secondary echinococcosis. However its manifestation can be a cyst complication (20 a 40%), resulting from mechanical, toxic or septic effects. The circumstances in which is detected are multiple and the symptoms and signs are

polymorphs, according the cyst (“age”, number, dimension, location), the contiguous organs involved and eventual complications. The patient can refer abdominal pain, dyspepsia, fever, allergic manifestations, which are unspecific complaints [7]. If the patient complaint is right hypochondria pain and he has hepatomegaly, one must think in this diagnosis if he is from endemic regions or countries, particularly those who are in touch with animals, namely dogs and cattle. More rarely are the cysts complications that give the diagnosis. The most frequent complications are: the rupture to the biliary tree, in 15% of the cases [8-10], the rupture to the peritoneal cavity [1,11-13], resulting in anaphylactic shock or acute abdomen.

Therapeutic options

The treatment of CE is complex and based on cyst characteristics, available medical/surgical expertise and equipment, and adherence of patients to long-term monitoring. Because the treatment involves a variety of options and requires specific clinical experience, patients should be referred to recognized reference and national/regional CE treatment centres, whenever available. There is no “best” treatment option for CE and no clinical trial has compared all the different treatment modalities, including “Watch and Wait” [14].

The aim of the treatment of CE is the death of the parasite and consequently the cure of the disease. It has to be done with minimal risks and maximum comfort for the patient, and always paying attention to avoid complications, secondary echinococcosis and relapses [15-17]. The methods to achieve the death of the parasite are both the sterilization of the cyst content, using scolicalid or more generally anti-*Echinococcus* drugs, or the parasite direct removal, through aspiration or the surgical excision of the entire cyst [17,14]. For many years, surgery has been the only treatment available, but with alternative treatment modalities advancing it is pertinent to clarify the current position of surgery among other options [14,18]. One important difference is between complicated and uncomplicated cysts. Before choose the therapeutic modality, one shall decide: 1) what cysts to treat? 2) When to treat the cyst (strategy)? 3) How to treat it (therapeutic option)?

What cysts: complicated cysts shall be treated and also the active uncomplicated cysts: type 1 and 2 according the WHO-US classification (Table 1), so as the cysts on the transitional stage (3a and 3b). The cysts on inactive stage (type 4 and type 5), should not be treated, unless complicated. In these cysts “watch & wait” modality shall be followed.

When: the therapeutic strategy depends on the cyst activity, which is given by the US characteristics, but should also observe the clinical condition of the patient, the technical conditions of the physician, the safety and effectiveness of the therapeutic approach, the patient comfort, and costs of each method.

How: in patients with complicated cysts (rupture, cyst-biliary fistula, compression of vital organs and vessels, haemorrhage) surgery maintains its place as the treatment of choice. In uncomplicated cysts surgery is increasingly being replaced by other treatment options (percutaneous treatment, medical treatment and watch & wait modality).

In uncomplicated CE we can consider two options: non-invasive and invasive approaches.

Non-invasive approach

The non-invasive treatment, also called medical treatment [20], corresponds to the orally administration of anti-infective drugs: albendazole (ABZ), mebendazole (MBZ) or praziquantel (PZQ). MBZ was the first Benzimidazole (BMZ) agent found to have *in vivo* activity in CE. Nowadays ABZ is the drug chosen for oral treatment of CE [21-23]. Its metabolite, the albendazole sulphoxide, is the active component that has a half-life of 8.5 hours [24]. ABZ is orally administered, every 12 hours, in a total dose of 10-15 mg/kg/day. In the past this drug was given during a period that was called “therapeutic cycle” (4 weeks of treatment followed by 2 weeks of interruption), but according to the Expert Consensus published in 2010, this so-called “discontinuous” administration of the drug should not be used any longer to treat CE [25].

The anti-*Echinococcus* effect depends on the stage of development of the cyst and on its germinal membrane integrity too: more effective on young cysts (type 1) and less on type 2 cysts with over 50% of failure rate [26], and more effective on liver cysts than on cysts in other locations, presumably because of a better concentration of the drug in the liver and in the liver cysts [27]. ABZ is also used associated with surgery, or other invasive methods, to reduce the internal cyst’s tension and prevents secondary Echinococcosis [28-30]. Alternatively may be used MBZ at a dosage of 40–50 mg/kg body weight daily, in three divided doses with fat-rich meals, if ABZ is not available or not tolerated. PZQ is the other anti-parasitic drug, which has a limited use in the treatment of liver cysts [31,32], given in a dose of 50 mg/kg either once weekly or every two weeks. Used in combination with ABZ, at a dosage of 40 mg/kg once a week seems more effective and, perhaps, more rapid than ABZ alone [33].

They are indicated for inoperable patients, patients with multiple cysts in two or more organs, or peritoneal cysts. The BMZ compounds are contraindicated in cysts at risk of rupture and in early pregnancy once have been proven teratogenic in rats and rabbits. They must be used with caution in patients with chronic hepatic disease and avoided in those with bone-marrow depression.




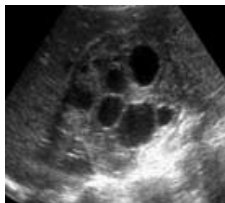
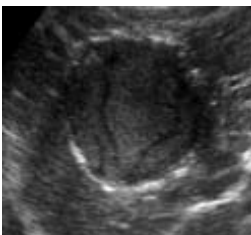

Invasive approaches

The invasive treatment can be done by different methods, including surgery. All non-surgical methods are non-radical procedures. The radical treatment only can be done by surgery.

Non-radical procedures: In non-radical procedures we have two options: the cyst sterilization and the parasite (hydatid) removal, which can be done either removing only the parasite or part of the cyst.

This cyst sterilization is based on the degeneration of the hydatid layers and destruction of the elements of the hydatid fluid due to the effect of anti-parasite drugs, called also “scolicalid” if they are able to kill protoscolices whatever injected into the cyst or orally taken. The injection of a scolicalid solution into the cyst cavity is the most ancient method of treatment for the hepatic cysts. It was considered the best

Table 1: WHO US classification [19].

STAGE	TYPE	CYST CHARACTERISTICS	
I ACTIVE	1	Univesicular anechoic cystic lesion with double line sign, with hydatid fluid, viable protoscolices and scolices	
	2	Multivesicular cyst multiseptated ("rosette-like"/"honeycomb" sign), with multiple daughter vesicles with hydatid fluid, viable protoscolices and scolices	
II TRANSITIONAL	3 a)	Univesicular cystic with detached layers ("water lily-sign"), with hydatid fluid, viable protoscolices and scolices	
	3 b)	Cyst with daughter vesicles in solid matrix. Viable protoscolices and scolices?	
III INACTIVE	4	Old cyst with heterogeneous content (hypo echoic / hyper echoic). No daughter vesicles. The liquid areas can contain protoscolices and scolices (viable?)	
	5	Old cyst with solid content, plus calcified wall (cone-shaped shadow)	

method for treatment of simple cysts (univesicular cysts – type 1 and 3a) in the current ultrasound classification). In the past this procedure was only done by laparotomy, but nowadays we have two approaches more: laparoscopy [34-36], and percutaneous puncture [37,38]. Percutaneous puncture is known as PAIR (Puncture, Aspiration, Injection (of the scolicide) and Re-aspiration) and is considered the gold standard, since it is a minimal invasive technique, it is less painful for the patient as well as it has less complication rate, is less expensive, with earlier discharge and activity resumption [39-43].

To remove the parasite there are two different ways: the aspiration

of the parasite (or hydatid) – procedure called Hydatidectomy, or the excision of the cyst, which necessarily removes the parasite – procedure called Cystectomy. The Hydatidectomy is a procedure that only removes the hydatid (the parasite). It is identical to the puncture method for the sterilization of the cyst except in what concerns the last step (total aspiration). This aspiration is done under high pressure, in order to remove the hydatid layers and all the remaining contents, or using a device that destroy the germinal layer and the cyst content [44]. This method can be performed under laparotomy, laparoscopy or percutaneous puncture, and is indicated in cysts type 2 and 3b)

of the US classification. Percutaneous approach is called PEvac (Puncture and Evacuation) [45], but has also other designations, like MoCaT (Modified Catheterization Technique), technique developed by Akhan et al. since 2002 [46]. These techniques are considered the gold standard once they are minimal invasive, less painful for the patient, have less complication rate, and they are also less expensive, with earlier discharge and activity resumption.

The Cystectomy is a procedure that removes the cyst and consequently the parasite. This procedure only can be performed by surgery. Ideally we shall try to remove the entire cyst (radical treatment), but sometimes it is not possible, because the risk of damage of bilious or vascular structures. In this case the cystectomy will be partial or subtotal [47,48].

Radical procedures: The unique radical procedure corresponds to total cystectomy or organ resection [14]. Total cystectomy consists on the excision of the entire cyst, which is the ideal surgical procedure, once diminish relapses and complications. It can be performed through laparotomy or laparoscopy, both by open or closed methods. In both options, the dissection is made on the outside of the adventitia. The open method is performed by opening the cyst then its aspiration and finally the removal of its content. Only after this step we proceed to the entire cyst “wall” removal. The closed method, known as Napalkoff’s operation, consists of the entire cyst removal without opening it. In the past the dissection was made in sane hepatic tissue (pericystectomy), to guarantee the complete cyst removal: the parasite (hydatid) and the host tissue that surrounds it (adventitia), but after the works of Peng Xin Yu et al., the dissection is made in the virtual space between the adventitia and sane hepatic tissue [49], which is a less bloody space, so it is associated with less complications while being as effective to remove all parasitic tissue. When a total resection can damage bilious or vascular structures a partial cystectomy must be done, despite this is a non-radical procedure. Cystectomy can be performed by video assisted surgery on selected cases, namely small cysts (5 cm in diameter) with peripheral localization. Since the total cystectomy is the ideal approach it should be done by the closed method and without using CO2 due to dissemination risk in case of rupture.

Another option is the hepatic resection (segmentectomy or lobectomy), in case of great size cysts in which there is a high risk of ischemia for the remained hepatic tissue. So, hepatic resection is an option only for selected cases.

Both methods have higher risks per-operatively but fewer rates

of complications and relapses after surgery. On the other side, non-radical methods have less intra-operatively risks but higher rate of long outcome complications and relapses. The main advantage of radical procedures is the immediate healing of the disease which is obtained only when the cyst is completely removed whatever with or without hepatic tissue (cystectomy or hepatic resection).

In Table 2 are referred the therapeutic modalities suggested for uncomplicated cysts, according the cyst stage, based on the cyst characteristics given by the US imaging.

Prevention of complications

Although nowadays the morbidity and mortality of CE surgery have diminished, they cannot be overlooked. The prevention of complications starts with an accurate surgical technique and the necessary caution in the removal of the cysts which are very close to the bilious and vascular intra-hepatic structures [14]. To prevent the relapses it is very important, beyond to protect the surgical field with pads soaked with scolicedal solution [14,50], the administration of ABZ, at least one week before the intervention. This procedure will also prevent a secondary Echinococcosis in case of spillage of the cyst content during the cyst removal. Also after surgery, ABZ shall be administrated during a period of one to three month [14,25].

To prevent cholangitis it is mandatory to search cistobiliary fistulae. The surgeon must pay attention to the cyst content color, and in case of doubt shall scrutinize the presence of bilirubin in the bile-stained content and realize a cholangiography if necessary. Strictly avoiding injection of scolicedal solution into cysts that communicate with the biliary or bronchial tree.

In case of a partial cystectomy or surgical hydatidectomy is performed, the residual cavity needs attention: simple drainage with suction and/or filling with epiploon (omentoplasty) are options to reduce the risk of complications [14].

Conclusion

The treatment of Cystic Echinococcosis has, nowadays, different possibilities. Surgery has a fundamental role, particularly in complicated cysts and multivesicular uncomplicated cysts. Although surgical techniques have improved, considerable controversy continues on the most effective operative technique, the role of cyst aspiration and external drainage, hepatic resection, management of the residual cavity, cyst recurrence after surgery and high rates of complications and mortality related to re-operation for recurrent disease. The more radical the intervention, the higher the intra-

Table 2: Treatment modalities suggested by cyst stage (uncomplicated cysts).

Stage/type*		Suggested		Recommendation/evidence**
Active	Type 1	< 5 cm	ABZ alone	A / I
		> 5 cm	PAIR + ABZ	A / I
	Type 2	PEvac/MoCat/Surgery + ABZ		A / II
Transitional	Type 3a	< 5 cm	ABZ alone	A / I
		> 5 cm	PAIR + ABZ	A / II
	Type 3b	PEvac/MoCat/Surgery + ABZ		A / II
Inactive (type 4 / 5)		No treatment: Wash & wait		B / III

*WHO US classification, 2001.

**Infectious Diseases Society of America grading system (strength of recommendation/quality of evidence).

operative risk, and the lower the frequency of relapse and vice versa in the more non-radical approach.

References

- Dévé F (1946) L'Echinococcose secondaire. Masson & Cie 19460800637.
- Demirleau JC (1973) Traitement des Kystes Hydatiques du Foie. Masson & Cie Éditeurs.
- Petrone L, Vanini V, Petruccioli E, Ettorre GM, Busi Rizzi E, et al. (2015) IL-4 specific-response in whole blood associates with human Cystic Echinococcosis and cyst activity. *J Infect* 70: 299-306.
- Perdomo R, Carbó A, Alvarez C, Monti J (1995) Asymptomatic hepatic cystic echinococcosis (hydatidosis) diagnosed by ultrasonography. *Echinomed* 19: 2-3.
- Frider B, Losada C, Larrieu E, Zavaleta O (1988) Asymptomatic abdominal hydatidosis detected by ultrasonography. *Acta Radiologica* 29: 431-434.
- Larrieu E, Del Carpio M, Salvitti J, Mercapide C, Sustersic J, et al. (2004) Ultrasonographic diagnosis and medical treatment of human cystic echinococcosis in asymptomatic school age carriers: 5 years of follow-up. *Acta Trop* 91: 5-13.
- Klotz F, Nicolas X, Debonne JM, Garcia JF, Andreu JM (2000) Kystes Hydatiques du foie. *Encycl Méd Chir, Hepatologie* 7-023-A-10: 1-12.
- Testas P, François M (1983) La rupture des kystes hydatiques du foie dans les voies biliaires extra-hepatiques. *Chirurgie* 109: 122-125.
- Zargar SA1, Khuroo MS, Khan BA, Dar MY, Alai MS, et al. (1992) Intrahepatic rupture of hepatic hydatid cyst: sonographic and colangiographic appearances. *Gastrointestinal Radiology* 17: 41-45.
- Kornaros S, Aboul-Nour TA (1996) Frank intrahepatic rupture of hydatid hepatic cyst: diagnosis and treatment. *J Am Coll Surg* 183: 466-470.
- Karydakos P, Pierrakakis S, Economou N, Ninos A, Raitsiou B, et al. (1994) [Surgical treatment of ruptures of hydatid cysts of the liver]. *J Chir* 131: 363-370.
- Karavias D, Vagianos C, Kakkos S, Panagopoulos C, Androulakis J (1996) Peritoneal Echinococcosis. *World J Surg* 20: 337-340.
- David de Morais J (2002) Hidatidose abdominal secundária a acidentes traumáticos: a nossa experiência de 20 anos em área endêmica. *Rev Portuguesa Doenç Infec* 1: 6-15.
- Junghanss T, da Silva A, Horton J, Chiodini P, Brunetti E (2008) Clinical Management of Cystic Echinococcosis: State of the Art, Problems and Perspectives. *Am J Trop Med Hyg* 79: 301-311.
- Wen H, New R, Craig P (1993) Diagnosis and treatment of human hydatidosis. *Br J Clin Pharmacol* 35: 565-574.
- Sayek I, Onat D (2001) Diagnosis and treatment of uncomplicated hydatid cyst of the liver. *World J Surg* 25: 21-27.
- Menezes-Silva A (2003) Hydatid cyst of the liver – criteria for the selection of appropriate treatment. *Acta Trop* 85: 237-242.
- Brunetti E, Junghanss T (2009) Update on cystic hydatid disease. *Current Opinion in Infectious Diseases* 22: 497-502.
- WHO Informal Working Group (2003) International classification of ultrasound images in cystic echinococcosis for application in clinical and field epidemiological settings. *Acta Trop* 85: 253-261.
- Saimot AG (2001) Medical treatment of liver hydatidosis. *World J Surg* 25: 15-20.
- Teggi A, Lastilla MG, De Rosa F (1993) Therapy of human hydatid disease with mebendazole and albendazole. *Antimicrob Agents Chemother* 37: 1679-1684.
- Horton RJ (1997) Albendazole in treatment of human cystic echinococcosis: 12 years of experience. *Acta Trop* 64: 79-93.
- Keshmiri M, Baharvahdat H, Fattahi SH, Davachi B, Dabiri RH, et al. (2001) Albendazole versus placebo in treatment of echinococcosis. *Trans R Soc Trop Med Hyg* 95: 190-194.
- Lacey E (1990) Mode of action of benzimidazoles. *Parasitology Today* 6: 112-115.
- Brunetti E, Kern P, Vuitton DA (2010) Writing Panel for the WHO-IWGE. Expert consensus for the diagnosis and treatment of cystic and alveolar echinococcosis in humans. *Acta Trop* 114: 1-16.
- Franchi C, Di Vici B, Teggi A (1999) Long-term evaluation of patients with hydatidosis treated with Benzimidazole carbamates. *Clinical Infectious Diseases* 29: 304-309.
- Chai J, Menghebat, Wei J, Deyu S, Bin L, Jincuo S et al. (2004) Observations on clinical efficacy of albendazole emulsion in 264 cases of hepatic cystic echinococcosis. *Parasitol International* 53: 3-10.
- Morris D (1987) Pre-operative Albendazole therapy for hydatid cyst. *Br J Surgery* 74: 805-806.
- Erzurumlu K, Hokelek M, Gonlusen L, Tas K, Amanvermez R (2000) The effect of albendazole on the prevention of secondary echinococcosis. *Hepato-gastroenterology* 47: 247-250.
- Smego Jr RA, Bhatti S, Khaliq AA, Beg MA (2003) Percutaneous aspiration-injection-reaspiration drainage plus albendazole or mebendazole for hepatic cystic echinococcosis: a meta-analysis. *Clin Infect Dis* 37: 1073-1083.
- Homeida M, Leahy W, Copeland S, Ali MM, Harron DW (1994) Pharmacokinetic interaction between praziquantel and albendazole in Sudanese men. *Ann Trop Med Parasitol* 88: 551-559.
- Urrea-París MA, Moreno MJ, Casado N, Rodriguez-Caabeiro F (1999) *Echinococcus granulosus*: praziquantel treatment against the metacestode stage. *Parasitol Res* 85: 999-1006.
- Bygott JM, Chiodini PL (2009) Praziquantel: neglected drug? Ineffective treatment? Or therapeutic choice in cystic hydatid disease? *Acta Trop* 111: 95-101.
- Alper A, Emre A, Hazar H, Ozden I, Acarli K, et al. (1995) Laparoscopic surgery of the hepatic hydatid disease: Initial results and early follow-up of 16 patients. *World J Surg* 19: 725-728.
- Sağlam A (1996) Laparoscopic treatment of Liver Hydatid Cysts. *Surgical Laparoscopy & Endoscopy* 6: 16-21.
- Manterola C, Fernández O, Muñoz S, Vial M, Losada H, et al. (2002) Laparoscopic pericystectomy for liver hydatid cysts. *Surgical Endoscopy* 16: 521-524.
- Gargouri M, Ben Amor N, Ben Chehida F, Hammou A, Gharbi HA, et al. (1990) Percutaneous treatment of hydatid cysts (*Echinococcus granulosus*). *Cardiovasc Intervent Radiol* 13: 169-173.
- Men S, Hekimoolu B, Yücesoy C, Serdar A, Baran I (1999) Percutaneous treatment of hepatic hydatid cysts: an alternative to surgery. *American Journal of Roentgenology* 172: 83-89.
- Filice C, Brunetti E, Crippa F, Bruno R (1999) Treatment of Echinococcal Abdominal Cysts. *Ultrasound quarterly* 15: 223-233.
- Akhan O, Özmen M (1999) Percutaneous treatment of liver hydatid cysts. *Eur J Radiol* 32: 76-85.
- Giorgio A, Tarantino L, de Setafano G, Francisca G, Mariniello N, et al. (2001) Hydatid liver cyst: an 11-year experience of treatment with percutaneous aspiration and ethanol injection [In Process Citation]. *J Ultrasound Med* 20: 729-738.
- Brunetti E, Troia G, Gartlaschelli AL, Gulizia R, Filice C (2004) Twenty years of percutaneous treatments for cystic echinococcosis: a preliminary assessment of their use and safety. *Parassitologia* 46: 367-370.
- Yagci G, Ustunsoz B, Kaymakcioglu N, Bozlar U, Gorgulu S, et al. (2005) Results of surgical, laparoscopic, and percutaneous treatment for hydatid



- disease of the liver: 10 years' experience with 355 patients. *World J Surg* 29: 1670-1679.
44. Saremi F, McNamara T (1995) Hydatid cysts of the liver: long-term results of percutaneous treatment using a cutting instrument. *AJR Am J Roentgenol* 165: 1163-1167.
45. Schipper HG, Lameris JS, van Delden OM, Rauws EA, Kager PA (2002) Percutaneous evacuation (PEVAC) of multivesicular echinococcal cysts with or without cystobiliary fistulas which contain non-drainable material: first results of a modified PAIR method. *Gut* 50: 718-723.
46. Akhan O, Gumus B, Akinci D, Karcaaltincaba M, Ozmen M (2007) Diagnosis and percutaneous treatment of soft-tissue hydatid cysts. *Cardiovasc Intervent Radiol* 30: 419-425.
47. Magistrelli P, Masetti R, Coppola R, Messia A, Nuzzo G, et al. (1991) Surgical treatment of hydatid disease of the liver. A 20-year experience. *Arch Surg* 126: 518-522.
48. Taylor B, Langer B (1998) Current surgical management of hepatic cyst disease. *Advances in Surgery* 31: 129-148.
49. Peng X, Zhang S, Niu JH (2002) Total sub adventitial cystectomy for the treatment of 30 patients with hepatic hydatid cysts. *Chin. J. Gen. Surg* 17: 529-530.
50. Djilali G (1997) Surgical treatment of cystic Echinococcosis of liver: The place of scolicides. *Archivos Internacionales de la Hidatidosis* 32: 177-179.

Copyright: © 2015 da Silva AM. This is an open-access article distributed under the terms of the Creative Commons Attribution License, which permits unrestricted use, distribution, and reproduction in any medium, provided the original author and source are credited.

Citation: da Silva AM (2015) Cystic Echinococcosis in the Liver: Nomenclature and Surgical Procedures. *J Surg Surgical Res* 1(3): 059-065. DOI: 10.17352/2454-2968.000015