

Nickul N Shah^{1*}, David Roman² and Roland Purcell³

Interfaith Medical Center, 1545 Atlantic Avenue, Brooklyn NY 11213, USA

Dates: Received: 02 November, 2015; Accepted: 17 November, 2015; Published: 19 November, 2015

*Corresponding author: Nickul N. Shah, Interfaith Medical Center, 1545, Atlantic Avenue, Brooklyn NY 11213, E-mail: shah.nickul@gmail.com

www.peertechz.com

ISSN: 2454-2968

Keywords: Ulnar artery thrombosis; Ulnar nerve compression; Superficial ulnar artery

Case Report

Aberrant Ulnar Artery and Ulnar Artery Thrombosis with Nerve Entrapment: A Case Report

Abstract

Introduction: Vascular compromise causes hand pain, and physical examination requires to differentiate vascular causes from isolated ulnar nerve compression. Diagnostic studies visualize vascular abnormalities such as CT scans, MRA scans, and AV fistulograms. Ulnar artery aneurysms are quite rare discoveries, related to repetitive trauma, vasculitis, anatomic abnormalities, or infections. It is essential to repair any aneurysm when flow impediment causes significant symptoms. Blunt injury to the ulnar artery and superficial palmar arch damages the arterial wall and forms an aneurysm. The sensory branch of the ulnar nerve becomes compressed. Treatment here is to resect the thrombotic segment to relieve the compression. It is interesting to note, that a high origin and superficial ulnar artery had coursed along the forearm and entered along the ulnar side of the hand. The presence of such anatomic variations are essential in medical practice.

Case presentation: A 73-year-old Haitian female was admitted to the hospital with complaints of numbness and weakness along the right forearm and wrist. According to the patient's daughter, she has experienced these symptoms for at least two years' duration after minimal trauma to her right hand. Upon physical examination of the right wrist, a 3-cm palpable, pulsatile ulnar mass was found. The Allen's test showed no significant abnormalities, but the Tinel's test and pinprick examination were diminished. An AV fistulogram was scheduled the same day and a repair followed soon after. IV contrast dye demonstrated an aneurysm of the ulnar artery, along with an adjacent superficial branch. The decision was made to resect the aneurysm and allow the superficial ulnar artery remain patent for continuous blood supply to the 4th and 5th digits of her right hand. She was discharged the same day and to follow up in the vascular clinic a week later.

Conclusion: This particular case describes a couple important disciplines that establishes further insight about the human anatomy, pathophysiology and vascular surgical management. First, hypothenar hammer syndrome has been illustrated in a patient without any history of vasculitis, infections, or congenital anatomic abnormalities. A diagnostic and therapeutic approach is necessary to relieve ulnar nerve entrapment. Second, this particular patient underwent a simple repair but it was found that an aberrant ulnar artery was discovered, which coursed adjacent and superficial to the aneurysm. It is important to establish an early diagnosis prior to any surgical procedures. Intraoperatively, proper identification to isolate and establish a continuous blood flow is essential. Knowledge of such variations allows for improved care in the fields of radiology, angiography, surgery and the medical sciences.

Introduction

Aneurysmal formations often result from excessive dilatation secondary to damage of blood vessel walls. Aneurysms of the ulnar artery and palmar arch arise from rare circumstances, usually related to repetitive trauma of the upper extremity, which affects the hypothenar region of the hand. As a result, adults can experience hand and finger pain from vascular insufficiency and compression of the ulnar nerve. However, most traumatic aneurysms are quite common among young males, and sometimes related to congenital abnormalities or infections. A Duplex ultrasound and AV Fistulogram identified an aneurysm in a 73-year-old woman after a minor injury. In addition, a superficial ulnar artery of high origin was identified, lying superficial and adjacent to the aneurysm.

Case Presentation

A 73-year-old, non-smoker, Haitian woman was accompanied with her daughter to the community hospital. The patient spoke

very little English, but her daughter translated. As per her daughter, the patient complained of numbness, pain and weakness along the right arm, forearm, and wrist. She had visited her home in Haiti two years ago, and believed she unintentionally "bumped her hand on something". The patient has a significant past medical history of hypertension, arthritis of both her hands, bilateral cataracts, and a right sided lumpectomy. Upon examination, she appeared to be well nourished, without apparent distress, was alert and oriented. A 3-cm pulsatile mass was observed at the ulnar side of the right wrist with a palpable thrill. No obvious signs of trauma were observed. She had numbness and tingling along the 4th and 5th digits of her right hand, but strength was preserved. The Allen's test was conducted, and no significant abnormalities were observed. A Tinel's test was also conducted, but showed hyporeflexia. Pinprick sensation was also diminished along the ulnar distribution of the hand.

Subsequently, she underwent an AV fistulogram, which demonstrated the dilated vessel and aberrant branch of an ulnar

artery. A contrast dye was utilized to isolate the aneurysm and observe the continuity of blood flow. It showed that there was no disruption of flow proximal or distal to the aneurysm as well as the adjacent artery (Figures 1A-1C).

A resection of the right wrist aneurysm was scheduled the same day. After desensitizing her pain under local anaesthesia, a longitudinal incision was created to expose the aneurysm and its bifurcation points. Intraoperatively, the patient's vitals were stable. During the operation, however, an aberrant ulnar artery was observed, which was found medial to the aneurysm (Figure 2a and 2b). Special care was facilitated in order to avoid damage to the artery or the flow to the hand. Multiple microvascular connections were observed with the aneurysm, and again special care was needed to isolate the aneurysm without excessive blood loss. Ring handle bulldogs were placed in a tangential fashion to occlude flow of the aneurysm and its branch points. The microvascular connections were ligated throughout the procedure while still exposing the aneurysm and the artery of interest. Once the aneurysm was isolated both proximally and distally using additional clamps, it was later resected for histopathological evaluation

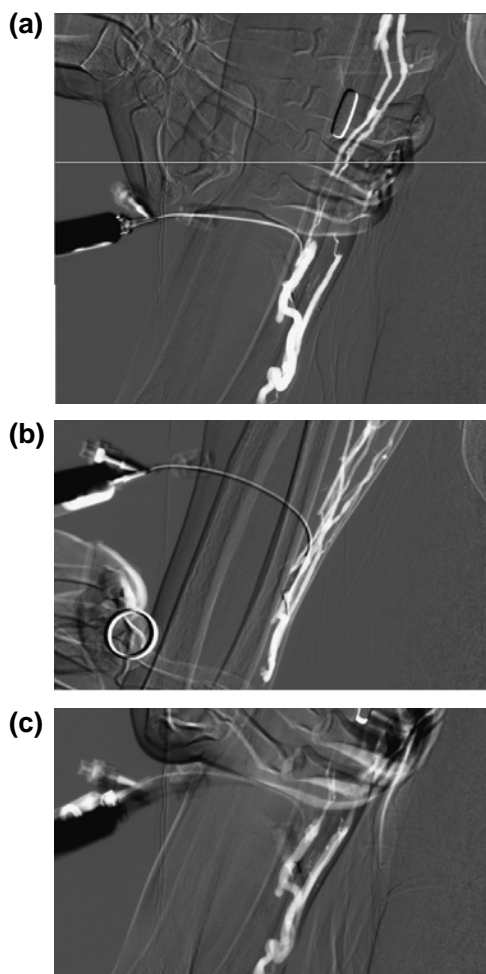


Figure 1 : AV fistulogram used to demonstrate the flow of aberrant artery and distal aneurysmal dilation as shown by filling contrast.

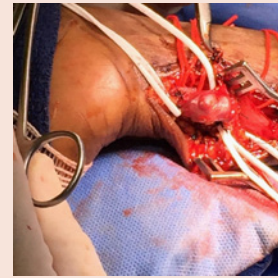

Figure 2a: Intraoperative exploration of the ulnar artery aneurysm identified and isolated.

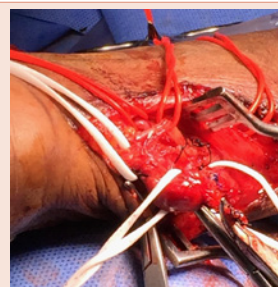


Figure 2b: High origin and superficial course of ulnar artery identified intraoperatively.

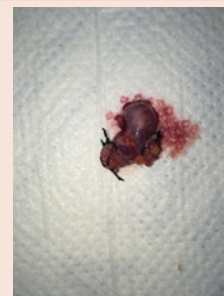


Figure 3: Resected, isolated thrombotic aneurysm, measured at 3-cm, sent for histopathologic review.

(Figures 3, 4a and 4b). As shown by (Figures 4a and 4b), there was an abnormality in the architecture of the resected aneurysm under low and high power, suggestive of thrombus formation. The isolated aberrant artery was patent throughout the procedure with continuous flow, as detected by the Doppler Ultrasound. A 3-0 Nylon suture was used to close the wound. The Allen's test was again applied to test for adequacy of blood flow to the hand, and no abnormalities were found. Pinprick sensation and Tinel's test had significantly improved. The patient's vitals remained stable throughout the procedure. Post-operatively, she was awake without any complications from the procedure. Her pain was adequately controlled in the recovery room. She was discharged home with her daughter the same day.

The patient was advised to follow up in the outpatient clinic a week later. She was also informed to visit the hospital if any complications arose prior to her scheduled clinic appointment.

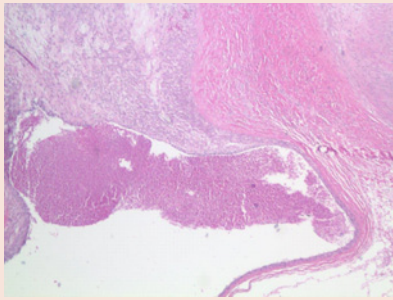


Figure 4a: Low magnification of excised aneurysm showing significant wall thickening. Intimal degeneration and thrombus formation with loss of smooth muscle and elastic fibers.

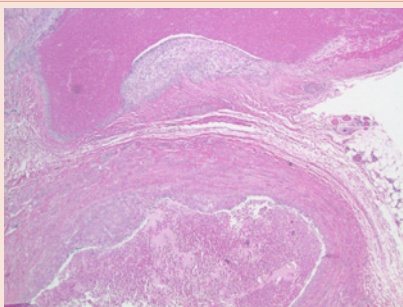


Figure 4b: Higher magnification showing wall thickening, collagen infiltration and marked derangement of wall architecture.

Discussion

Aneurysms of the ulnar artery and palmar arch arise from repetitive trauma, which involve the upper extremity, or vasculitis. They are often found in young males, sometimes related to anatomic vascular anomalies or infections. However, distal ulnar artery and palmar arch aneurysms are uncommon clinical findings, usually associated with Hypothenar Hammer Syndrome [1]. Hypothenar Hammer Syndrome is a rare condition, with an incidence of up to 14% and considered a less common etiology of ischemia in the upper extremity from a repetitive or single trauma to the region of the hypothenar eminence [2]. The pathogenesis, as described by Ablett and Hackett [3], is related to the anatomy of the ulnar artery as it enters the palm and exits the Guyon's canal to form the superficial palmar branch. This arterial segment is susceptible to injury because of its limited protection from overlying tissues of the hypothenar muscles. According to an article by Blum et al. [4], both radial artery and ulnar artery provide most of the blood supply to the hand and additional circulation arise from the median artery or the interosseous arterial system. The deep palmar arch and superficial palmar arch are most significant circuits as they supply blood to each finger [3,4]. The superficial palmar arch supplies all the fingers and the ulnar side of the thumb. The deep palmar arch has a connection with the deep palmar branch of the ulnar artery above the level of the hamulus. Repetitive blunt trauma can damage the intima of the ulnar artery as it passes adjacent to the hook of hamate. Subsequently, the artery becomes aneurysmal or thrombose, affecting digital arteries [5,6]. Hypothenar

hammer syndrome arises because of the anatomic relationship of the sensory branch of the ulnar nerve and the superficial branch of the ulnar artery in association with the hamulus [4]. Ferris and his colleagues have also suggested a fibromuscular dysplasia etiology in which the intimal and medial hyperplasia resulted in a disruption in the internal elastic lamina with areas of stenosis and dilatation [2].

Ulnar neuropathy, also known as Guyon Canal Syndrome, should also be placed as a differential to explain this patient's neurological symptoms. As described by Blum [4], ulnar neuropathy affects athletes involved in cycling (handlebar palsy), in which repetitive and continuous pressure onto the wrist can compress the ulnar nerve. It may also affect workers who are exposed to frequent vibrations such as those who work in foundries. Lastly, adjacent masses such as lipomas, anomalous muscles, ulnar artery aneurysms, hamulus fractures can entrap the nerve. Nerve entrapment caused by an ulnar artery aneurysm can affect the superficial or sensory branch of the nerve and decrease sensory loss to the hypothenar eminence, including the fourth and fifth digits. There is tenderness to palpation, and patients may complain of paresthesias, weakness, and tingling that radiates to the fourth and fifth digits.

In contrast to the literature, this case is unique in that the patient described is a 73-year-old woman, with only a significant past medical history of hypertension and arthritis, who did not injure herself through occupational or sports activity that cause repetitive micro-trauma on the heel of the hand [1]. However, she did experience neurologic symptoms such as paraesthesia, as the sensory branches of the ulnar nerves coursed in close proximity to the ulnar artery aneurysm. In addition, a pulsatile hypothenar mass was present after the formation of the aneurysm. There were no signs of digital ischemia, cyanosis, or atrophic ulcerations.

Initially, this patient was evaluated using the Allen's test to assess the patency of the superficial palmar arch. A positive Allen's test suggest occlusion, stenosis or incomplete development of the superficial palmar arch or distal ulnar artery [3]. In addition, a fistulogram was utilized to observe a proximal stenosis that may be present [7]. Upon reviewing the literature, it was agreed that a Doppler Ultrasound examination of the extremity and serial arteriograms are useful to evaluate the aneurysm, and differentiate it against other vascular anomalies. For example, fibromuscular dysplasia can be ruled out because of the absence of a corkscrew sign that demonstrates areas of stenosis and ectasia [8]. It was decided, therefore, to surgically resect the aneurysm. Reasons to repair an aneurysm were skin changes such as thinning or erosion, inflammation, pain, and thrombosis with flow impediment. If left untreated, local compression, emboli, distal ischemia, or rupture can develop [9,10]. The resected aneurysm (Figure 3) was sent for pathologic evaluation, which demonstrated wall thickening and abnormality of the vessel wall architecture due to thrombosis (Figure 4a and 4b).

Intraoperatively, there was an anatomical variation in the vascular bundle (Figure 2a and 2b), which was isolated and evaluated using the Doppler. According to Balla [11], the presence of an ulnar artery of high origin is considered a rare anatomical variation. Pulakunta et al have also reported a variation of a co-existence of a superficial ulnar artery and an adjacent aneurysm of the deep palmar arch in the hand

[12]. The arterial course can lead to a higher risk of damage during vascular surgery. Therefore, the use of a Doppler was necessary to demonstrate the patency of both the ulnar artery and its superficial branch. After resecting the aneurysm (Figure 3), the aberrant artery remained and the Allen's test was again conducted to show perfusion of the deep palmar arch.

Conclusion

Most aneurysms in the forearm are found in the distal artery, often combined with traumatic events [13]. The resultant trauma to the hypothenar eminence can cause entrapment within the Guyon's canal and compress the sensory branch of the ulnar nerve. To prevent irreversible consequences, surgical intervention was mandatory. A preoperative assessment of the artery was demonstrated using the Allen's test, Doppler Ultrasound, and Fistulogram. Upon isolation and resection of the aneurysm, an aberrant superficial ulnar artery was identified. Careful evaluation of its persistent flow prevented its obliteration intraoperatively. Its patency prevented this patient's complications such as ischemia and gangrene. Knowledge of such anatomical variations are very important to all fields of medicine in clinical practice. Physical examination, diagnostic studies, and the evaluation for surgical intervention are necessary to prevent irreversible damage.

Acknowledgements

We would like to acknowledge Dr. Shamah Iqbal for her contributions to providing histopathological information from the biopsied specimen.

References

1. Mazzaccaro D, Malacrida G, Stegher S, Occhiuto MT, Caldana M, et al. (2012) Ulnar Artery Aneurysm: case report and review of the literature. *G Chir* 33: 110-113.
2. Nitecki S, Anekstein Y, Karram T, Peer A, Bass A et al. (2008) Hypothenar Hammer Syndrome: Apropos of Six Cases and Review of Literature. *Vascular* 16: 279-282.
3. Ablett TC, Hackett LA (2008) Hypothenar Hammer Syndrome: Case Reports and Brief Review. *Clinical Medicine and Research* 6: 3-8.
4. Blum AG, Zabel JP, Kohlmann R, Batch T, Barbara K, et al. (2006) Pathologic Conditions of the Hypothenar Eminence: Evaluation with Multidetector CT and MR Imaging. *Radiographics* 26: 1021-1044.
5. Smith HE, Dirks M, Patterson RB (2004) Hypothenar Hammer Syndrome: Distal Ulnar Artery Reconstruction with Autologous Inferior Epigastric Artery. *J Vasc Surg* 40: 1238-1248.
6. Monacelli G, Rizzo MI, Spagnoli AM, Monarca C, Scuderi N, et al. (2010) Ulnar Artery Thrombosis and Nerve Entrapment at Guyon's Canal: Our Diagnostic and Therapeutic Algorithm. *In vivo* 24: 779-782.
7. Lo H-Y, Tan S-G (2007) Arteriovenous Fistula Aneurysm – Plicate, Not Ligate. *Annals Academy of Medicine* 36: 851-853.
8. Cook RA (2003) Hypothenar Hammer Syndrome: A Discrete Syndrome to be Distinguished from Hand-Arm Vibration Syndrome. *Occupational Medicine* 53: 320-324.
9. Pasklinsky G, Meisner RJ, Labropoulos N, Leon L, Gasparis AP, et al. (2011) Management of True Aneurysms of Hemodialysis Access Fistulas. *J Vasc Surg* 53: 1291-1297.
10. Karatepe C, Yetim TD (2011) Treatment of Aneurysm of Hemodialysis Access Arteriovenous Fistulas. *Turkish Journal of Thoracic and Cardiovascular Surg* 19: 566-569.
11. Balla L, Syamala G, Prasa KSN (2015) High Origin and Aberrant Superficial Course of Ulnar Artery: A Case Report. *IOSR Journal of Dental and Medical Sciences (IOSR-JDMS)* 14: 7-9.
12. Pulakunta T, Potu BK, Vollala VR, Gorantla VR, Thomas H, et al. (2009) Co-existence of superficial ulnar artery and aneurysm of the deep palmar arch in the hand. *Bratis Lek Listy* 110: 738-739.
13. Weinand C, Akbari C, O'Donnell S (2011) A High Bifurcation of the Dorsal Branch with Dominant Superficial Palmar Branch of the Radial Artery: A Case Report of an Aberrant Radial Artery with Traumatic Aneurysm. *J Hand Microsurg* 3: 78-81.