

Andi Nugraha Sendjaja*, Agung Budi Sutiono, Ahmad Faried and Muhammad Zafrullah Arifin

Department of Neurosurgery, Hasan Sadikin Hospital – Padjadjaran University Faculty of Medicine, Bandung Indonesia

Dates: Received: 09 December, 2015; Accepted: 02 January, 2016; Published: 07 January, 2016

***Corresponding author:** Andi Nugraha Sendjaja, MD, Department of Neurosurgery, Hasan Sadikin Hospital, Padjadjaran University Faculty of Medicine, Jl Pasteur 38 Bandung Indonesia, Tel/Fax: 62-22-2041694; E-mail: andsendjaja@gmail.com

www.peertechz.com

ISSN: 2455-2968

Keywords: Open depressed; Compound elevated; Skull fracture; Superior sagittal sinus

Case Report

Open Depressed and Compound Elevated Skull Fracture over the Superior Sagittal Sinus: A Case Report

Abstract

This is a case report of an open depressed and compound elevated skull fracture that located in the area where superior sagittal sinus lies beneath. This is a very rare variant of skull fractures. This patient was admitted to our Department of Neurosurgery Hasan Sadikin Hospital, Bandung Indonesia. He is a 14 years old male with motor vehicle accident and diagnosed with compound elevated and depressed skull fracture. A CT Scan demonstrated an Epidural hematoma with suggested cerebral prolapse. The initial GCS was 15 with slight hemiparesis and the patient underwent an emergency surgery. The elevated skull compound was fixated by a titanium mesh but we left the prolapse untouched, then the procedure followed by duraplasty using a pericranial flap. After 7 days of post-op treatment he was discharged without any neurological deficit. With proper emergency surgery, and by preserving the prolapsed brain tissue with fixation on the elevated skull fracture to prevent further injury may give a good results on this patient.

Introduction

Skull fractures are classified into linear, depressed and comminuted [1]. A depressed fracture is one wherein the fractured fragment driven inwards. On the other hand, in elevated fracture, the fractured portion is elevated above the level of the intact skull [2]. Compound elevated fractures are caused by tangential injuries which slice off a portion of the scalp, skull and the underlying Dura and brain. They are frequently due to assaults with sharp edged weapons [3]. The principle of management is identical to those of compound depressed fractures with the elevated bone fragments being replaced into position after proper closure of the Dura. Delay or failure to operate these may result in meningitis or formation of abscess [4].

A fourteen years old boy suffered a blunt force trauma onto the top of his head, caused by motor vehicle accident. Skull X-Ray performed 3 hours after accident, showed depressed skull fracture more than 1 table located mid-parietal with adjacent linear fracture (Figures 1, 2). The patient was fully conscious with Glasgow Coma Scale scored 15, a lacerated wound located at mid parietal sized 6x3 cm based on bone fracture (Figure 5), there was no history of unconscious, vomiting, and bleeding from ear, mouth, nose after accident although a slight hemiparesis was detected. An emergency hemorrhage-control scalp stiches was done in nearby emergency facilities. We performed head CT-Scan and found a depressed skull fractured at mid parietal with an epidural hematoma located on top of Superior Sagittal Sinus, a 3D skull reconstruction was performed to get a more detailed information about the fracture (Figures 2, 3, 4).

We performed an emergency craniectomy procedure plus debridement, during operation an adjacent linear fracture was located

(about 18 cm long), we also located an epidural hematoma in the same location underneath the fracture (about 20cc in volume), the inward force of the depressed skull fragment cause a dural laceration (about 2 cm wide) and caused the brain tissue of the right post central gyrus to prolapse through (Figure 6). After removing the ekstradural hematomas plus the bone fragment, a duraplasty was followed using a pericranial flap but the prolapsed brain tissue remain untouched. A 100 x 100 mm titanium mesh was used to fix the bone defect, screwed by 5mm mini screws (Figure 7) then the scalp was sutured.

Within 4 days follow up, the patient already gain a full consciousness (GCS 15) and hemiparesis was fully diminished. The patient discharged after 7 days with good condition.

Discussion and Results

Skull fractures are classified in three ways: by pattern (linear,

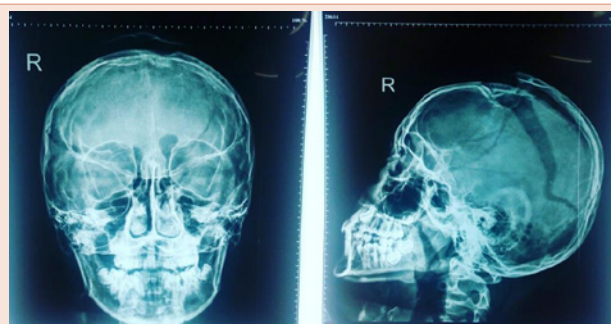


Figure 1: Skull Xray anteroposterior & lateral view.

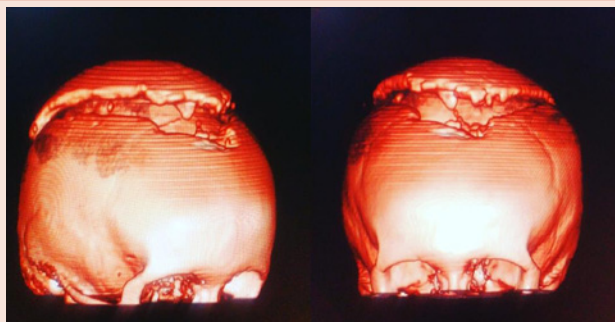


Figure 2: 3D reconstruction of skull.

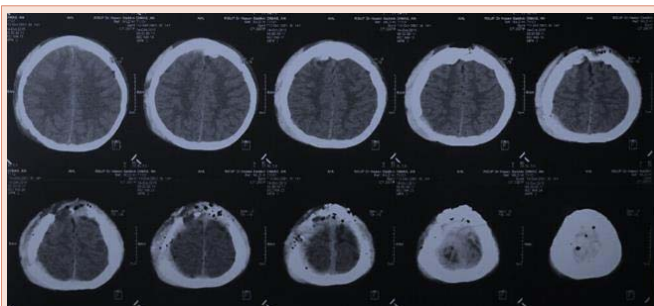


Figure 3: Non contrast Head CT-Scan (Brain window).

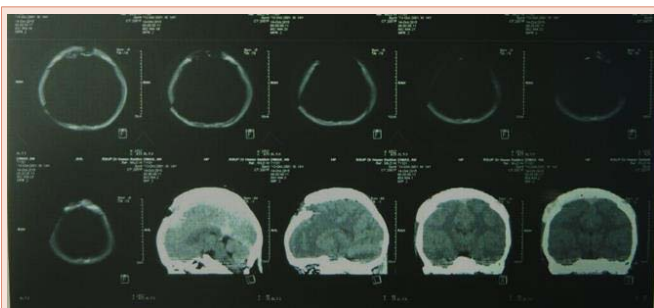


Figure 4: Non contrast Head CT-Scan (Bone Window).

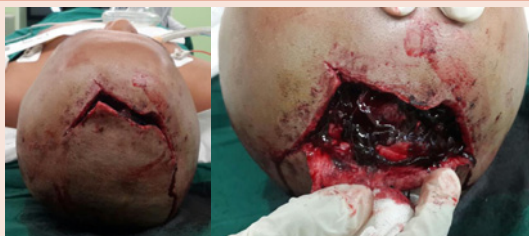

Figure 5: Clinical pictures : Scalp laceration on the top of Superior Sagittal Sinus, see bone fragments and epidural hematoma.

comminuted, and depressed), by anatomical location (vault convexity, base), and by skin integrity (open, closed). The pattern of a skull fracture is affected by two factors. The first factor is the force of impact. A linear fracture results first at a point of weakness

when the skull structure fails to undergo further elastic deformation as a response to impact; the fracture typically starts at the point of weakness in response to the maximal stress (the point of weakness is often remote from the actual impact point) and then extends to the point of impact.

A comminuted fracture results when the impact force is sufficient to break the bone into multiple pieces under the point of impact and further through areas of weakness. Comminution absorbs the force of the injury. With even larger impact energies, the comminuted pieces can be driven inward to create a depressed fracture and may penetrate the dura and cortical surface of the brain.

The second factor is the ratio of the impact force to the impact area. If the impact, even one of high energy, is dispersed over a large area, as in a blunt head injury to an individual wearing a motorcycle helmet, it often produces no skull fracture, even though the brain may be severely injured. Parenthetically, it should be noted that some helmets, by the efficiency of their very force-transferring protection, have created basal skull fractures by transferred energy absorbed from protection of the vault and face and then transmitted through the mandible via the chin strap to the skull base. However, if the impact, even one of low energy, is concentrated in a small area, such as from a hammer blow, it often produces a small depressed fracture with multiple linear skull fractures radiating from the site of impact.

A linear skull fracture is a single fracture line that goes through the entire thickness of the skull. Linear skull fractures require no stabilization or exploration when the scalp is closed, and when there is no evidence of epidural hematoma or underlying dural or cortical injury. Even when a scalp laceration is present, very seldom is surgical

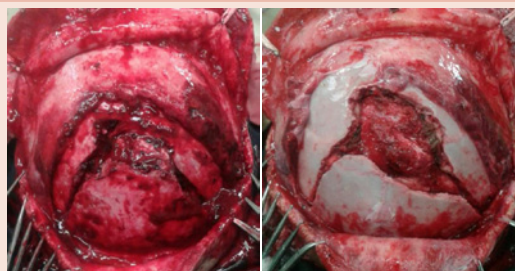


Figure 6: Intraoperative Finding; Left : depressed bone fragment located over the superior sagittal sinus, compound elevated fracture; Right : after the depressed bone fragment removed, we can see prolapsing brain tissue.

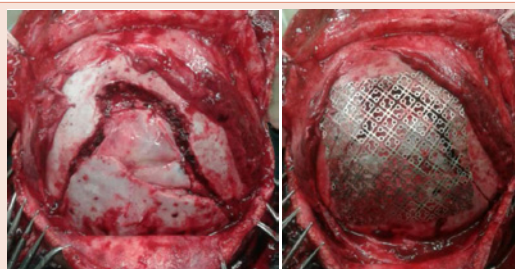


Figure 7: Intraoperative finding; Left : Duramater after patched by pericranial flap; Right : Bone defect closure with 10x10 Titanium mesh.

exploration with bone removal necessary. Exceptions would include a machete injury to the skull producing a linear skull fracture with underlying dural laceration and brain damage.

A comminuted fracture occurs when multiple linear fractures radiate from the point of impact. Some of the fracture lines may involve the suture lines (diastatic fracture) or may stop at them. Around the point of impact there may be free fragments of bone. If the skin is closed, and no depression of bone fragments greater than the thickness of the skull is demonstrated on CT, management is as that for linear skull fractures. However, in many of these cases, surgery is performed for the underlying intracranial injury, such as an epidural hematoma. After the intracranial injury has been corrected, the bone fragments are primarily replaced as a bone cranioplasty after cleaning.

Missing bone can be replaced with a titanium mesh screen. If the skin is open, and free bone fragments are present, cleansing or débridement of the contaminated fragments is performed, before dural and scalp closure. Bone too contaminated may be discarded, and a titanium screen is then used to span the bone defect.

In a depressed skull fracture, the greatest bone depression can occur at the interface of fracture and intact skull or near the center of the fracture if several fragments are displaced inward. Impacted fractures may be “wedged” into position by blocked bone edges.

Some patients with depressed skull fractures experience initial loss of consciousness and neurological damage owing to the force transferred from the impact through the skull and into the brain. However, 25% of patients experience neither loss of consciousness nor neurological deficit. Another 25% of patients experience only brief loss of consciousness. Although the diagnosis of a depressed skull fracture is often indicated on routine skull radiographs by an area of double density (overlying bone fragments) or by multiple or circular fractures, the full extent and depth of injury are rarely appreciated with a CT scan. Physical examination is more difficult in the presence of scalp mobility and swelling. Scalp mobility can result in nonalignment of the sheared layers of the scalp or a scalp laceration and can therefore simulate, under palpation, the sense of a skull fracture; normal skull under a scalp laceration also does not exclude a depressed fracture 1 or 2 cm from one edge of the laceration.

Furthermore, post-traumatic swelling of the scalp minimizes the palpable and visual appearance of the step-off at the bony edges, preventing accurate clinical assessment of the extent of skull deformity or displacement for the first few days. CT is the diagnostic method of choice. When image display windows are adjusted to optimize bony detail, they display the position, extent, and number of fractures as well as the presence and depth of depression. With the imaging windows set to optimize intracranial contents, the same CT scan also allows assessment of the underlying brain for contusion or hematoma, small bone fragments, or foreign bodies as well as other intracranial trauma. Occasionally, coronal CT images through fractures near the vertex of the head or extending into the skull base are used to supplement the standard CT images, because the depth of a depression is more accurately measured on CT images perpendicular to the depression.

Depressed skull fractures over a venous sinus require special handling. Surgical elevation of these fractures may involve massive blood loss if a depressed fragment has been plugging a sinus tear. There are two strategies for management. The fracture can be carefully elevated, attempting to gain control of the venous sinus as soon as possible, preparing for significant transfusion requirements. If the fracture site is not grossly contaminated with foreign material, or will not cause a major cosmetic or functional deformity, or not cause intracranial hypertension secondary to sinus occlusion, such fractures are managed with scalp debridement alone and irrigation, followed by serial CT scans for signs of brain abscess for at least a year. A delayed cranioplasty may then be required for contour. The management of these fractures requires both judgment and experience as no definite rules apply to the variation of presentations.

This case is a compound elevated and depressed skull fracture over the superior sagittal sinus with epidural hematoma and cerebral prolapse. This is a complicated and very rare variant of skull fractures. The mechanism of this trauma was motor vehicle accident with direct impact on parietal bone. High velocity and small point impact probably are the cause of the fracture. The bone fracture may ruptured some vessel, or bleeding from skull diploe thus caused the epidural hematoma, it also tear the underlying dura thus some brain tissue prolapsed through. We performed early surgical intervention to prevent further complications like intracranial sepsis. All bone fragments has been removed and the dural laceration was patched with pericranium without manipulation on cerebral prolapse. Due to unstable cranial vault and the bone defect, we decided to perform cranioplasty using 100 mm x 100 mm titanium mesh. We also performed broad antibiotic therapy (Ceftriaxone 1gr IV once daily, Gentamicin 80mg IV twice daily, and Metronidazole 500mg IV third times daily) for infection prevention [6-8]. Within the first day post-op, the patient already gain full consciousness and neurological deficits are fully diminished. Patient discharged after 7 days with good clinical condition and no sign of infection⁵.

Early surgical management on a compound elevated and depressed skull fracture over the superior sagittal sinus with epidural hematoma can give a better outcome. With a prolapsed brain tissue, especially in an eloquent area, neurological deficits can be minimize by avoiding any surgical intervention to the involved brain tissue. The usage of titanium mesh usually avoided in open wound due to high risk of infection but in this patient, with good wound care and broad spectrum antibiotics, unwanted complication can be avoided.

References

1. S Kalayanaraman (1996) Scalp and Skull Injuries. In: Textbook of Neurosurgery. (Ed.) Churchill Livingstone New Delhi 289.
2. Geisler FH (1996) Skull fractures. In: Wilkins RH, Rengachary SS, (eds). Neurosurgery Vol II. New York, McGraw Hill 2741-2754.
3. Ralston BL(1976) Compound elevated fractures of the skull. Report of two cases. J Neurosurg 44: 77-79.
4. Verdure J, White RJ (1976) Compound elevated skull fractures. J Neurosurg 45: 245.
5. Geisler FH, Rodrigues E, Manson PN (2012) Traumatic Skull and Facial Fractures. In: Principles of Neurological Surgery 3rd edition. Philadelphia, Elsevier Saunders 365-369.

6. Zacko C, Harris L, Bullock R (2011) Surgical Management of Traumatic Brain Injury. In: Winn R. Youmans: Neurological Surgery 6th edition. Philadelphia; Elsevier Saunders 3424– 3451.
7. Cooper P (1993) Depressed Skull Fracture. In: Apuzzo M editor. Brain Surgery. New York: Churchill Livingstone 1273–1282.
8. Bullock R, Chestnut R, Ghajar J, Gordon D, Hartl R, et al. (2006) Surgical Management of Depressed Cranial Fracture. Neurosurgery S2-56 – S2-60.

Copyright: © 2016 Sendjaja AN, et al. This is an open-access article distributed under the terms of the Creative Commons Attribution License, which permits unrestricted use, distribution, and reproduction in any medium, provided the original author and source are credited.

Citation: Sendjaja AN, Sutiono AB, Faried A, Arifin MZ (2016) Open Depressed and Compound Elevated Skull Fracture over the Superior Sagittal Sinus: A Case Report. J Surg Surgical Res 2(1): 001-004. DOI: 10.17352/2455-2968.000020