

Farid Yudoyono*, Agung Budi Sutiono
and M Zafrullah Arifin

Department of Neurosurgery, Faculty of Medicine,
Universitas Padjadjaran–Dr. Hasan Sadikin
Hospital, Bandung, West Java, Indonesia

Dates: Received: 23 December, 2015; Accepted:
25 January, 2016; Published: 27 January, 2016

***Corresponding author:** Farid Yudoyono, MD,
Department of Neurosurgery, Faculty of Medicine
Universitas Padjadjaran–Dr. Hasan Sadikin Hospital,
Jl. Pasteur No. 38, Bandung 40161, Indonesia.
Tel: +62222041694; Fax: +62222041694; E-mail:
faridense@gmail.com

www.peertechz.com

ISSN: 2455-2968

Keywords: Calvarial Osteomyelitis; High voltage
electrical injuries; Scalp flap

Research Article

High-Voltage Electrically Head Injury Presenting underlying Calvarial Osteomyelitis: Single Indonesian Tertiary Hospital Experience

Abstract

Objective: To demonstrate the characteristic of high-voltage electrically head injury patients presenting underlying calvarial osteomyelitis.

Methods: Retrospectively report of patients high-voltage electrically head injured with calvarial osteomyelitis from January 1st 2011 to December 31st 2013. The demographic variable namely age, sex, place of accident, present of calvarial osteomyelitis, Glasgow coma scale, surgical treatment type, grading of burn injury and total body surface area of burn (TBSA).

Results: Eleven high-voltage electrically injured patients presenting with calvarial osteomyelitis, who admitted to the Emergency Unit Department of Neurosurgery Hasan Sadikin Hospital, All patients were males (100%). Their ages ranged between 24 and 51 years (average 23,7 years old) All patient (100%) suffered from calvarial osteomyelitis. Eight patient (77,7%) were high building worker at the time of incident, two patients were electric installation worker (18,18%). Entry point of electric wave 11 patients (100%) from head and outlet 11 patients (100%) from leg.

Conclusion: Bone debridement in calvarial osteomyelitis is a difficult to treat infectious disease with a high relapse risk, cure is possible with appropriate treatment choices. Antibiotic treatment will provide more benefit if it is combined with appropriate and timely surgical treatment for both scalp and calvarial.

Introduction

Electrically head injured are extremely rare and pose a difficult challenge for neurosurgeon, Electrical injuries account for less than 5% of admissions to major burn centers. The mortality is reported to be between 3% and 15%, with about 1000 deaths a year in the United States attributed to electrical injury [1-4]. The disability of electrotrauma depends not only the nature of the voltage current (DC or AC), but also the length of exposure, location and contact resistance of different tissues. Electrotrauma is divided between higher (>1000 volts) and lower (1000 volts) voltage injuries [1,2,5]. High-voltage (>1000 volts) electrical current, it often causes deep scalp and calvarial burns when enters into the body from the head present serious challenges in early and late stages of healing, underlying dura and cerebrum may be severely injured; moreover, neurological deficits caused by intracranial hemorrhage leading to loss of consciousness, sensory and motor deficiencies may occur. No difference management but cerebral involvement are more devastating and frequently end with a destructive condition [6].

Osteomyelitis is an infection process accompanied by bone destruction caused by a microorganism [7]. The incidence is on the rise in developing countries because of malnutrition, poor

socioeconomic conditions, and immunodeficiency syndromes [8], and also due to preexisting infectious focus, Local vascular insufficiency or hematogenous spread. The treatment involves a surgical and long term antibiotics for causative agent [9].

Methods

Retrospectively report of high-voltage electrically head injured with underlying calvarial osteomyelitis from January 1st 2011 to December 31st 2013. Demographic information and the mechanism of injury complications, hospitalization period, surgical interventions and grading of burn injury and total body surface area of burn (TBSA) were recorded. Incomplete records and patients who had left the Hospital with written consent before the termination of their treatment course were excluded from the study (Table 1).

Criteria for surgical procedures were high-voltage electrically head injured patients with underlying calvarial osteomyelitis who do not fulfill these criteria for admission are treated in the outpatient clinic until healing of their burn wounds or becoming ready for grafting.

Results

Eleven adult patients (11 males) were managed for high-voltage electrically head injured with underlying calvarial osteomyelitis

Tabel 1: Patient Demographic.

Age (years old)	Sex	Profession	Inlet †	GCS*	Skull X ray	Outlet ‡	Wound care (days)**	Treatment	Grading	TBSA (%) ***2
24	male	high building worker	head	15	osteomyelitis+ SCI L1-2	leg	14	Craniectomy debridement + Skin Flap	IIA-B	30
30	male	high building worker	head	15	osteomyelitis	leg	11	Craniectomy debridement + Skin Flap	IIA-B	4
32	male	high building worker	head	15	osteomyelitis	leg	loss follow Up††	Craniectomy debridement + Skin Flap	IIA-B	40
51	male	high building worker	head	15	osteomyelitis	leg	15	Craniectomy debridement + Skin Flap	IIA-B	5
32	male	electric instalation	head	15	osteomyelitis	leg	loss follow Up††	Craniectomy debridement + Skin Flap	IIA-B	38
30	male	electric instalation	head	15	osteomyelitis + Epidural Abscess at Vertex	leg	14	Craniectomy debridement + Skin Flap	IIA-B	40
45	male	accidental	head	15	osteomyelitis	leg	loss follow Up††	Craniectomy debridement + Skin Flap	IIA	39
45	male	high building worker	head	15	osteomyelitis	leg	45	Craniectomy debridement + Skin Flap	IIA-B	34
33	male	high building worker	head	15	osteomyelitis	leg	loss follow Up††	Craniectomy debridement + Skin Flap	IIA-B	13
26	male	high building worker	head	15	osteomyelitis	leg	25	Craniectomy debridement + Skin Flap	II-III	13
27	male	high building worker	head	15	osteomyelitis	leg	loss follow Up††	Craniectomy debridement + Skin Flap	IIA	5

†inlet: port de entre of electric wave, ‡outlet: electric wave out from body, *GCS: Glasgow Coma Scale, **Wound care (days): open wound care during hospitalization, ††loss follow Up: forced discharged or loss follow up in outpatient clinic.
 ***TBSA (%): Total Body Surface Area: Area extent of burn injury.

All patients were males (100%). Their ages ranged between 24 and 51 years (average 23,7 years old) and the surface extent of burn ranged from 4 to 40% Total Body Surface Area (TBSA) average 23,72 %. Wound care average 15 days included 5 patient loss follow up caused by forced discharged due to financial problem and not controlled in outpatient clinic. GCS admission was 15 included one patient paraphrases caused by spinal cord injury. All patient (100%) suffered from calvarial osteomyelitis found radiographically or clinical assessment, Head CT scan not available for all patient due to limitation of insurance coverage. Eight patient (77,7%) were high building worker at the time of incident, two patients were electric installation worker (18,18%). Entry point of electric wave 11 patients (100%) from head and outlet 11 patients (100%) from leg.

Diagnosis of the type of electrical injury either as a low-voltage or a high-voltage injury was made according to the clinical examination and the history given by the patient, an attendant of the accident, or the medical report supplied by the medical facility that provided first aid management and/or transportation. Assessment of the type and depth scalp is confirmed subsequent debridements and dressing changes later intra-operatively during debridement.

Discussion

Electrical injuries account for less than 5% of admissions to major burn centers. The mortality is reported to be between 3% and 15%, with about 1000 deaths a year in the United States attributed to electrical injury [1,2,6]. Electrical burns remain an important issue in developing countries due to its higher prevalence and complications mortality rate reported in literature as high as 59% [6,7]. Electrotrauma is frequently caused by work-related accidents.

Handschin et al., show a large number of high voltage electrotrauma in connection with accidents at work (72%) [2].

Prolonged High-voltage electrical head injuries can be damage various types of tissue such as skin, subcutaneous tissue, muscles, nerves, tendons and blood vessels although rare calvarial destroys frequently both soft tissues and bony parts of the head and infection can occurs such as calvarial osteomyelitis on the inlet part (Figures 2A,B) [10,11].

Grading of burn injury divided to First degree includes only the outer layer of skin, epidermis usually appear red and very painful, Second degree divided into two partial thickness involve entire epidermis full thickness involve entire epidermis and most of the dermis with diminished sensation, third degree involve all layers of

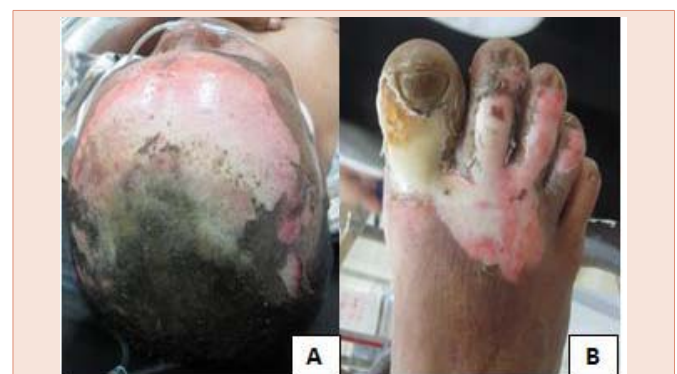

Figure 1: A Electric Source inlet on Vertex; B. Outlet Electric wave on pedis.

the skin are destroyed extends into subcutaneous tissue [13]. First degree usually treated conservatively and heals within 2-3 weeks by daily hydrotherapy and debridement with local application of silver sulfadiazine cream the most commonly affected site is scalp it seems to be due to the presence of a little amount of muscle fibers at the vault in compares to that present for example in extremities [13]. (Figures 1A,B).

The incidence of Calvarial osteomyelitis rising in developing countries because of malnutrition, poor socioeconomic conditions, and immunodeficiency syndromes. The basic approach for this treatment is surgery involves large debridement of necrotic bone and tissue because the ischemic nature and a vascularity of infected tissue, and the low oxygen level due to the presence of sequestra, cause inadequate penetration of antibiotics into the infected tissue, obtaining appropriate cultures, dead space management [9].

All patients have GCS 15 no neurological deficit during hospitalization so we do not use ICP monitoring for the patients. The management methods reported in the literature are divided into five groups: the first is primary or secondary closure using cancellous bone grafts. The second is filling dead tissue with antibiotic, followed by reconstruction. The third method uses local muscle flaps to control infection. The fourth method uses microsurgical techniques to make composite tissue transfers, thereby closing bone, muscle, and skin defects. Bone defects are closed using vascularized fibular grafts and osteocutaneous iliac flaps. The fifth method is the use of Ilisarov techniques to close bone defects. On our cases we use titanium mesh for closing calvarial defect after infection has been treated [9].

Limited partial-thickness defects of the scalp may be left to heal by secondary intention. However, significant contracture may result, and the scar may have limited or no hair growth. Larger partial-thickness defects, usually require repair. Patients with full-thickness scalp wounds should undergo some type of reconstructive surgery. Wounds occurring over hardware should be covered with well-vascularized flaps. Cranioplasty is performed to provide protective coverage of the intracranial contents and to restore cranial contour. If infection is present, the cranioplasty should be delayed until the infection has been treated [12].

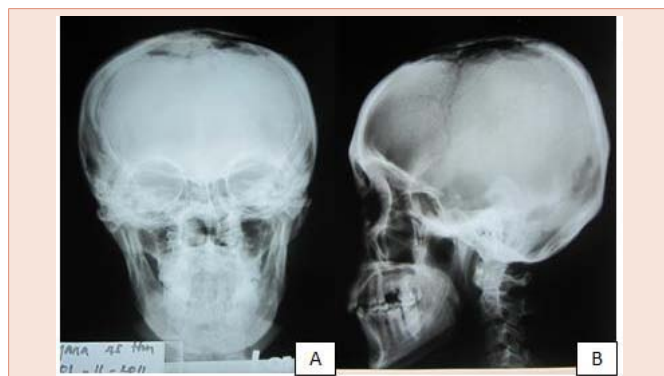

Figure 2: A) Anteroposterior radiograph demonstrates a large parietal lytic lesion B) Lateral radiograph shows large circumscribed lytic lesion in parietal bone.

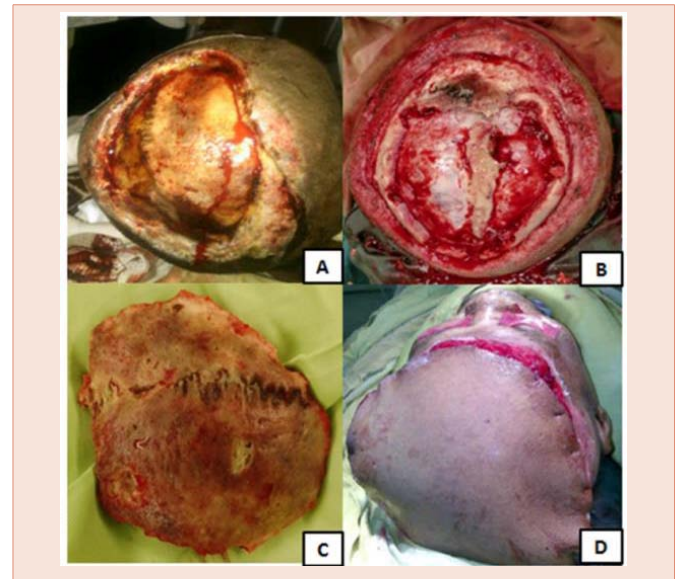


Figure 3: A) Intraoperation showed Osteomyelitis B) Epidural empyema on vertex C) Craniectomy osteomyelitis bone D) After Free Flap from latissimus dorsi.

All patient performed craniectomy by a neurosurgeon (Figures 3A, 3B). One of those patients was discovered intraoperatively to have a small extradural abscess underneath the resected bone which was evacuated adequately (Figure 3B).

Spinal cord injury after electrical injury may be due to the anatomical characteristics of the arterial blood supply to the anterior gray matter, especially anterior horn cell because blood is supplied only by the sulcal branch, the longest branch originating from the anterior spinal artery. So any occlusive event caused by vascular wall injury in the sulcal branch will enhance the risk of ischemic injury in its distal area. Furthermore, the spinal cord at T4 to T8 levels is more vulnerable to ischemic injury due to poor collateral circulations [13,14].

The average bone defects following craniectomy were 4 cm and 10 cm in diameter (Figure 3C). Bone wax was used to control the oozing from the resected and decorticated bone. Flaps were used for the coverage of scalp defects in all patients (Figure 3D). At the end of six month 10 patient have good wound healing and 1 patient has reoperation due to flap failed and then good wound healing next 8 month.

Conclusion

Bone debridement in calvarial osteomyelitis is difficult to treat and high relapse risk, cure is possible with appropriate treatment choices. Antibiotic treatment will provide more benefit if it is combined with appropriate and timely surgical treatment for both scalp and calvarial.

References

1. Ahmed AK, Nawres M (2006) Scalp Burns: Evaluation of Electrical Versus Thermal Scalp Injury. The Iraqi Postgraduate Medical Journal 5: 4.
2. Lipovy B, Kaloudova Y, Rihova H, Chaloupkova Z, Kempny T, et al. (2014) High Voltage Electrical Injury: An 11-Year Single Center Epidemiological Study. Ann Burns Fire Disasters 27: 82-86.

3. Makboul M, Abdel-Rahim M (2013) Simple flaps for reconstruction of pediatric scalp defects after electrical burn. *Chin J Traumatol* 16: 204-206
4. Kaif M, Singh Panwar D, Chandra A, Chandra N (2009) High-voltage electrical burn of the head: Report of an unusual case, *Indian Journal of Neurotrauma (IJNT)* 6: 163-164.
5. Lee J, Sinno H, Perkins A, Tahiri Y, Luc M (2010) 14,000 Volt Electrical Injury to Bilateral Upper Extremities: A Case Report. *Mcgill J Med* 13: 18-21.
6. Ghavami Y, Reza Mobayen M, Vaghardoost R (2014) Electrical Burn Injury: A Five-Year Survey of 682 Patients. *Trauma Mon* 19: e18748.
7. Soo Kim M (2012) Skull Osteomyelitis, Osteomyelitis, Prof. Mauricio S. Baptista (Ed.) 45-88.
8. Raut AA, Nagar AM, Muzumdar D, Chawla AJ, Narlawar RS, et al. (2004) Imaging Features of Calvarial Tuberculosis: A Study of 42 Cases. *AJNR Am J Neuroradiol* 25: 409-414.
9. Sümer S, Karamese M, Köktekir E, Ural O (2013) Chronic osteomyelitis of skull associated with necrotic injury after trauma: A case report. *Journal of Microbiology and Infectious Diseases* 3: 218-222.
10. N Gümüş (2012) Negative pressure dressing combined with a traditional approach for the treatment of skull burn. *Niger J Clin Pract* 15: 494-497.
11. Abd Al-Aziz H. Ahmad A, Al-Leithy I, Abu Alfotouh S (2004) Evaluation of the Treatment protocol of electrical injuries in Ain Shams University Burn Unit. *Egypt J Plast Reconstr Surg* 28: 149-158.
12. Samuel JL, Matthew MH, Roman JS (2008) Scalp and Calvarial Reconstruction. *Seminars in Plastic Surgery* 22: 281-293.
13. Ko SH, Chun W, Kim HC (2004) Delayed spinal cord injury following electrical burns: a 7-year experience. *Burns* 30: 691-695.
14. Johl HK, Olshansky A, Beydoun SR, Rison RA (2012) Cervicothoracic spinal cord and pontomedullary injury secondary to high-voltage electrocution: a case report. *J Med Case Rep* 6: 296.

Copyright: © 2016 Yudoyono F, et al. This is an open-access article distributed under the terms of the Creative Commons Attribution License, which permits unrestricted use, distribution, and reproduction in any medium, provided the original author and source are credited.

Citation: Yudoyono F, Sutiono AB, Arifin MZ (2016) High-Voltage Electrically Head Injury Presenting underlying Calvarial Osteomyelitis: Single Indonesian Tertiary Hospital Experience. *J Surg Surgical Res* 2(1): 010-013. DOI: 10.17352/2455-2968.000022