

Giorgio Maria Paul Graziano¹,
Carnazzo Santo², Samperisi Luigi² and
Antonino Graziano^{3*}

¹University of Catania Medical School, Italy

²Research University of Catania, Azienda, Policlinico, Italy

³University of Catania, Azienda, Policlinico, Department of Sciences Medical Surgery and advanced technologies "G Ingrassia", Italy

Dates: Received: 01 March, 2016; Accepted: 28 March, 2016; Published: 30 March, 2016

***Corresponding author:** Antonino Graziano, Department of Sciences Medical Surgery and advanced technologies "G Ingrassia", via S Sofia 86, Catania cap, 95125, Italy, E-mail graziano@policlinico.unict.it

www.peertechz.com

ISSN: 2455-2968

Keywords: Hernioplasty adenomectomy prostatic

Research Article

One Time Surgery in Contemporary Diseases of the Abdominal Wall and Pelvis in the Elderly

Abstract

Introduction: The diseases most frequently found in the elderly are E.I. (inguinal hernia)* and BPH. (Prostatic hypertrophy non-neoplastic)*. The latter causes an effect on the abdominal wall to the increase in abdominal pressure from cervical-urethral obstruction, leading to the onset of the inguinal hernia pathology due to abdominal pressure which is higher, the greater as the residual bladder urine. The purpose of the study is to provide information on the surgical strategy and on timing in the presence of the simultaneous two diseases.

Material and Method: Patients observed and joint treated were divided into two subgroups A (patients without) and B (patients with prosthetic implantation), with a mean age of 74 years. These patients accounted for 23% of the cases handled by hernioplasty and 49% of treated cases of BPH. The surgical treatment performed for joint pathologies in the two groups was that of a Pfannestiel single super-pubic incision extending on the projection of the inguinal ligament. In a first stage is performed a prostatic adeno-myomectomy sec Frayer, and subsequently an hernioplasty (prosthetic and do not).

Results: The complications (seroma, hematoma) represented 10.6% of group A patients. In group B patients' complications attested to only 6% of cases, without a significant increase in complications or therapeutic failure, or a prolongation of hospital stay which was an average of 4 days and of 2 days in group A and B respectively. Early recurrent hernia, episodes that usually occur in the immediate postoperative period (prosthesis mobilization, throttling of the spermatic cord, etc.), we observe only 1% in group B, while present in 3% of patients in group A without affixing the prosthetic material. Finally the follow-up, implemented for a period of 24 -36 months to two groups, was sufficiently adequate for the purposes of a detection of possible late complications or relapses.

Discussion: The affixing of the prosthesis thanks to the continuous evolution of materials and improved surgical technique favors the consolidation of early hernioplasty and the further reduction of the relapse rate. The simultaneous treatment of the two diseases in terms of satisfaction in patients treated has produced excellent results. Patients with only one operating session are not exposed to additional risks both anesthesia, and surgical, still burdened by complications

Conclusions: The treatment of joint diseases EI ((inguinal hernia) and BPH (prostatic hypertrophy non-neoplastic) meets a great liking to the patient, for the adoption of a single analgesia to allow the implementation of both interventions in same day. Anatomical incision detects any non-clinically significant hernias, or unmask.

Introduction

The most frequent pathologies in patients in geriatric age are the EI (inguinal hernia)* and I 'BPH (benign prostatic hypertr3ophy)*. Codest diseases reach the highest incidence after age 60 [1] and in that decade of age do it takes a high hit statistical Office of the contemporaneity of the two diseases [2,3]. The feature pathophysiology is characterized by the association of the two diseases caused by a part to increased endo abdominal pressure required to overcome the resistance of the obstruction cervical -urethral, the other to an alteration of the aponeurotic wall structures with a progressive decrease of the resistance of tissues [4]. The other most significant aspect is anatomically indicating a favorable joint treatment of diseases. Implemented the even more widespread surgical option are deferred treatment (12 months) of the two diseases, but in relation to 'analysis of our experience you can make a joint surgical treatment.

The purpose of this paper is to define the directions to an open question which is that of timing in the presence of contemporaneity of the two diseases.

Materials and Methods

Patients seen in Codest study and referred to the Joint treatment and two groups were divided;

A) The 1983-93 group I Patients seen at the Surgical Clinic II Hospital Garibaldi Catania are No 68, No 46 of these were treated with adenomectomy trans bladder and hernia repair, the other No. 22 with TUR-P (Trans urethral resection prostatic) and hernioplasty

B) The group II 1994-2004 observed patients No 73 at the Surgical Clinic III Hospital Policlinico, and from 2004 to 2014 are n 71 at the Department of specialized surgical sciences II Policlinico Catania.

Of these 103 cases undergo adenomectomy trans bladder and hernia repair, the remaining n 41 with a TUR-P (transurethral resection prostatic) and hernioplasty. l 'age was between 65-90, with a mean age 74. The risk factors were: cardiovascular diseases, age. Metabolic diseases (diabetes, kidney failure,, obesity, BPCO (chronic obstructive pulmonary disease). Such patients taken under observation accounted for 23% of all cases of EI (inguinal hernia) treated, and 49% of cases of BPH (benign prostatic hypertrophy) observed and operated at the Department of specialized surgical sciences II. The treatment is in the first group was made a spinal anesthesia in 90% of cases and in the remaining 10% of patients was carried out under general anesthetic. In Group II the spinal anesthesia was performed in all patients, and in the few cases (8 cases. 5.5%) in which the anesthetic technique had a shorter duration we proceeded with the prosthetic hernioplasty with

loco regional anesthesia. The surgical treatment for joint pathologies made in the two groups was that of a suprapubic incision extending sec Pfannenstiel incision on the projection of the inguinal ligament see (Figures 1,2)

Then in the surgical treatment the first time you make a prostate adenomectomy sec Frayer century, and later in a subsequent prosthetic hernioplasty sec Bassini (33%),sec Postempsky (67%) performed in the period 1983-93, sec Trabucco (20%), sec Lichtenstein (20%), sec Stoppa (60%) and performed in the period 1994-99, sec Shouldice (34%), sec Robbins and Ruskow (67%) predominantly from 2000-14, taking care to prevent contamination of the prostheses. in group B. In recent intervention, the surgical procedure was preceded by a study to define, through eco and in some cases a CT examination, prostate size, its structural aspects, the evaluation of the post urinary bladder residue, in order to attribute a etiopathogenetic role to stressed urinary flow in determining the hernia pathology in Figure 3 shows the anatomical site where it develops the inguinal hernia, easily reached with the engraving illustrated.

Results

In the two groups (A,B) of patients treated, we evaluated multiple complications, length of stay. Initially were evaluated complications. In group a represented 10.6% (seroma, hematoma), while in group B due to the improvement of surgical techniques and the application of prosthetic material, complications were present in only 6% of cases. In all patients there was not a significant risk of treatment failure (relapse, or loosening of the prosthesis, or strangulation of the cord). Complications observed have not then engraved on the prolongation of hospital stay that was on average 4 days for group A and 2 days for group B, until the introduction of the DAY Surgery. The presence of risk factors has led to a greater focus on monitoring the postoperative course leading to a prolongation of the antibiotic therapy and of thrombo embolic prophylaxis, as well as an increase in average 1-day hospital stay. (10% of cases). The hernia early recurrence episodes that usually occur in the immediate post operating had a lower incidence of 3% in group A versus 1% in group B. The incidence was significantly higher in patients of group A, without affixing the prosthetic material. Finally, the follow-up was implemented for a period of 24 -36 months for the two groups, we got a response in 93% of cases, sufficiently adequate for the purpose of a statistical survey of late complications.

Discussion

In patients receiving surgical treatment, the significant fact that we found is as the removal of the obstacle urinary flow associated with a strengthening of the band with the affixing of prostheses, has resulted in a reduction of hernia recurrence, especially in patients in group B. This indicates that the removal of the intra-abdominal pressure is effective and able to prevent recurrences hernias [5]. The affixing of the prosthesis thanks to the continuous evolution of materials and improved surgical technique, developing enhanced early hernia repair and the further reduction of the relapse rate. The simultaneous treatment of the two diseases in terms of satisfaction in patients treated has produced excellent results. Patients with one time interventions are not exposed to additional risks. Both

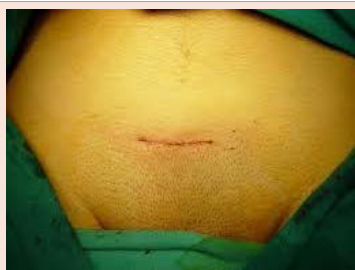

Figure 1: Suprapubic incision.

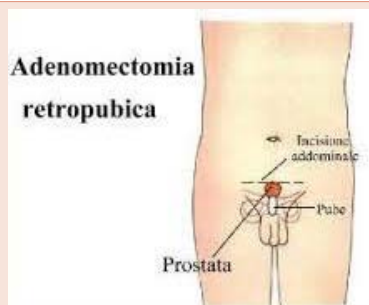

Figure 2: Anatomical position.

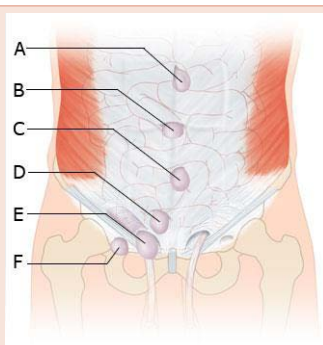


Figure 3: Seat possible hernias.

anesthesia, and surgical treatment, are still burdened by early and late complications [6]. Relatively to anesthesia, latter lasted as to permit the performance of both interventions, and in the few cases (4%) in which the anesthesia period was reduced by an insufficient optimal dosage of the drug, the hernia repair was implemented in local anesthesia with an excellent tolerance. Finally spinal anesthesia has reduced the use and consumption of drugs for postoperative pain treatment. The surgical technique allows, through a Pfannenstiel incision, to eliminate both inguinal incision and aponeurosis section, so reducing the trauma of the abdominal wall (Figures 1,2). For the prostate adenomectomy, the pre-peritoneal via is preferred, and allows the assessment of the presence of a bladder stress with detrusor hypertrophy. This anatomical status ease the tight closure of the bladder making it possible to reduce the risk of pollution of infectious urine filtration next hernia repair [7]. Bladder catheterization also work so. In cases where there are no conditions for a watertight closure of the bladder was necessary to defer hernia repair in a second stage, with the inguinal access [8,9], in order to reduce the risks related the infective contact between urine filtration and affixed prosthetic material. Finally in contemporary TUR-P and inguinal surgery, were implemented all the surgical techniques of prosthetic hernia-plastic by inguinal incision with considerable success and tolerability. In those patients undergoing TUR-P (in I and II and III stage BPH)* you can predict the onset of recurrent hernia because the removal of the adenoma may be incomplete (small tablet of prostate tissue remains in situ in order to avoid major complications, such as perforation dl rectum). This tablet prostate tissue grows over time bringing the patient to a new urethral stenosis with subsequent urinary retention, with a new hypertrophy of the detrusor and increase in abdominal pressure. The use of new technologies such as laser that vaporizes the prostate hypertrophic tissue allows in this group of patients to be able to hope for a definitive solution of the diseases. Last but not least, especially in case of bilateral hernias, both diseases may be treated totally via endoscopic techniques: laparoscopic the hernias, cistoscopic the benign prostatic hypertrophy.

* BPH benign prostatic hypertrophy

* EI Inguinal Hernia

* TUR-P Trans urethral resection prostatic

Conclusions

The removal of cervical-ureteral obstruction due to the presence of BPH has advantages in terms of efficiency because it prevents both the hernia formation and complications. The intervention of prostatic adenomectomy is that this is done by trans-bladder or in TUR-P and contemporary hernia repair eliminates the risks associated with a second surgical procedure. Also noted is a reduction in the health and social costs. The treatment of joint disorders IH and BPH

meets a great liking to the patient, with a significant effect due to the duration of a single analgesia to allow the implementation of both interventions. It is believed that the success of this surgical procedure may find wider acclaim for the purposes of an evaluation with a more extensive series. In this field new laparoscopic and cistoscopic techniques may give other contributes.

References

- Vagnoni G, Graziano A (1993) Trattamento congiunto dell'IPB ed ernia inguinale Atti VII congress naz. Soc Ital. Chir.Geriatria Roma 22-24 sett 1: 623-625.
- Ventrex ST (2015) Studio multicentrico su un nuovo device per l'ernia ombelicale" Congresso Nazionale SIC (Società Italiana di Chirurgia) – Milano.
- (2012) Double Sided Mesh in Umbilical Hernia Repair, Hernia Repair 2012, atti congresso congiunto American Hernia Society (AHS) e European Hernia Society (EHS).
- Cholewicki J, Ivancic PC, Radebold A (2002) Can increased intra-abdominal pressure in humans be decoupled from trunk muscle co-contraction during steady state isometric exertions? Eur J Appl Physiol 87: 127-133.
- Cramer SO, Malangoni MA, Schulte WJ, Condon RE (1983) Inguinal hernia repair before and prostatic resection. Surgery 94: 627-630.
- González-Ojeda A, Marquina M, Calva J, Mendoza A, de la Garza L (1991) Combined inguinal herniorrhaphy and transurethral prostatectomy. B J Surg 78: 1443-1445.
- Warren LP, Appling S, Oladehin A, Griffin J (2001) Effect of soft lumbar support belt of abdominal oblique muscle activity in nonimpaired adults during squat lifting. J Orthor Sports Phys Ther 31: 316-323.
- Richardson CA, Snijders CJ, Hides JA, Damen L, Pas MS, et al. (2002) The relation between transverses abdominis muscles, sacroiliac joint mechanics and low back pain. Spine 7: 399-405.
- (2012) Studio prospettico sull'utilizzo di reti leggere in polipropilene con tecnica tension-free sutureless. Unità e valore della Chirurgia Italiana, atti del primo congresso Nazionale- Roma 23-27.
- Graziano A (2008) Risk factor for hernia after gastroplasty. Acta Chirurgica Mediterranea 24: 5-7.
- (2015) Original two components prosthesis for inguinal hernia repair. First World Conference on Abdominal Wall Hernia Surgery, Congresso congiunto A.H.S. e E.H.S.
- (2015) Using a three-dimensional bit soft plug (PT2/3-H3) in polypropylene for primitive crural hernia and recurrent inguinal hernia: Preliminary experience, Poster Session – 1st World Conference on Abdominal Wall Hernia Surgery, Milano 25-29.
- (2014) Inguinal hernia repair in young sport men Video session, 36th Annual International Congress of the EHS – Edimburg, Scotland, Maggio.
- Graziano A (2007) Bilateral spigelian hernia treated by double mesh. Acta Chirurgica Mediterranea 1: 51-52.
- Cavallaro A, Lauretta A, Pennisi S, Lizzio A, Cavallaro M (2005) Complication in day surgery hernia repair using mesh. Chirurgia 18: 111-113.
- Graziano A, Giovanni Castelli - Giorgio M. Paolo Graziano (2010) Foramen of Winslo W hernia. Acta Chirurgica Mediterranea 26: 81-83.

Copyright: © 2016 Paul Graziano GM, et al. This is an open-access article distributed under the terms of the Creative Commons Attribution License, which permits unrestricted use, distribution, and reproduction in any medium, provided the original author and source are credited.

Citation: Paul Graziano GM, Santo C, Luigi S, Graziano A (2016) One Time Surgery in Contemporary Diseases of the Abdominal Wall and Pelvis in the Elderly. J Surg Surgical Res 2(1): 018-020. DOI: 10.17352/2455-2968.000024