



**Gabriel Carneiro Fernandes Fonsêca<sup>1\*</sup>, Marcelo Gonçalves Sousa<sup>2</sup>, Rômulo Gioia Santos Júnior<sup>1</sup>, Gabriela Albuquerque Batista de Araújo<sup>2</sup> and Marcelo Moura Linhares<sup>3</sup>**

<sup>1</sup>Faculdade de Medicina Nova Esperança, Brazil

<sup>2</sup>Hospital Universitário Lauro Wanderley, Universidade Federal da Paraíba, Brazil

<sup>3</sup>Universidade Federal de São Paulo, Brazil

**Received:** 23 April, 2019

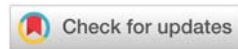
**Accepted:** 28 May, 2019

**Published:** 29 May, 2019

**\*Corresponding author:** Gabriel Carneiro Fernandes Fonsêca, Faculdade de Medicina Nova Esperança, João Pessoa, Brazil, Tel: +55 83 99302-6421; E-mail: gabrielcfernandesf@hotmail.com

**Keywords:** Ampulla of vater; Adenocarcinoma; Duodenal neoplasms

<https://www.peertechz.com>



## Case Report

# Mixed Adenoneuroendocrine Carcinoma of the Ampulla of Vater

## Abstract

**Introduction:** In 2010, World Health Organization defined mixed adeno-neuroendocrine carcinoma as rare tumor with two malignant components: neuroendocrine and adenocarcinomas. A rare mixed adenoneuroendocrine carcinoma of the ampulla of Vater was diagnosed in this report.

**Methods:** Diagnosis, surgery and follow-up performed at the Surgical Clinic Service of the Lauro Wanderley University Hospital, from November 2017 to March 2019. Authorized by the patient and approved by the Ethics and Research Committee.

**Results:** in the current english literature there are only 22 published cases until now. Ampullary carcinoma has been sub classified into 4 categories based on the exact location and such location has distinct prognostic factors. There are three types of morphology according to the distribution of the exocrine and endocrine component: amphicrine, mixed and collision. The mixed type is the most common and present in this case. Diagnosis before the surgery is difficult due to the predominance of non-specific symptoms and because the rarity of the tumor. The surgery is the first line therapy and, after radical resection, adjuvant therapy must be considered, focusing on the more aggressive histology type.

**Conclusion:** Periampullary mixed adenoneuroendocrine carcinoma are infrequent tumors, diagnosed after resection and immunohistochemical analysis. There isn't standardization in the management of this disease yet. It is necessary to publish the reported cases for the development of treatments.

## Abbreviations

MANEC: Mixed Adenoneuroendocrine Carcinoma

## Introduction

In 2010, World Health Organization classified the mixed adenoneuroendocrine carcinoma (MANEC) as a tumor whose two malignant components are morphologically recognized: neuroendocrine and glandular epithelial cells. By definition, its constitution has at least 30% of each histological lineage of tumor [1].

MANEC's are uncommon neoplasms that usually appears in the stomach, colon/rectum and pancreas. Therefore, periampullary presentation is atypical and less widespread in the scientific community [2,3].

This study identified a rare case of MANEC in duodenal papilla topography. The clinical presentations, histopathogenesis, epidemiology, forms of diagnosis and treatment are not well described in the literature, only a few cases have been reported, therefore, there is no standardized or officially recommended treatment.

The purpose of this article is to expand medical knowledge, bringing to the fore a report of this singular neoplasia in order to promote future studies.

## Case Presentation

A man of 70 years-old was admitted to the clinic with fever, progressive jaundice, pale stools, five months of right hypochondriac pain and loss of weight (7 kg/15,4 lbs) in a short period of three months. No history of diabetes mellitus and none report of symptoms compatible with carcinoid syndrome.

At admission, pancreatic enzymes, as the tumor markers, present a normal analytic behavior. The abdominal computed tomography with contrast showed dilatation of intra and extrahepatic biliary tract, distended gallbladder, a dilation of the Wirsung duct - associated with an ill defined and hypodense area in the uncinate process - and, last but not the least, doesn't show the presence of lymph node enlargement (Figure 1).

The magnetic resonance cholangio-pancreatography shows a common bile duct of 1.8 cm, showing a severe tapering

of its distal segment, concomitant with the concentric parietal thickening. The pancreas with significant diffuse ectasia of the main and secondary pancreatic duct, measuring up to 0.8 cm, with an important tapering at the papilla level (Figure 2). In the upper digestive endoscopy, the duodenal papilla appeared bulging, protuberant, with a tumor aspect and hardened consistency, yet with a functional drainage.

In view of these findings, compatible with resectable disease, it was suggested to the patient a pancreaticoduodenectomy - with lymphadenectomy of chains 8 and 9 -, a peri-pancreatic and a peri-hilar. The presence of a tumor mass in higher papilla topography, hardened, without apparent local dissemination, free of mesenteric vessels, portal vein or hepatic artery (Figure 3). The reconstruction, performed in single-loop, with a pancreatojejunostomy duct-to-mucosa (5 mm), without use of plastic catheter. At the postoperative phase, the patient's clinical condition evolved uneventfully, followed by a hospital discharge on the 5th postoperative day and with drainage withdrawal without biliary fistula.

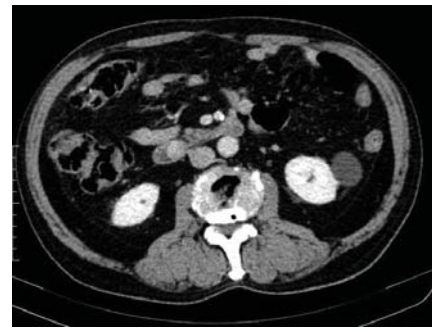In the macroscopic analysis we found an elevated lesion, with a cream-greyish aspect, with 1.8x1.5x0.8cm of measure, in a topography of duodenal papilla. The microscopic analysis showed a malignant neoplasm of epithelioid pattern and solid-trabecular arrangement infiltrating the duodenal papilla with free surgical margins; 1 mitosis / 10 fields; and no angiolymphatic invasion, but with perineural infiltration. There was no neoplastic infiltration in the peripancreatic and pancreatic adipose tissues, nor in the underlying duodenal. Peripancreatic lymph nodes without compromise (0/5).

The immunohistochemical analysis showed a pattern of adenoneuroendocrine mixed carcinoma with infiltrative lesion up to the submucosa. The exocrine component was of glandular origin with well differentiated mucinous tubular areas - with greater depth of invasion - and little differentiated solids with signet ring cells. The neuroendocrine component was of solid pattern with a positive reaction to synaptophysin, chromogranin A, CDX-2, CK20, CK7 and mucinous antigens. Ki-67 positive in 20% of the cells (Figure 4). In addition to that, was noted the presence of micro metastasis in the lymph node adjacent to the lesion with clustering of up to five epithelioid cells in the intranodal lymphatic sinus.

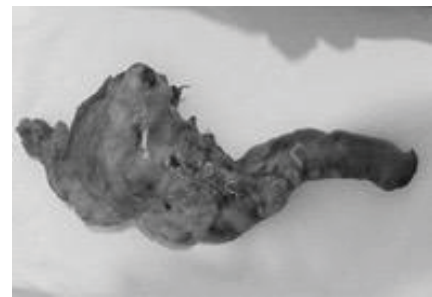
In the follow-up, was indicated a chemotherapy with capecitabine and oxaliplatin, protocol opted due to a good action against gastrointestinal adenocarcinomas; that may also be used for neuroendocrine tumors. The patient evolved with good tolerance to the proposed treatment and has been follow-up for one year and two months without any interurrences nor signs of recurrence of disease.

## Discussion

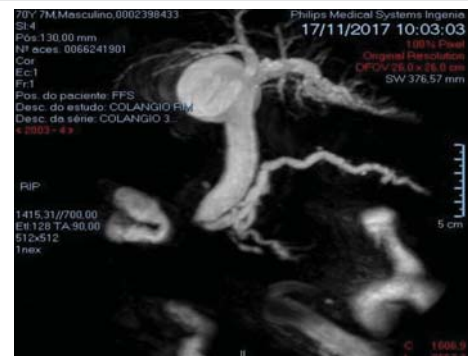Periampullar tumors are classified in 4 categories according to the location: intra-ampullar (limited to ampulla of Vater), Ductal-ampullar (biliopancreatic duct), duodenal-periampullar (exophytic growth for the duodenal lumen and minimal ampullar growth) and no exact location in the ampulla



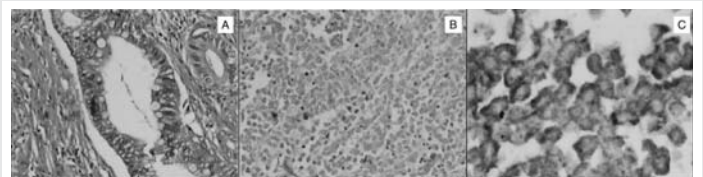
**Figure 1:** Computed tomography shows dilations of the intra- and extrahepatic biliary tract, an ill-defined and hypodense area in the uncinate process with a tumor in the duodenal papilla obstructing the bile duct (arrowhead).



**Figure 2:** Magnetic resonance cholangio-pancreatography exhibits dilatation of the biliary tree, common bile duct measuring approximately 1.8 cm in its largest diameter and important tapering of its distal segment.



**Figure 3:** Macroscopic view of the surgical part of a pancreaticoduodenectomy.



**Figure 4:** A: Haematoxylin and eosin stain. B: Immunohistochemical reaction to Chromogranin A. C: Immunohistochemical reaction to Synaptophysin.

(mixed involvement of the duodenum, intra-ampullary and biliopancreatic) [4].

Mahansaria et al published a series of 22 cases, whose distributions of periampullar MANECs are: intra-ampullar in 18% (4/22), duodenal-periampullar in 27% (6/22) and non-localized in the ampulla in 55% (12/22) [5]. In this case, the tumor was in a duodenal periampullar position. The location

is linked to distinct prognostic factors, the best subtype is the intra-ampullar and the worst subtype is the non-specific locus of ampulla [6].

There are several theories about histopathogenesis. Mahansaria et al. defends three types of morphology according to the distribution of components exocrine and endocrine: amphicrine, mixed or combined and collision. Type anficrine arises from early stem cells that proliferate the neoplasm before they differentiate into exocrine and endocrine cell lines. The presentation mixed is the most common and it is present in the case in question, in which components neuroendocrine and exocrine are already intimately mixed. The collision type shows a separate neuroendocrine and exocrine part, with a mixed central zone [5]. Chang et al still adding the solitary concomitant type and multiple concomitant type to the classification. The first shows a single tumor composed by endocrine and exocrine components distinctly separated by a fibrous band between these two parts. The last one contains simultaneously isolated endocrine and exocrine parts [7].

The preoperative diagnosis of MANEC is difficult due to the of nonspecific symptoms such as abdominal pain, nausea, vomiting, discomfort epigastric, jaundice and most of the patients do not present carcinoid syndrome, as a present case. The radiological findings areno specific, even the previous endoscopic biopsy, because the removal of small areas may not cover all the components of the tumor [5]. The confirmation of the diagnosis depends on histopathological analysis and immunohistochemistry after surgery as occurred in the case in question [4,8].

Due to the few cases reported in the literature, there is no consensus about the subject and, therefore, the clinical behavior is uncertain. At the present, it is defined that surgical intervention is the first line of treatment for cases with resectable tumors. After radical resection, multimodal treatment with adjuvant radiotherapy and/or chemotherapy should be done. Lee et al have proposed that treatment should be focused on the more aggressive cell type. It is believed that the glandular component, rather than of the neuroendocrine component, seems to be the main driving force of disease progression [4,8-17].

## Results

After the procedure, the patient evolved without interurrences, performing laboratory examinations and tomographies, demonstrating the positive result of the surgical technique. The patient is still being follow up by the Gastroenterlogy Service of Lauro Wanderley University Hospital.

## Conclusion

Periampullar MANEC's are rare tumors. They are diagnosed after resection and immunohistochemical analysis. There is no literature about the standardization of their management, because of their histology origin, as well as the low prevalence, which makes it difficult to establish diagnosis and the best

treatment, thus justifying the publication of the identified cases to develop future studies.

## References

1. Bosman F, Carneiro F, Hruban RH, Theise ND (2010) WHO classification of tumours of the digestive system. World Health Organization 3. [Link: https://tinyurl.com/yb8cousq](https://tinyurl.com/yb8cousq)
2. Max N, Rothe A, Langner C (2016) Mixed adenoneuroendocrine carcinoma of the ampulla of Vater: A case report. *Molecular and Clinical Oncology* 5: 95-98. [Link: https://tinyurl.com/y4slosn9](https://tinyurl.com/y4slosn9)
3. Kourie H, Ghorra C, Rassy M, Kesserouani C, Kattan J (2016) Digestive neuroendocrine tumor distribution and characteristics according to the 2010 WHO classification: a single institution experience in Lebanon. *Asian Pacif Journal of Cancer Prevention* 17: 2679-2681. [Link: https://tinyurl.com/y3pg3b3c](https://tinyurl.com/y3pg3b3c)
4. Zhang Q, Lu C, Zhang X, Ma Z, Xin Q, et al. (2015) Neuroendocrine Neoplasms of the Major Duodenal Papilla With Focus on Histopathological Features and Prognosis. *Int J Surg Pathol* 23: 433-438. [Link: https://tinyurl.com/y4rg9kef](https://tinyurl.com/y4rg9kef)
5. Mahansaria S, Agrawal N, Arora A, Bihari C, Appukuttan M, et al. (2017) Ampullary Mixed Adenoneuroendocrine Carcinoma: Surprise Histology, Familiar Management. *Int J Surg Pathol* 25: 585-591. [Link: https://tinyurl.com/y6e226du](https://tinyurl.com/y6e226du)
6. Adsav V, Ohike N, Tajiri T (2012) Ampullary region carcinomas: definition and site specific classification with delineation of four clinicopathologically and prognostically distinct subsets in an analysis of 249 cases. *Am J Surg Pathol* 36: 1592-1608. [Link: https://tinyurl.com/y3dj2l2d](https://tinyurl.com/y3dj2l2d)
7. Chang S (2010) Solitary concomitant endocrine tumor and ductal adenocarcinoma of pancreas. *World Journal of Gastroenterology* 16: 2692-2697. [Link: https://tinyurl.com/y2gkzezh](https://tinyurl.com/y2gkzezh)
8. Zhang L, DeMay R (2014) Cytological features of mixed adenoneuroendocrine carcinoma of the ampulla: Two case reports with review of literature. *Diagnostic Cytopathology* 42: 1075-1084. [Link: https://tinyurl.com/y5wrthcf](https://tinyurl.com/y5wrthcf)
9. Lee HH, Jung CK, Jung ES, Song KY, Jeon HM, et al (2011) Mixed exocrine and endocrine carcinoma in the stomach: a case report. *J Gastric Cancer* 11: 122-125. [Link: https://tinyurl.com/y46a7km4](https://tinyurl.com/y46a7km4)
10. Imaoka K, Fukuda S, Tazawa H, Kuga Y, Mochizuki T, et al. (2016) A mixed adenoneuroendocrine carcinoma of the pancreas: a case report. *Surgical Case Reports* 2: 133. [Link: https://tinyurl.com/y4gxonzk](https://tinyurl.com/y4gxonzk)
11. Kaji K, Seishima J, Yamato M, Miyazawa M, Komura T, et al. (2016) Clinical utility of endoscopic ultrasound-guided fine-needle aspiration in mixed adenoneuroendocrine carcinoma with signet-ring cells of the pancreas: a case report and review of the literature. *Clinical Journal of Gastroenterology* 9: 43-48. [Link: https://tinyurl.com/y4vx7ky](https://tinyurl.com/y4vx7ky)
12. Mori H, Hanada K, Minami T, Yano S, Fukuhara M, et al. (2018) A case of mixed adenoneuroendocrine carcinoma of the pancreas mimicking intraductal papillary mucinous carcinoma. *Clinical Journal of Gastroenterology* 11: 320-326. [Link: https://tinyurl.com/yyllozjy](https://tinyurl.com/yyllozjy)
13. Murata M, Takahashi H, Yamada M, Song M, Hiratsuka M (2018) A case of mixed adenoneuroendocrine carcinoma of the pancreas. *Medicine (Baltimore)* 96: e6225. [Link: https://tinyurl.com/y6ztgcm2](https://tinyurl.com/y6ztgcm2)
14. Soubra A, Faraj W, Saab J, Shamseddine A (2011) Peri-ampullary mixed acinar-endocrine carcinoma. *Rare Tumors* 3: e15. [Link: https://tinyurl.com/y45purb3](https://tinyurl.com/y45purb3)
15. Yoshioka S, Ebisu Y, Ishida M, Uemura Y, Yanagimoto H, et al. (2018) Cytological features of mixed adenoneuroendocrine carcinoma of the



ampulla of Vater: A case report with immunocytochemical analyses. Diagnostic Cytopathology 46: 540-546. [Link: https://tinyurl.com/y4mqcvvb](https://tinyurl.com/y4mqcvvb)

16. La Rosa S, Marando A, Sessa F, Capella C (2012) Mixed Adenoneuroendocrine Carcinomas (MANECs) of the Gastrointestinal Tract: An Update. Cancers (Basel) 4: 11-30. [Link: https://tinyurl.com/y4zjbn3r](https://tinyurl.com/y4zjbn3r)

17. Huang Z, Xiao W, Li Y, Huang S, Cai J, et al. (2015) Mixed adenoneuroendocrine carcinoma of the ampulla: Two case reports. World Journal of Gastroenterology 21: 2254-2259. [Link: https://tinyurl.com/yy2ooymv](https://tinyurl.com/yy2ooymv)

### Discover a bigger Impact and Visibility of your article publication with Peertechz Publications

#### Highlights

- ❖ Signatory publisher of ORCID
- ❖ Signatory Publisher of DORA (San Francisco Declaration on Research Assessment)
- ❖ Articles archived in worlds' renowned service providers such as Portico, CNKI, AGRIS, TDNet, Base (Bielefeld University Library), CrossRef, Scilit, J-Gate etc.
- ❖ Journals indexed in ICMJE, SHERPA/ROMEO, Google Scholar etc.
- ❖ OAI-PMH (Open Archives Initiative Protocol for Metadata Harvesting)
- ❖ Dedicated Editorial Board for every journal
- ❖ Accurate and rapid peer-review process
- ❖ Increased citations of published articles through promotions
- ❖ Reduced timeline for article publication

**Submit your articles and experience a new surge in publication services**  
(<https://www.peertechz.com/submission>).

*Peertechz journals wishes everlasting success in your every endeavours.*

**Copyright:** © 2019 Fernandes Fonsêca GC, et al. This is an open-access article distributed under the terms of the Creative Commons Attribution License, which permits unrestricted use, distribution, and reproduction in any medium, provided the original author and source are credited.