

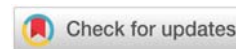


Received: 01 November, 2019

Accepted: 30 December, 2019

Published: 31 December, 2019

\*Corresponding author: Heinz Albrecht, MD, Department of Medicine 1, University Hospital Erlangen, Erlangen, Germany, E-mail: [heinz.albrecht@gmx.de](mailto:heinz.albrecht@gmx.de)

ORCID: <https://orcid.org/0000-0001-7456-1079><https://www.peertechz.com>

## Research Article

# Accuracy of the Full Spectrum Endoscopy (FUSE) system for assessment of disease activity in Inflammatory Bowel Diseases (IBD) compared to high-definition endoscopy

Heinz Albrecht<sup>1\*</sup>, Michael Vieth<sup>2</sup>, Gian Eugenio Tontini<sup>3</sup> and Helmut Neumann<sup>4</sup>

<sup>1</sup>Department of Medicine 1, University Hospital Erlangen, Erlangen, Germany

<sup>2</sup>Institute of Pathology, Klinikum Bayreuth, Bayreuth, Germany

<sup>3</sup>Gastroenterology and Digestive Endoscopy Unit, IRCCS Policlinico San Donato, San Donato Milanese, Italy

<sup>4</sup>First Medical Department, University Medical Center Mainz, Mainz, Germany

## Abstract

**Introduction:** Recently, Full Spectrum Endoscopy (FUSE) was introduced as a novel colonoscopy platform. In contrast to other endoscopy systems illumination with the FUSE system is achieved by Light-Emitting Diodes (LEDs) and not by a xenon light source. Currently, the FUSE-system does not provide high-definition imaging yet. In patients with IBD, precise assessment of disease activity (*i.e.* mucosal healing) is of paramount importance to predict disease outcome and to guide therapy.

**Aims:** To determine in a comparison study whether FUSE has the potential to assess disease activity in patients with IBD in comparison to a matched cohort of patients undergoing High-Definition White-Light Endoscopy (HD-WLE).

**Materials & methods:** Consecutive patients with IBD (n=34) undergoing FUSE colonoscopy were matched to patients with IBD undergoing HD-WLE at the same endoscopy unit. The mucosal vascular pattern and any mucosal abnormalities were recorded. Inflammation in ulcerative colitis was recorded according to Mayo Ulcerative Endoscopic Score (MUES) and in Crohn's disease according to Crohn's Disease Endoscopic Index of Severity (CDEIS). Subsequent to endoscopic characterization targeted biopsies were obtained for histopathological analysis of disease activity.

**Results:** 90 cases were included. Mean age of patients was 37 years (Range 18 to 72 years). 59% of patients had diagnosis of Crohn's disease and 41% diagnosis of ulcerative colitis. Accuracy of FUSE and HD-WL endoscopy for diagnosis of disease activity in IBD was not statistically significant different (83.8% versus 71.7%). The PPV and NPV for FUSE and HD-WLE did not differ significantly. In the subgroup analysis FUSE and HD-WLE endoscopy yielded in underdiagnosis and overdiagnosis of disease activity in 57% versus 46% and 43% versus 54% of not correctly predicted cases, respectively. Overall, FUSE was more accurate for diagnosis of disease activity in Crohn's disease patients, while HD-WL endoscopy was more accurate for diagnosis of disease activity in ulcerative colitis.

**Conclusion:** Despite the use of LEDs resulting in a darker image and high-resolution imaging, the FUSE seems to be equally effective to high-definition white-light imaging for diagnosis of disease activity in patients with IBD.



## Introduction

Inflammatory Bowel Diseases (IBD) comprise of two types of chronic intestinal disorders: Crohn's Disease (CD) and ulcerative colitis (UC) [1]. IBD is a worldwide health-care problem with a continually increasing incidence in western countries. Nevertheless, the major pathogenesis of IBD still remains unknown [2]. IBD affects approximately 1.4million Americans, and its peak onset is in persons 15 to 30 years of age, whereas the prevalence of IBD in Europe ranges between 27 and 48 patients per 100.000 people [3,4]. Endoscopic mucosal healing is nowadays preferred over clinical remission as a target therapeutic endpoint, because it has been demonstrated to reduce hospitalization and corticosteroid use, to reduce the risk of bowel resection, and to reduce the risk of colorectal cancer. Mucosal healing is also associated with sustained clinical response and improved quality of life [5]. Moreover, mucosal healing is not only a treatment target, but can also be used for the adjustment of medical therapies and to access therapeutic efficacy [6]. Therefore, in patients with IBD, precise assessment of disease activity (*i.e.* mucosal healing) is of paramount importance to predict disease outcome and to guide therapy.

In this context, the recent introduced SCENIC guidelines (*Surveillance for Colorectal Endoscopic Neoplasia Detection and Management in Inflammatory Bowel Disease Patients: International Consensus Recommendations*) strongly recommend the use of High-Definition (HD) white-light endoscopes for surveillance of patients suffering from IBD [7,8]. The strong recommendation was given according to the improved visualization and lack of negative effects with high-definition white light endoscopy.

Most recently, Full Spectrum Endoscopy (FUSE) was introduced as a novel colonoscopy platform providing a 330-degree field of view. In contrast to other endoscopy systems, illumination with the FUSE system is achieved by Light-Emitting Diodes (LEDs) and not by a xenon light source. By use of three imagers and LED groups positioned at the front and on the sides of the distal tip of the colonoscope a full-spectrum endoscopic view is achieved. Due to the technical parameters, the FUSE system does not provide HD imaging yet and the image may appear darker as compared to the one traditionally provided by xenon light sources. However, according to the LEDs used the contrast of the image is improved compared to commonly used xenon light sources.

Therefore, the aim of the present study was to evaluate in a comparison study the efficacy of the FUSE system compared to HDhigh-definition White-Light Endoscopy (WLE) for assessment of disease activity in patients with IBD.

## Materials and Methods

### Patients: screening, inclusion, and exclusion criteria

Between October 2013 and August 2014 34 consecutive patients with IBD undergoing FUSE colonoscopy were prospectively included and matched to patients with IBD undergoing HD-WLE in the endoscopy unit of the First

Department of Medicine at the University Hospital of Erlangen. Patient characteristics are shown in Table 1. Informed written consent was obtained from every patient before the procedure. The study was conducted according to the Declaration of Helsinki and has been approved by the local Ethics Committee at the University Hospital of Erlangen. Subjects were enrolled if they met the following inclusion criteria: more than 18 years of age, ability to provide written informed consent, and known colonic Crohn's disease or ulcerative colitis. Patients with one or more of the following criteria were excluded from the study: inability to provide written informed consent, severe uncontrolled coagulopathy, impaired renal function, pregnancy or breast feeding, active gastrointestinal bleeding, and residing in institutions. To avoid bias, the endoscopist was blinded to the results of previous colonoscopies. Also, the pathologists were blinded to the clinical and endoscopic findings.

**Table 1:** Patient characteristics.

Sex, n (%)	
Male	24(70.6)
Female	10(29.4)
Age in years, mean (range)	37(18 – 72)
Body mass index, mean (range)	24(17 – 33)
Extraintestinal manifestations of IBD, n(%)	
Arthritis	2(5.9)
Erythema nodosum	-
Pyoderma gangrenosum	-
Aphthous stomatitis	-
Iritis/uveitis	1(2.9)

### Endoscopic procedure, biopsy protocol and histological evaluation

Patients underwent a standard bowel preparation using either oral sodium phosphate or polyethylene glycol-electrolyte lavage solution. All colonoscopies were performed by expert endoscopists (more than 500 colonoscopies per year). FUSE colonoscopies were performed by using the newly introduced End Choice colonoscope that features cameras at the tip as well as on the sides of the scope providing your physician with a panoramic 330-degree field of view of the colon. HD-WLE was performed by using commercially available HD endoscopes (Pentax Medical, Tokyo, Japan). Thus, for the patient, the procedure was not different in both groups. Initially, the endoscope was advanced into the colon. On withdrawal, all parts of the colon were evaluated, and areas of inflammation were classified as followed: The Mucosal Vascular Pattern (MVP) and any mucosal abnormalities like rubor of mucosa, edema, granularity, and ulcerations were recorded. In ulcerative colitis, inflammatory changes were classified according to Mayo ulcerative endoscopic score that was modified from the Baron score for endoscopic severity. The scores were as follows: 0=normal or inactive disease; 1=mild disease (erythema, decreased vascular pattern, mild friability); 2=moderate disease (frank friability, marked erythema, absent



vascular pattern, erosions); and 3=severe disease (mucopus, spontaneous bleeding, and ulceration) [9]. In Crohn's disease, inflammatory changes were classified according to CDEIS that recorded the depth of ulcerations in each segment of the ileocolon and the surface of lesions and ulcerations on a 10-cm analog scale [10]. Prospectively, the following parameters were assessed during the endoscopic procedure: MVP and mucosal abnormalities were recorded in both groups, as previously described [11,12]. Furthermore, location (measured from the anus in centimeters) of any abnormalities was documented. Subsequent to endoscopic characterization targeted biopsies were obtained in a systematic fashion for histopathological analysis of disease activity. All biopsy specimens in both groups were placed in separate jars with exact labeling of location and macroscopic appearance. Biopsy specimens were fixed in 4% neutral-buffered formalin, embedded in paraffin, and sectioned in 4- $\mu$ m slides. Hematoxylin and eosin staining was used for histopathological examination. The pathologist was blinded to the endoscopic findings in each group and classified the inflammatory changes according to Riley, et al., into the following categories: mild inflammation, moderate inflammation, and severe inflammation [13]. The longitudinal extent of the inflammation in the colon was assessed by the presence of inflammation in the various sequential segments sampled. Finally, the histopathological findings were compared with the endoscopic assessment of disease activity in both groups.

## Statistics

Descriptive statistics were used to analyze patient demographics. The results were expressed as the mean or median (range). The Mann-Whitney U test was used for all continuous variables to determine whether differences between any two groups existed. A two-sided P value <0.05 was considered to be significant. For comparisons of proportions we used the chi-squared test. If the validity of the chi-square test was in question, the Fisher's exact test was used instead. All statistical analysis were performed using PASW Statistics 18 (SPSS, Inc., Chicago, USA).

## Results

To determine the potential of FUSE to assess disease activity and extent in IBD, a prospective study comparing FUSE with HD-WLE was performed. Overall, 34 patients with IBD were included in this study, 17 patients in the FUSE group and 17 patients in the HD-WLE group.

Overall, 90 cases were included. Mean age was 37 years (range 18 to 72years). 59% of patients had diagnosis of CD and 41% diagnosis of UC. Baseline characteristics such as age or gender did not significantly differ in both groups. The mean endoscopic activity index, based on the Mayo UC endoscopic score, was 1.41 in the FUSE group and 1.29 in the HD-WLE group. This difference was not statistically significant ( $p=0.8493$ ). Moreover, the mean CDEIS was not significantly different ( $p=0.7565$ ) between the FUSE group (6.94) and the HD-WLE group (5.25).

When comparing the endoscopic prediction of the extent of inflammatory activity with the histological results from the corresponding specimens, we found an overall accuracy of 83.8% in the FUSE group and 71.7% in the WLE-HD group ( $p=n.s.$ ). This means, that using the FUSE system, the endoscopists could predict more accurately the histologic result found by the pathologist. Overall, FUSE was more accurate for diagnosis of disease activity in CD patients, while HD-WLE was more accurate for diagnosis of disease activity in ulcerative colitis.

The Positive Predictive Values (PPV) were calculated as 83.3% for FUSE and 76.9% for HD-WLE, respectively in all cases. This signifies a higher probability (even if not statistically significant), that using the FUSE system an endoscopist could correctly predict the histological results and that the patient will truly have that specific disease extension.

On the other hand the negative predictive values (NPV) were calculated as 84.2% for FUSE and 66.7% for HD-WLE, respectively in all cases. This underlines again the higher capability of the FUSE system to correctly predict the final histology and to rule out false positive results (Table 2 for details).

Altogether FUSE is tending to more accurately predict the presence or absence of inflammation and its extension compared to HD-WLE.

In the subgroup analysis, FUSE and HD-WLE yielded in underdiagnosis of disease activity in 57% versus 46% and in overdiagnosis of disease activity in 43% versus 54% of not correctly predicted cases, respectively.

**Table 2:** Sensitivity, specificity, PPV, NPV and accuracy for the assessment of disease activity in IBD using FUSE compared to HD-WLE.

	Sensitivity	Specificity	PPV	NPV	Accuracy
<b>All cases:</b>					
FUSE	83.3%	84.2%	83.3%	84.2%	83.8%
HD-WLE	69.0%	75.0%	76.9%	66.7%	71.7%
<b>CD:</b>					
FUSE	87.5%	81.8%	77.8%	90.0%	84.2%
HD-WLE	58.8%	37.5%	66.7%	30.0%	52.0%
<b>UC:</b>					
FUSE	80.0%	87.5%	88.9%	77.8%	83.3%
HD-WLE	83.3%	93.8%	90.9%	88.2%	89.3%

CD: Crohn's Disease; CU: Ulcerative Colitis; PPV: Positive Predictive Value; NPV: Negative Predictive Value©

## Discussion

In the present study, we report for the first time on the accuracy of FUSE in comparison to HD-WLE for the assessment of disease activity in IBD. By directly comparing the results of FUSE and HD-WLE and subsequent histology of biopsy specimens, we observed that despite the use of LEDs resulting in darker image FUSE appears to be equally effective to HD-WLE for diagnosis of disease activity in patients with IBD.



Assessment of mucosal healing is of crucial importance for the management of IBD as it has been shown to reduce corticosteroid use, hospitalization and surgery. Accordingly, the recent introduced SCENIC guidelines strongly recommend the use of HD-WLE for surveillance of patients suffering from IBD [7,8].

The potential advantage of the FUSE system lies in the expanded field of view (330 degree for the colonoscope) resulting in previously unseen views, such as behind colonic and pyloric folds, and other difficult anatomy [14]. Multiple imagers make the panoramic view possible. One should also recognize that in the FUSE system LEDs illuminate the field of view, whilst the present standard light source for most endoscopes is a xenon based arc lamp, which emits a broad range of spectrum across the visible range which is very close to that of day light. The removal of the light fibers that are usually needed in standard endoscopes using xenon light sources creates more space that can be dedicated to the additional imagers in the FUSE system [14]. This sort of illumination results in a slightly darker illumination but with enhanced contrast compared to commonly used xenon light sources. This effect is mainly caused by the lower output of light of LEDs as compared to xenon light sources, but on the other hand LEDs have the advantage of adjusting to relative intensities which enables contrast enhancement what is beneficial for biological tissue imaging [15]. Lee AC, et al., concluded that the use of LEDs compared to xenon based arc lamps provide a more uniform illumination with sharper shadows, less flickering and better illumination for visual perception [16].

Using HD-WLE, the exact extent of inflammatory activity could be found with an accuracy of 71.7% compared to the histological results in the presented study. These findings are in accordance with other published data [4,12,17]. Compared to these findings, FUSE provides a slightly better overall accuracy (83.8%) in our study. The fact that FUSE was more accurate for diagnosis of disease activity in CD patients, while HD-WLE was more accurate for diagnosis of disease activity in ulcerative colitis needs to be further investigated. It can be speculated, that the use of LEDs might be of some help to improve the visualization of inflammatory mucosal changes, especially when a mild inflammation is present. Nevertheless, the assessment of FUSE for the determination of disease activity in IBD clinical practice still warrants further investigation. In addition, currently there is no reimbursement for advanced endoscopic imaging methods. Therefore, HD-WLE with multiple random biopsies still remains the standard for surveillance in patients with IBD, but it can be suggested that newer endoscopic techniques such as FUSE or the combination of several methods will improve our possibilities of disease surveillance. Potential limitations of our study should be acknowledged. First, all procedures were performed by one endoscopist what could introduce potential bias. However, our goal was to assess the accuracy of FUSE for the prediction of disease activity in IBD. Further prospective studies are needed to assess interobserver variation when the procedure is performed by community physicians or less-experienced endoscopists. Although use of one endoscopist

might create bias, this methodology has been the standard in many colonoscopy trials [18–20]. Use of the same endoscopist for both examinations has some advantages because they act as their own control with use of an identical withdrawal technique and baseline assessment. Second, differences in activity between endoscopy histology were directly assessed between both diagnostic modalities (*i.e.* severe on endoscopy and severe on histology = agreement). Third, another limitation of the current study is its design where patients undergoing FUSE colonoscopy were matched to patients undergoing HD-WLE. To overcome these issue upcoming studies could probably be performed as tandem colonoscopies.

In conclusion, precise assessment of disease activity in IBD is of paramount importance to predict disease outcome and to guide subsequent therapy. Several clinical, laboratory, and histological criteria for such an assessment have been proposed. Standard WLE represents the most commonly used mode of endoscopy in IBD surveillance and also recommended by the recently introduced SCENIC guidelines. Our study clearly indicates that the new FUSE system is equally effective to HD-WLE imaging for diagnosis of disease activity in patients with IBD. Illumination with LEDs, as it is implied in the FUSE system, does not affect image characterization for assessment of mucosal healing.

## References

1. Abraham C, Cho JH (2009) Inflammatory bowel disease. *N Engl J Med* 361: 2066-2078. [Link: http://bit.ly/36wexKW](http://bit.ly/36wexKW)
2. Zhang YZ, Li YY (2014) Inflammatory bowel disease: Pathogenesis. *World J Gastroenterol* 20: 91-99. [Link: http://bit.ly/2QRy6Xl](http://bit.ly/2QRy6Xl)
3. Loftus EV, Sandborn WJ (2002) Epidemiology of inflammatory bowel disease. *Gastroenterol Clin North Am* 31: 1-20. [Link: http://bit.ly/2tx2yhJ](http://bit.ly/2tx2yhJ)
4. Neumann H, Vieth M, Günther C, Neufert C, Kiesslich R, et al. (2013) Virtual chromoendoscopy for prediction of severity and disease extent in patients with inflammatory bowel disease: a randomized controlled study. *Inflamm Bowel Dis* 19: 1935-1942. [Link: http://bit.ly/2QTi3s1](http://bit.ly/2QTi3s1)
5. Ket SN, Palmer R, Travis S (2015) Endoscopic Disease Activity in Inflammatory Bowel Disease. *Curr Gastroenterol Rep* 17: 50. [Link: http://bit.ly/37EZSgA](http://bit.ly/37EZSgA)
6. Walsh A, Palmer R, Travis S (2014) Mucosal healing as a target of therapy for colonic inflammatory bowel disease and methods to score disease activity. *Gastrointest Endosc Clin N Am* 24: 367-378. [Link: http://bit.ly/2R576nF](http://bit.ly/2R576nF)
7. Laine L, Kaltenbach T, Barkun A, McQuaid KR, Subramanian V, et al. (2015) SCENIC international consensus statement on surveillance and management of dysplasia in inflammatory bowel disease. *Gastrointest Endosc* 81: 489-501. [Link: http://bit.ly/39NJJqU](http://bit.ly/39NJJqU)
8. Laine L, Kaltenbach T, Barkun A, McQuaid KR, Subramanian V, et al. (2015) SCENIC international consensus statement on surveillance and management of dysplasia in inflammatory bowel disease. *Gastroenterology* 148: 639-651. [Link: http://bit.ly/37ILHY2](http://bit.ly/37ILHY2)
9. Schroeder KW, Tremaine WJ, Ilstrup DM (1987) Coated oral 5-aminosalicylic acid therapy for mildly to moderately active ulcerative colitis. A randomized study. *N Engl J Med* 317: 1625-1629. [Link: http://bit.ly/37lcWBT](http://bit.ly/37lcWBT)
10. Mary JY, Modigliani R (1989) Development and validation of an endoscopic index of the severity for Crohn's disease: a prospective multicentre study. Groupe d'Etudes Thérapeutiques des Affections Inflammatoires du Tube Digestif (GETAID). *Gut* 30: 983-989. [Link: http://bit.ly/2SVdPD7](http://bit.ly/2SVdPD7)



11. Kiesslich R, Fritsch J, Holtmann M, Koehler HH, Stolte M, et al. (2003) Methylene blue-aided chromoendoscopy for the detection of intraepithelial neoplasia and colon cancer in ulcerative colitis. *Gastroenterology* 124: 880-888. [Link: http://bit.ly/2sSeRVL](http://bit.ly/2sSeRVL)
12. Kiesslich R, Goetz M, Lammersdorf K, Schneider C, Burg J, et al. (2007) Chromoscopy-guided endomicroscopy increases the diagnostic yield of intraepithelial neoplasia in ulcerative colitis. *Gastroenterology*. 132: 874-882. [Link: http://bit.ly/2ZWYmUj](http://bit.ly/2ZWYmUj)
13. Riley SA, Mani V, Goodman MJ, Herd ME, Dutt S, et al. (1988) Comparison of delayed-release 5-aminosalicylic acid (mesalazine) and sulfasalazine as maintenance treatment for patients with ulcerative colitis. *Gastroenterology* 94: 1383-1389. [Link: http://bit.ly/2N1y4Ln](http://bit.ly/2N1y4Ln)
14. Gralnek IM (2015) Evaluation of the EndoChoice full spectrum endoscopy (Fuse) platform for upper endoscopy and colonoscopy. *Expert Rev Med Devices* [Link: http://bit.ly/2sSVg7U](http://bit.ly/2sSVg7U)
15. Clancy NT, Li R, Rogers K, Driscoll P, Excel P, et al. (2012) Development and evaluation of a light-emitting diode endoscopic light source. *Proc SPIE 8214 Advanced Biomedical and Clinical Diagnostic Systems X*, 82140R. [Link: http://bit.ly/2R56min](http://bit.ly/2R56min)
16. Lee AC, Elson DS, Neil MA, Kumar S, Ling BW, et al. (2009) Solid-state semiconductors are better alternatives to arc-lamps for efficient and uniform illumination in minimal access surgery. *Surg Endosc* 23: 518-526. [Link: http://bit.ly/37FZT3W](http://bit.ly/37FZT3W)
17. Neumann H, Neurath MF, Mudter J (2011) New endoscopic approaches in IBD. *World J Gastroenterol* 17: 63-68. [Link: http://bit.ly/37H92sT](http://bit.ly/37H92sT)
18. Rex DK, Cutler CS, Lemmel GT, Rahmani EY, Clark DW, et al. (1997) Colonoscopic miss rates of adenomas determined by back-to-back colonoscopies. *Gastroenterology* 112: 24-28. [Link: http://bit.ly/35wTI0s](http://bit.ly/35wTI0s)
19. van Rijn JC, Reitsma JB, Stoker J, Bossuyt PM, van Deventer SJ, et al. (2006) Polyp miss rate determined by tandem colonoscopy: a systematic review. *Am J Gastroenterol* 101: 343-350. [Link: http://bit.ly/36wndRA](http://bit.ly/36wndRA)
20. Chen SC, Rex DK (2007) Endoscopist can be more powerful than age and male gender in predicting adenoma detection at colonoscopy. *Am J Gastroenterol* 102: 856-861. [Link: http://bit.ly/2ZUZyao](http://bit.ly/2ZUZyao)

### Discover a bigger Impact and Visibility of your article publication with Peertechz Publications

#### Highlights

- ❖ Signatory publisher of ORCID
- ❖ Signatory Publisher of DORA (San Francisco Declaration on Research Assessment)
- ❖ Articles archived in worlds' renowned service providers such as Portico, CNKI, AGRIS, TDNet, Base (Bielefeld University Library), CrossRef, Scilit, J-Gate etc.
- ❖ Journals indexed in ICMJE, SHERPA/ROMEO, Google Scholar etc.
- ❖ OAI-PMH (Open Archives Initiative Protocol for Metadata Harvesting)
- ❖ Dedicated Editorial Board for every journal
- ❖ Accurate and rapid peer-review process
- ❖ Increased citations of published articles through promotions
- ❖ Reduced timeline for article publication

**Submit your articles and experience a new surge in publication services**  
(<https://www.peertechz.com/submission>).

*Peertechz journals wishes everlasting success in your every endeavours.*

**Copyright:** © 2019 Albrecht H, et al. This is an open-access article distributed under the terms of the Creative Commons Attribution License, which permits unrestricted use, distribution, and reproduction in any medium, provided the original author and source are credited.

**Citation:** Albrecht H, Vieth M, Tontini GE, Neumann H (2019) Accuracy of the Full Spectrum Endoscopy (FUSE) system for assessment of disease activity in Inflammatory Bowel Diseases (IBD) compared to high-definition endoscopy. *Arch Clin Gastroenterol* 5(3): 034-038. DOI: <https://dx.doi.org/10.17352/2455-2283.000066>