

## Case Report

# A new method of placing nasogastric tubes in patients at high risk of epistaxis

Ilse M Novis<sup>1</sup>, Edward Le<sup>1</sup>, Hailey S Novis<sup>1</sup>, Karim Sorour<sup>1</sup> and Khaled A Sorour<sup>2\*</sup>

<sup>1</sup>Signature Healthcare Brockton Hospital, USA

<sup>2</sup>Senior Author, Critical Care Medicine, Harvard Medical School, USA

**Received:** 13 August, 2022

**Accepted:** 22 August, 2022

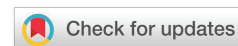**Published:** 23 August, 2022

**\*Corresponding author:** Khaled A Sorour, Senior Author, Critical Care Medicine, Harvard Medical School, USA, Tel: 5089417310; E-mail: [ksorour@signature-healthcare.org](mailto:ksorour@signature-healthcare.org)

**ORCID:** <https://orcid.org/0000-0003-3060-6057>

**Copyright License:** © 2022 Novis IM, et al. This is an open-access article distributed under the terms of the Creative Commons Attribution License, which permits unrestricted use, distribution, and reproduction in any medium, provided the original author and source are credited.

<https://www.peertechzpublications.com>



## Background

Nasogastric tubes are used for a multitude of purposes, however, due to their firm composition, they often injure the nasal passages when being placed. While a small amount of bleeding from the nasal mucosa is traditionally acceptable, that small amount of bleeding from the nose can potentially form thrombi that could compromise the airway in patients with impaired sensorium and swallowing. Furthermore, moderate or massive epistaxis is considered a medical emergency. The literature is silent on statistics about nasal bleeds from nasogastric tube attempts despite it being one of the common complications of nasogastric tube insertions.

One of the concerns of a risk of bleeding is with patients on anticoagulation, especially with the increased use of anticoagulants like Direct Oral Anticoagulants [DOACs] for stroke prophylaxis in atrial fibrillation and the treatment of thromboembolism. Additionally, the use of dual antiplatelet therapy in coronary artery disease has soared in the last decade. This brings into question the risk of insertion of a nasogastric tube in a patient using the above medications or even having a primary coagulation disorder or liver failure as incidence and the degree of epistaxis in these patients are perceived to be very high.

## Case description

A 51-year-old patient with schizoaffective disorder, cirrhosis, ascites, encephalopathy, pancytopenia, diabetes mellitus, hypertension, Barrett's esophagus, Gastric Antral Vascular Ectasia [GAVE] presented to the hospital with altered mental status. During their hospitalization, the patient

developed severe hematemesis, acute hepatic encephalopathy, and worsening abdominal distension. Computed tomography showed massive distension of the stomach, small bowel, and large bowel extending all the way to the rectum. To provide gastric decompression and to help alleviate the hematemesis, a nasogastric tube placement was attempted, however, multiple attempts to pass nasogastric tubes through her right and left nostrils failed due to the narrowing of the nasal passages. These attempts were complicated by severe epistaxis and aspiration pneumonia.

Lubricating the nasal passages and the nasogastric tube provided no benefits in our attempts to pass the nasogastric tube and attempts were continuously complicated by epistaxis. The only logical next step was to emergently intubate and sedate the patient and place an orogastric tube. However, before jumping to intubation of the patient, we attempted a new technique to pass the nasogastric tube without causing nasal trauma. We lubricated and carefully placed Nasopharyngeal airways, which are made of soft rubber, starting with a 28 French Nasopharyngeal airway [NPA], followed by a 30 French NPA, and then a 32 French NPA (Figure 1). Then, we lubricated the inside of the Nasopharyngeal airway and placed the 18 French nasogastric tubes through the 32 French NPA. The tube passed smoothly with no nasal injury. Then, we pulled out the Nasopharyngeal airway and left it mounted on the nasogastric tube outside the nose (Figure 2).

## Discussion

Risks of inserting a nasogastric tube include: tissue trauma; epistaxis; pneumothorax; sore throat; sinusitis; intracranial placement [1,2], tube dislodgement (48.5%); electrolytic

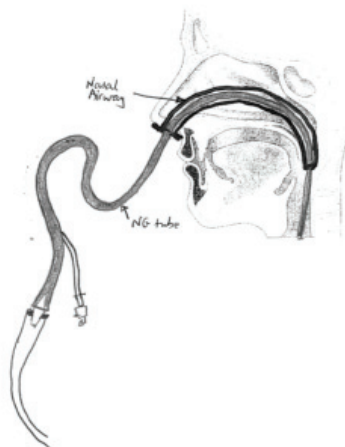


Figure 1: Nasogastric Tube in Nasopharyngeal Airway.

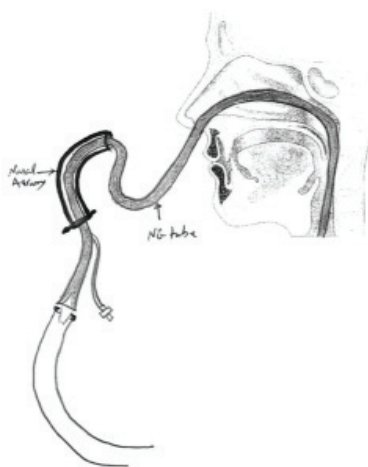


Figure 2: Nasopharyngeal Airway Mounted on Nasogastric Tube.

alterations (45.5%); hyperglycemia (34.5%); diarrhea (32.8%); constipation (29.7%); vomiting (20.4%); tube clogging (12.5%); and lung aspiration (3.1%) [3]. Nasogastric tube placement in unconscious patients in a neutral head position has a first attempt failure rate of nearly 50% [4]. According to literature, some common methods to increase the success rate of the nasogastric tube in unconscious patients are the use of a slit endotracheal tube, forward displacement of the larynx and the use of various forceps, the use of a ureteral guidewire as a stylet, head flexion, lateral neck pressure, and the use of a gloved finger to steer the nasogastric tube after impaction [5]. Our new method of placing a nasal gastric tube has not yet been described in the literature, nonetheless, we subsequently performed three such procedures on Intensive Care Unit patients.

We focused on mitigating the risk of tissue trauma, invasiveness, and epistaxis by first inserting a lubricated Nasopharyngeal airway and then dilating it until we

could effectively place the nasogastric tube through the Nasopharyngeal airway directly into the oropharynx. Unlike a nasogastric tube, because the Nasopharyngeal airways are compressible, tapered, and made of soft rubber, they did not cause any tissue trauma when they were carefully inserted and thus the patient's risk of epistaxis was mitigated. Of note, nasogastric tubes have smaller but firmer tips.

Research of published literature revealed that our method has not been done before and is a new and, potentially, successful method of interesting a nasogastric tube with fewer risks.

A potential drawback of our method is the inadvertent placement of the nasogastric tube into the larynx with literature stating that 2% of patients suffered from tube misplacement to the trachea [6]. That risk was identified pre-procedure and was mitigated by using short nasopharyngeal airways. Nasopharyngeal airway length is directly proportional to its width.

Ethical guidelines were followed. We used no patient identification in the manuscript.

## Conclusion

This new technique of placement of nasogastric tubes should be generalized and made available to be used in suitable patients to avoid nasogastric tube-induced epistaxis. More research should be conducted to determine its success rate and efficiency in placing a nasogastric tube.

## References

- Peter S, Di Milo AM. Nasogastric Tube Insertion. *Nasogastric Tube Insertion*. <http://www.med.uottawa.ca/procedures/ng/#:~:text=The%20main%20complications%20of%20NG,the%20case%20of%20this%20happening>.
- Contributor NT. *Nasogastric Tubes 2: Risks and Guidance on Avoiding and Dealing with Complications*. Nursing Times. 2021. <https://www.nursingtimes.net/clinical-archive/gastroenterology/nasogastric-tubes-2-risks-and-guidance-on-avoiding-and-dealing-with-complications-29-04-2009/>.
- Pancorbo-Hidalgo PL, García-Fernandez FP, Ramírez-Pérez C. Complications associated with enteral nutrition by nasogastric tube in an internal medicine unit. *J Clin Nurs*. 2001 Jul;10(4):482-90. doi: 10.1046/j.1365-2702.2001.00498.x. PMID: 11822496.
- Appukutty J, Shroff PP. Nasogastric tube insertion using different techniques in anesthetized patients: a prospective, randomized study. *Anesth Analg*. 2009 Sep;109(3):832-5. doi: 10.1213/ane.0b013e3181af5e1f. PMID: 19690254.
- Illias AM, Hui YL, Lin CC, Chang CJ, Yu HP. A comparison of nasogastric tube insertion techniques without using other instruments in anesthetized and intubated patients. *Ann Saudi Med*. 2013 Sep-Oct;33(5):476-81. doi: 10.5144/0256-4947.2013.476. PMID: 24188942; PMCID: PMC6074888.
- Motta APG, Rigobello MCG, Silveira RCCP, Gimenes FRE. Nasogastric/nasoenteric tube-related adverse events: an integrative review. *Rev Lat Am Enfermagem*. 2021 Jan 8;29:e3400. doi: 10.1590/1518-8345.3355.3400. PMID: 33439952; PMCID: PMC7798396.