

Clinical Image

Exclusive Image Gallery on Human Spinal Cord Regeneration

Giselher Schalow\*

MD, PhD, Untere Kirchmatte 6, CH-6207 Nottwil, Switzerland

Received: 22 May, 2019

Accepted: 15 June, 2019

Published: 16 June, 2019

\*Corresponding author: Giselher Schalow, Professor, Untere Kirchmatte 6, CH-6207 Nottwil, Switzerland, E-mail: [g\\_schalow@hotmail.com](mailto:g_schalow@hotmail.com)

<https://www.peertechz.com>

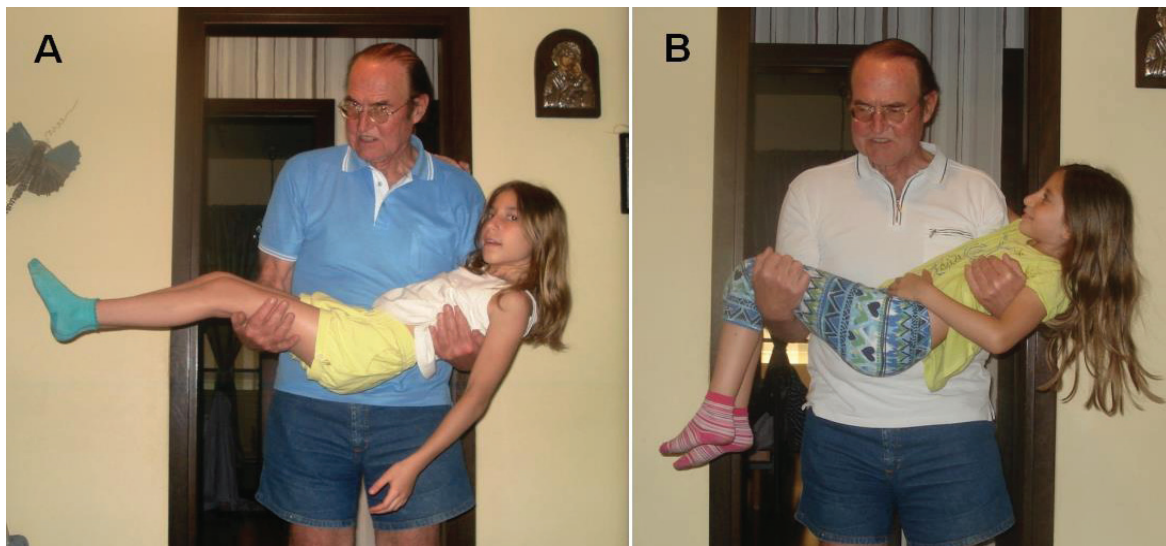


Figure 67: Practical judgment of extensor spasticity. When the Author holds the patient Nefeli (SCI Th10), one can judge her extensor spasticity by the extension of her legs (A). Her present spasticity is medium strong. A physiologic leg position can be seen in B. The healthy seven-year-old sister has no spasticity and the legs are flexed.

Copyright: © 2019 Schalow G. This is an open-access article distributed under the terms of the Creative Commons Attribution License, which permits unrestricted use, distribution, and reproduction in any medium, provided the original author and source are credited.