

Priyatam Khadka^{1*} and Ranju Kharel²

¹Department of Microbiology, Tribhuvan University Teaching Hospital (TUTH), Maharajgunj, Kathmandu, Nepal

²Assistant Professor and Uveitis Specialist, Department of Ophthalmology, Maharajgunj Medical Campus, B.P. Koirala Lions Centre for Ophthalmic Studies, Institute of Medicine, Tribhuvan University, Maharajgunj, Kathmandu, Nepal

Received: 04 April, 2019

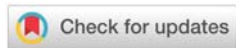
Accepted: 04 June, 2019

Published: 06 June, 2019

***Corresponding author:** Priyatam Khadka, Department of Microbiology, Tribhuvan University Teaching Hospital (TUTH), Maharajgunj, Kathmandu, Nepal, E-mail: khadka.priyatam@gmail.com

Keywords: *Mycobacterium tuberculosis*; Ocular tuberculosis; Clinical presentation; Diagnostic challenges; Uveitis

<https://www.peertechz.com>



Review Article

Ocular tuberculosis: Clinicopathologic assortment and diagnostic challenges

Abstract

Ocular tuberculosis is an exigent clinical entity—lacking a distinct clinical presentation and attributing the diagnostic conundrum. Nevertheless, the early-precise diagnosis with implicated anti-tubercular therapy may be sight-saving; diagnostic delays often encountered due to protean clinical presentations, the impracticability of obtaining tissue (in most case), limitation on sample volume extraction, and of wanting a sensitive diagnostic test. This article revises the current scenario of ocular tuberculosis, its clinicopathologic arrays, and diagnostic challenges for clinical management; Furthermore, advocates for compiling all such positive findings of corroborative tests in a precise diagnosis.

Epidemiology

Tuberculosis (TB) has subsisted for millennia and remains a foremost global health problem—one of the top ten cause of death worldwide. In reference to the Global TB reports 2017, approximately 10 million people get infected each year with tuberculosis [7]. Of the estimated number of incident cases, 64% of the totals were in seven countries: India, Indonesia, China, the Philippines, Pakistan, Nigeria, and South Africa; compiling 85% of total death only in South East region and Africa [7]. In Nepal, TB ranks 6th leading cause of death with an annual incident, 34,122 cases reported to NTP [8].

The incidence of ocular TB ranges from 1.4% to 5.74%; however, in an endemic region it may reach up 10% [4,9,10]. The exact epidemiological entity and per chance MDR/XDR ocular tuberculosis is unbeknownst, in Nepal. In a prospective study, 3.6% incidence was reported; nevertheless, drug-resistant ocular TB case is yet not reported [11].

Etiological agent

The main etiological agent of the ocular TB is *Mycobacterium tuberculosis*, or one of three related *Mycobacteria* species (sp. *bovis*, *africanum*, and *microti*). Referring the pathological features, bacterial cell wall consists of a high lipid content i.e mycolic acid; which in turn enriches the acid fastness character, and is responsible for multiplication and forming cell wall in host tissue [12]. Besides, there are approximately 4000 genes for immune system invasion and 200 extra-genomic set up for lipid metabolism; so, the pathogen is able to survive both inside and outside of the phagocytic cell [13].

Abbreviations

AFB: Acid-Fast Bacilli; ATT: Anti-Tubercular Therapy; ds DNA: Double-Stranded DNA; NAAT: Nucleic Acid Amplification Test; NTP: National Tuberculosis Programme; HSV: Herpes Simplex Virus, VZV: Varicella Zoster Virus, CMV: Cytomegalovirus

Background

Tuberculosis is a multisystem infectious disease that typically infects the lungs; extra-pulmonary organs including eyes are also prone to the infection, however. The infection by *Mycobacterium tuberculosis* in an eye, around the eye, or on its surface simply refers as ocular TB [1]. Usually, the infection is not coupled with clinical substantiation of pulmonary TB, as nearly 60% of extra-pulmonary TB cases may not have pulmonary TB [2]. The global statistic report on ocular tuberculosis, in the roof of extra-pulmonary TB, revealed the lower incidence compared to the pulmonary; however, poses arduous diagnostic challenges to the clinicians [3,4]. The clinical diagnosis of ocular tuberculosis is presumptive, in most cases; the clinicians are in conundrum—often made their diagnosis as probable and possible ocular tuberculosis—due to alike clinical presentation as those of eye infection with different etiology, relative paucity of the pathogen, and wanting sensitive diagnostic test [3,5,6].

Route of infection

The ocular TB can either occur as a primary active infection or a secondary infection from a distant site. The most frequent form of ocular involvement, however, is from hematogenous spread. Furthermore, some forms of ocular tuberculosis—phlyctenular disease and Eales' disease, are thought to be an outcome of a hypersensitivity reaction to the bacillus located elsewhere inside the body of the host [14].

Clinical presentation

Extra-ocular involvement: The acquisition of this form of infection occurs either by direct inoculations followed by hematogenous dissemination or via hypersensitivity reaction (15). The extra-ocular manifestations of TB appear on the external eye as a lid abscess or may manifest as chronic blepharitis or atypical chalazion [15].

Orbit: Tuberculosis involvement of the orbit presents either as proptosis to mass effect or diplopia from cranial nerve with involvement of extra-ocular muscles [16]. The clinical form is more common in children; the cases are being reported in adults too, nonetheless. The outer margin of orbit typically gets affected in the form of tuberculous periostitis; however, may manifest as cortical irregularities resulting in thickening and sclerosis of orbital bones [17,18]. A copious case of draining sinus tract and/or radiographic evidence of bony destruction—commonly in frontal, sphenoid, and zygomatic has been reported [9,16,17]. In an untreated case, the clinical form may, eventually, progress with extradural abscess formations, with characteristic caseating granulomas, soft tissue tuberculomas and diffused orbital involvement [16,18,19].

Lacrimal gland: The tuberculosis of lacrimal gland or tuberculous dacryoadenitis usually presents as a painless swelling of the eyelid, imitating either as dacryoadenitis of a bacterial entity or benign, mixed tumors of the lacrimal gland [9,15]. Therefore, diagnostic considerations or high index of clinical suspicions against masquerading infection is required also in cases that fail to responsive antimicrobial therapy.

Eye-lid: The TB on eye-lid may appear on the external eye as a lid abscess or as chronic blepharitis or atypical chalazion—the form usually predominant in children [14,15]. The skin of eyelids manifests as of lupus vulgaris—reddish-brown nodules that blanch to an “apple jelly” color when pressure is applied [14,15]. It has been presumed, the clinical form, most probable, is an extension of cutaneous tuberculosis, with characteristics sub-epithelial nodules, plaques, and ulcers [16].

Conjunctiva: The clinical forms, generally acquired via primary inoculation—either from external source, from eye-lids, or from secondary routes. Ocular redness, discomfort, mucopurulent discharge, and lid edema, are the most common clinical presentations [9]. Furthermore, marked lymphadenitis (subconjunctival nodule), pedunculated polyp, or tuberculoma are often seen; which is absent or less prominent in most other types of viral, bacterial and allergic conjunctivitis, however [9,14,15].

Sclera: Nearly 10.6% of infectious scleritis are resulted due to tuberculosis [20,21]. The clinical forms may be either localized or diffused; nonetheless, most cases are nodular [20,22]. The nodules or lesion eventually undergoes necrosis and scleral thinning [20,22]. These nodules are presumed as an outcome from hematogenous acquisitions; however, the direct inoculations or from the previous tubercular infection has also been reported [16].

Cornea: Corneal tuberculosis, the rare ophthalmic presentation, likely occur in a host, with the hypersensitivity to tuberculo-protein rather than the direct inoculation [23]. As an outcome, the non-specific clinical manifestations: interstitial keratitis, disciform keratitis, and phlyctenular keratoconjunctivitis may be seen [16].

Intraocular involvement

Progressively, intraocular TB is being recognized as a common cause of uveitis. The hematogenous spread is the primary mechanism; nevertheless, either by direct inoculations or via hypersensitivity reaction of tuberculo-protein, the intraocular TB can be acquired [24]. Almost, all intraocular segments of the eye gets affected: choroidal lesions such as focal, multifocal, or multifocal serpiginoid choroiditis (MSC), retinal lesions such as retinal vasculitis, optic nerve lesions such as optic disc granuloma or optic neuritis, and intermediate and anterior uveitis [24–27].

Uveitis: Tubercular uveitis is a great mimicker of various uveitis entity—Herpetic uveitis: HSV, VZV, CMV; ocular parasitosis: protozoa, nematodes, cestodes, trematodes, and ectoparasites; syphilis; ocular toxoplasmosis; ocular toxocariasis [28]. Therefore, owing to these masquerading entities, precise clinical diagnosis often misguided or deferred result a dire consequences.

Anterior uveitis: Tuberculous anterior uveitis usually presents as unilateral or bilateral chronic granulomatous disease appearing as large, mutton fat keratic precipitates (Figure 1), and occasionally hypopyon [29]. The clinical forms with the peculiarity-- broad-based posterior synechiae, less likely to have filiform synechiae of uveitis, unrelated to TB can be observed [5,24,26,29]. The presence of iris nodules, however, are important clues for the clinical diagnosis of uveitis of tubercular origin.

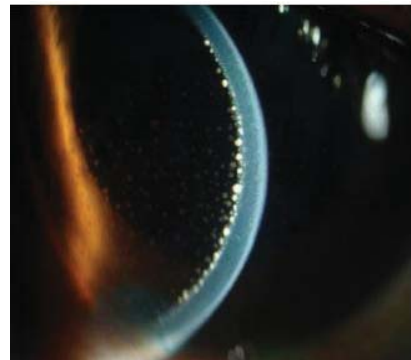


Figure 1: Granulomatous acute anterior uveitis showing multiple mutton fat keratic precipitates clustered over the endothelium in a presumed case of ocular TB.

Intermediate uveitis: In intermediate uveitis, resulting from intraocular tuberculosis, pars planitis generally gets stimulated. Besides, the low grade smoldering, vitritis, snowball opacities, snow banking, peripheral vascular sheathing and peripheral retinochoroidal granuloma are the common clinical manifestations in the patients [26,29].

Posterior and panuveitis: Posterior uveitis, the most prevailing clinical presentations of intraocular TB, comprises lesions which characteristically present in the choroid [30,31]. Of posterior uveitis, the multifocal or solitary posterior pole choroidal granuloma and choroiditis are the most common manifestations; however, the solitary or multiple choroidal nodules (tubercles), choroidal granuloma (tuberculoma), neuroretinitis, subretinal abscess, endophthalmitis, panophthalmitis, and retinal vasculitis are probable clinical spectrum [24,26,29].

a. Choroidal tubercles: The choroidal tubercles are more frequently observed, of reported intraocular manifestations, resulting from hematogenous seeding of the bacilli [32]. Clinically, the choroidal tubercles appear as small nodules—grayish white to yellow with indistinct borders—which continue to grow as a solitary mass i.e. tuberculomas [24,26]. As the infection resolves, the tubercles become pigmented throughout the peripheral margin leaving a characteristic atrophic scar (Figure 2).

b. Choroidal tuberculomas: The tuberculomas appear as large solitary mass and may be located anywhere in choroid—in the macula, posterior pole, equator, or in juxta-papillary locations [26]. Because of, its comparable size (4–14mm), and a characteristic exudative retinal detachment; clinician often made a clinical diagnosis either as tumors or infective abscesses [24].

c. Serpiginous-like choroiditis: The serpiginous choroiditis is a chronic inflammation of the choroid and choriocapillaries; which is recurrent and is believed to be immunogenic, rarely infective in origin [29]. It might present as multifocal lesions of choroiditis which progress in serpiginous pattern and then coalesce [24,26]. Furthermore, diffuses like a plaque centrifugally in amoeboid fashion. Despite, an administration of systemic corticosteroids and immunosuppressive drugs; the inflammation shows relentless progression for 4–6 weeks prior healing [24,26]. After a subsequent anti-tubercular treatment, the healed lesions do not recur, in general (Figure 3,4) [26].

d. Sub-retinal abscesses: The sub-retinal abscesses usually occur as an outcome of the liquefaction of caseating necrotic granulomas. The clinical forms may be associated with vitritis and retinal hemorrhages; had found commonly in the patient with disseminated tuberculosis [24,26,33].

Retinitis and Retinal Vasculitis

Tuberculosis from retina has been scarcely reported which may present as secondary choroiditis [34,35]. However, the retinitis and retinal vasculitis are more familiar with TB-associated intraocular inflammation than non-TB associated uveitis [24].

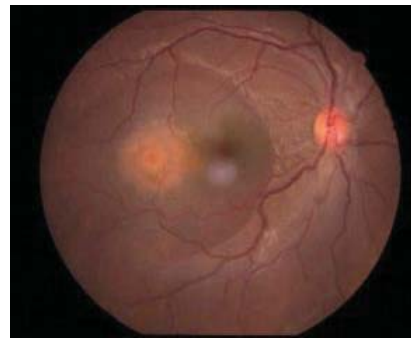


Figure 2: Fundus photograph of 23 years male patient showing a solitary posterior pole choroidal tuberculoma [31].

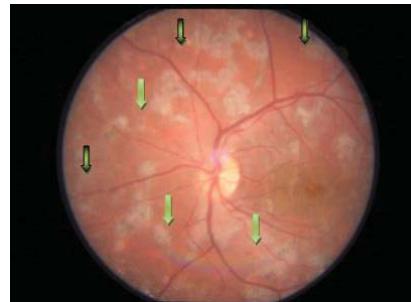


Figure 3: Left eye fundus showing multifocal active choroidal lesions – whitish and irregular margin (green arrow) and resolved choroidal lesions – pigmented and well-defined margin (black arrow) in the patient with Mantoux reading 28 mm and quantiFERON TB Gold test highly positive.

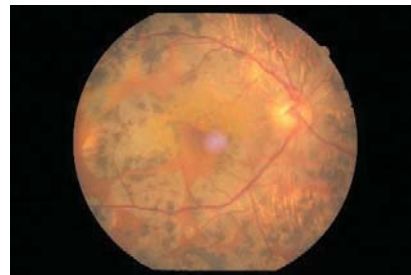

Figure 4: Right Eye Fundus picture in a case of serpiginous-like choroiditis showing healed lesions after treatment with ATT (anti-tubercular therapy) for 9 months. The patient has a positive Mantoux test (25mm). There was no recurrence noted after the start of ATT.

a. Retinal Vasculitis and other Retinovasculopathies: Retinal vasculitis classically presents as periphlebitis, with rare involvement of arterioles was noted. The clinical form is characterized by thick exudates around the retinal veins resulting in retinal hemorrhages and hemorrhagic infraction [28]. Furthermore, is associated with the mild degree of cellular infiltrates in the anterior chamber and mild vitreous infiltrate [30]. Besides, the proliferative vascular retinopathy with sequelae such as recurrent vitreous hemorrhage, traction retinal detachment, rubeosis iridis, and neovascular glaucoma may occur progressively [28].

b. Eales' disease: It has been presumed, either with the causative entity or form hypersensitivity reaction, the Eales' disease may have acquired; since the pathogen may or may not detected in the ocular sample [24,26]. Peripheral capillary nonperfusion, neovascularization,

recurrent vitreous hemorrhages, periphlebitis, and intraocular fibrovascular proliferation in a quiet eye are the principal characteristics of the Eales disease [24]. Besides, the associated systemic symptoms—epistaxis, peripheral circulation disorders, headache, constipation—has also been reported [26,29].

Endophthalmitis and Panophthalmitis

This clinical form of the disease characterized as the inflammation with intense, enough to produce hypopyon, filling the anterior chamber with purulent material [24,26]. As a result, to identify any granulomas and nodules from the iris surfaces, if present is difficult [26]. The intense inflammation of vitreous, in posterior segments, results in accumulation of large subretinal abscesses which may destroy Bruchs membrane [26].

The sclera, nevertheless, is also involved in panophthalmitis which eventually may result in globe perforation or scleral calcifications, in advanced form [36,37].

Neuroretinitis and Optic Neuropathy

Tuberculosis optic neuropathy and neuroretinitis may occur either with the direct inoculation, hematogenous seeding, and/or from the hypersensitivity reaction [5]. The optic nerve tubercle, papillitis, papilledema, optic neuritis, retrobulbar neuritis, neuroretinitis or opticochiasmatic arachnoiditis; are the common clinical spectrum of intraocular tuberculosis with nerve involvement [24,26,29].

Diagnosis of Ocular Tuberculosis and Existing Challenges

Differential clinical diagnosis

The accurate diagnosis is often radically, deferred, and delayed, as ocular TB is not routinely considered in the differential diagnosis due imitating clinical manifestations (Table 1) [9,14,16,20,24,27,28,38–45]. Hence, differential diagnosis is obligatory for successful clinical management and treatment of the infection.

Diagnosis of corroborative evidence

Tuberculin skin test (TST): Since epochs, the TST/Mantoux test has been used as a supplementary test in detection of a latent form of tuberculosis. Neither a positive TST necessarily indicates active infection nor negative TST rules out the infection persistence [46]. However, in a diagnostic armory of ocular tuberculosis, the role could not be outweighed [47–50]. The standard test involves an intradermal inoculation of 0.1ml of tuberculin and read after 48 to 72 hours; on positive interpretation, the indurations diameter exceeds measuring 10mm. It has been advocated that a previous history of BCG vaccinations should be ignored; through assessment of exclusion of active tuberculosis with the recommended test—AFB staining/culture/molecular assays of the samples (pulmonary and extra-pulmonary samples), chest X-ray—is mandatory prior beginning the treatment [51,52].

The sensitivity and specificity of the TST, in detection of ocular tuberculosis, is variable; probably due to the diverse endemicity of disease and clinical presentations. A literature search showing the sensitivity and specificity of TST, in the detection of ocular tuberculosis, as shown in (Table 2(i)).

Interferon-gamma release assay (IGRA): Two distinct in-vitro T cell based assays are available: Quantiferon-TB-Gold and T-SPOT-TB—relying upon MT specific antigen (ESAT6 and CFP10) [53]. Currently, Quantiferon-TB-Gold in-tube with an additional MT specific antigen TB7.7 to ESAT6 and CFP10 is summoned for greater specificity in diagnosis of a latent form of tuberculosis [54,55]. The IGRA rely upon a fact: T lymphocyte with exposure to a specific tubercular antigen release interferon-gamma (IFN γ)—considered positive on higher optical density with cut-off 1IU/ml (for ocular TB) [56].

IGRAs in the diagnosis of ocular TB has found more specific but less sensitive than TST (Table 2(ii)); however, in conjunction with TST higher sensitivity and specificity can be achieved [57].

Serodiagnosis: Serodiagnosis for detection of antibodies and antigens has been used for diagnosis of the ocular tuberculosis: Middlebrook-Dubos Test (based on detecting antibody after injecting live bacilli in aqueous humor; animal model) [58], ELISA (based on detecting cord factor of *Mycobacterium tuberculosis* as antigen) [59], antilipoarabinomannan (LAM)-B antibody titer [60]. The serological test owing to its lower sensitivity and specificities; nevertheless, not preferred currently as the diagnostic test.

Fundus photography, Fluorescein angiography, Indocyanine green angiography: The clinical signs or lesions present in the posterior segment, intermediate or panuveitis can be well documented with fundus photography [33]. Furthermore, the digital image, hence obtained, allows the grading of vitreous haze.

Fluorescein angiography can be useful in the diagnosis of several forms of intraocular tuberculosis. It can assists in differentiating tubercular retinal vasculitis with other forms of retinal vasculitis, by showing extensive capillary nonperfusion [33,61].

Indocyanine green angiography has a pivotal application for a diagnosis of disorder related to the choroid. On clinical application of the dye, does not leak from choroidal arteries or veins; however, slowly leaks from the capillaries—impregnating choroidal stroma [62]. The mechanism relies upon a diagnosis of intraocular tuberculosis which commonly affects choriocapillaries [63].

Fundus photography, Fluorescein angiography, Indocyanine green angiography collectively put on extra support in diagnosing the complications of TB uveitis, but rarely accepted as the primary diagnostic modality for the tubercular entity [15].

Ophthalmic ultrasonography: Ophthalmic ultrasonography—a noninvasive tool with instant, real-time feedback—is a primary diagnostic imaging modality for the eye, with nu-

Table 1: Possible clinical presentations of ocular tuberculosis and differential diagnosis.

| Ocular tuberculosis | Possible clinical presentations | Diagnostic considerations |
|-----------------------------|--|--|
| Extra-ocular tuberculosis | | |
| Orbit | presents in five forms: classical periostitis, orbital soft tissue involvement, and cold abscess with or without bony destruction, orbital tuberculosis spread from the paranasal sinuses and tuberculous dacryoadenitis | malignancy, developmental anomalies, and non-tuberculous infections |
| Lacrimal gland | dacryoadenitis, abscess | either may cause by viruses, bacteria, fungi, and parasites or inflammatory; Sarcoidosis, Wegener's granulomatosis 5 thyroid ophthalmopathy, Sjögren's syndrome and orbital pseudotumor |
| Lid | chronic blepharitis, recurrent chalazion, diffuse infiltration resembling cellulitis | orbital cellulitis presenting with proptosis and ophthalmoplegia, atopic dermatitis, blepharitis(staphylococcal infection), Herpes simplex, Herpes zoster ophthalmicus, tumors. |
| Conjunctiva | conjunctivitis, subconjunctival nodules, polyps, tuberculomas, ulcers, phlyctenulosis | appear as an ulcerative lesion, miliary tubercle, hypertrophic granulation, lupus, or pedunculated mass; nonspecific inflammation suggestive of an allergic, bacterial and viral cause |
| Sclera | presents as a localized area of dark red discoloration of the sclera with chronic granulomatous inflammations and caseous necrosis, possibly leading scleromalacia, sclerokeratitis, sclero uveitis, poesterioscleritis | syphilis, phagolytic granuloma; bacterial infections: commonly Pseudomonas aeruginosa; viral infections: HSV, herpes zoster virus; autoimmune infections, Wegener's granulomatosis parasitic infections; s, systemic lupus erythematosus, juvenile rheumatoid arthritis, polyarthritis nodosa, relapsing polychondritis, psoriasis, gout, atopy, and rosacea |
| Cornea | interstitial keratitis, disciform keratitis, phlyctenulosis, corneal erosion | bacterial infection: Staphylococcus aureus, Pseudomonas aeruginosa; Herpes stromal keratitis, |
| Intra-ocular tuberculosis | | |
| Uveitis | anterior uveitis: iris or angle granulomas, mutton-fat keratic precipitates and posterior synechiae intermediate uveitis: granulomatous, non granulomatous with organizing exudates in pars plana/ peripheral uvea posterior uveitis and panuveitis: disseminated choroiditis is the commonest manifestations, and is often bilateral; multiple, discrete, yellow lesions unilaterally may be seen in posterior pole. As lesions progress their borders may become distinct with a rim of black pigments and the center becomes paler leading atrophic scar. | masquerading infection: HSV, varicella zoster, Vogt-Koyanagi-Harada disease, leprosy, histoplasmosis, toxocariasis, sarcoidosis, syphilis, toxoplasmosis, sympathetic ophthalmia, acute retinal necrosis |
| Choroiditis | tubercles may appear as white, gray, or yellow lesions with indistinct borders and may be accompanied by hemorrhages, exudates, or surrounding edema | sarcoid granulomata, syphilitic gummas, and metastatic tumors, fungal lesions, cryptococcus, serpiginous, toxoplasmosis |
| Choroidal tuberculomas | lesions appears gray, grayish-white or yellowish with the indefinite borders, retinal vessels appear normal with occasional hemorrhage and/or exudation | masquerading infection: sarcoid granulomata, syphilitic gummas, metastatic tumors, lymphomas, osteomas, melanoma or retinoblastoma. |
| Ciliary body tuberculoma | aggressive form of granulomatous tubercular uveitis; chronic smoldering course with intermittent recurrences | sarcoidosis, neoplasia, lymphoma, and fungal granuloma of the ciliary body |
| Tuberculous retinitis | The clinical features include vitreous opacification, gray-white retinal lesions, and rarely, an isolated vasculitis or retinal vascular tumor. | vein occlusion, active retinal periphlebitis, hemorrhagic infarction of the retina, |
| Tuberculous panophthalmitis | painless, progressive visual loss, decreased ocular motility, corneal cloudiness, signs of granulomatous ocular inflammation, and low intraocular pressure | masquerading infections: fungal infection, bacterial infection (commonly Pseudomonas aeruginosa, Clostridia, bacillus spp.) |

merous advantages over other imaging techniques in the rapid diagnosis of many ophthalmic abnormalities; limits the view of the fundus, however [64]. Besides, the scan confers the lower sensitivity in differentiating tuberculomas or tumor; however, may differentiate tuberculomas from other entities [24].

Optical coherence tomography: Optical coherence tomography has become a pivotal tool for detection and

quantification of macular edema and other pathology such as chorioretinal lesions; eventually assists in detection of intraocular tuberculosis (Figure 5) [65]. In higher degree of inflammations, nonetheless, the image resolutions may decrease; hence can not preclude tumors and inflammations resulting from other entity [22,24,65].

Chest X-ray /CT scan: The hematogenous dissemination from the primary origin is the most peculiarity may be observed

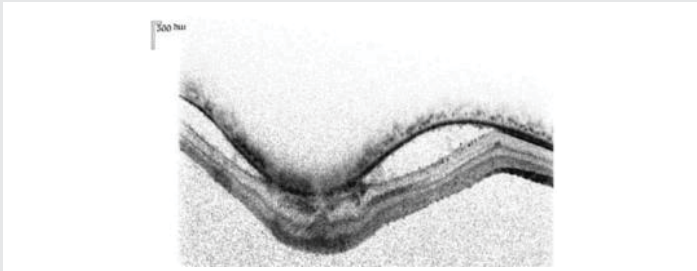


Figure 5: Optical coherence tomography image of the macular region showing choroidal tubercle in 23 years male patient [31].

Table 2: sensitivity and specificity of tuberculin skin test, interferon gamma release assay, and polymerase chain reaction in the diagnosis of ocular tuberculosis (literature review).

i) Tuberculin skin test(TST)

| Reference date | No. of sample | Sensitivity | Specificity |
|---------------------------|---------------|-------------|----------------|
| Ang et al.2009 [47] | 157 | 95.50% | 72.70% |
| Ang et al.2012 [57] | 138 | 72.00% | 51.10% |
| Chee et al.2012 [48] | Group A(21) | 83.00% | 68.00% |
| | Group B(70) | 100.00% | 10.00% |
| Ang et al.2013 [88] | 191 | 71.00% | 67.00% |
| Faiz et al.2014 [89] | 318 | 88.90% | 96.40% |
| Tsiouris et al.2006 [50] | 300 | 90 | Not calculated |
| Ball et al.2010 [49] | 108 | 100% | 53.30% |
| Kharel et al. (2017) [68] | 42 | 76.92% | 62.5% |

Group A: extensive PS or anterior scleritis + TST positive; Group B:Low-grade AC activity (1+) or vasculitis or severe vitritis + TST positive.

ii) Interferon gamma release assay

| Reference date | Interferon gamma release assay | No. of sample | Sensitivity | Specificity |
|---------------------------|--------------------------------|---------------|-------------|----------------|
| Kurup et al. 2006 [90] | QuantiFERON-TB | 216 | 89% | 98.10% |
| Tsiouris et al. 2006 [50] | not specified | 300 | 76% | not calculated |
| Ang et al. 2009 [47] | QuantiFERON-TB | 157 | 90.90% | 81.80% |
| Babu et al. 2009 [56] | QuantiFERON-TB | 108 | 82.00% | 76.00% |
| Ball et al. 2010 [49] | T-SPOT.TB | 108 | 94% | 83.30% |
| Ang et al. 2012 [57] | T-SPOT.TB | 138 | 36.00% | 75.00% |
| Ang et al. 2013 [88] | T-SPOT.TB | 191 | 49.00% | 91.00% |
| Ahn et al. 2014 [91] | QuantiFERON-TB | 181 | 100% | 72.00% |
| Ang et al. 2014 [92] | QuantiFERON-TB | 120 | 64% | 99.00% |
| | T-SPOT.TB | | 67% | 91.00% |
| Urzua et al. 2017 [93] | T-SPOT.TB | 45 | 80% | 85% |
| Kharel et al. 2017 [68] | QuantiFERON-TB Gold test | 42 | 66.67% | 57.14% |

iii) Polymerase chain reaction

| Reference date | No. of sample | Targets used in PCR | Sensitivity | Specificity |
|--------------------------|---------------|---------------------|-------------|----------------|
| Arora et al.1999 [94] | 53 | IS6110 | 37.70% | 95.30% |
| Biswas et al.1999 [95] | 57 | IS6110 | 46.10% | 97.70% |
| Madhavan et al.2000 [78] | 50 | MPB64(n-PCR) | 78.00% | 67.00% |
| Madhavan et al.2002 [79] | 69 | MPB64(n-PCR) | 21.00% | 96.00% |
| Gupta et al.2007 [26] | | IS6110 | 47.10% | not calculated |

| | | | | |
|-------------------------|-----|-------------------------------------|--------|----------------|
| Singh et al.2012 [96] | 28 | MPB64 | 57.00% | 90% |
| Sharma et al.2013 [97] | 25 | IS6110, MPB64, and Protein B (MPCR) | 77.77% | 100% |
| Balne et al.2013 [76] | 14 | IS6110, MPB64, and Protein B (MPCR) | 64.30% | not calculated |
| Bansal et al.2015 [98] | 11 | Multi targeted PCR(Gene Xpert) | 90.00% | not calculated |
| Kataria et al.2015 [98] | 75 | devR | 64% | 100% |
| | | MPBR64 | 72% | 100% |
| Sharma et al. 2016 [86] | 85 | Multi targeted PCR (Gene Xpert) | 22.3.% | 100% |
| Kharel et al.2018 [74] | 100 | IS6110, MPB64 | 71.40% | 76.77% |
| Barik et al.2018 [99] | 29 | mpb64:RPPH1 (normalised) nqPCR | 94.40% | 94.40% |
| | | MPBR64(qPCR) | 61.10% | 72% |
| LAMP study | | | | |
| Sharma et al.2014 [100] | 29 | IS6110 | 70% | 100% |
| Balne et al.2013 [76] | 14 | MPB64 | 85.70% | 100% |

in the ocular TB. Meanwhile, pictorial visualization and radiological evidence of the lesions, the suggestive tubercular entity is crucial in the precise diagnosis. The chest X-ray/CT/HRCT revealing lymphadenitis, cavities, consolidations, calcifications, and fibrosis could be an auxiliary compiling evidence of tuberculosis (Figure 6); nevertheless, are limited with lower sensitivity and specificity. In reference to the aforementioned studies, HRCT compared to chest X-ray and plain CT attributes higher accuracies in presumed ocular TB patients; nonetheless, also not of the absolute accuracy [26,66-68].

Diagnosing direct evidence of the etiology

Microscopic examination: Microscopic examination of acid-fast bacilli, on subsequent staining with Ziehl-Neelsen or fluorescence technique, could be an auxiliary; however, are of lower sensitivity. The applicability of the staining significantly would be helpful in diagnosis of tubercular endophthalmitis—characterized by the lesions with abundant necrotic caseation or may have a higher yield of acid-fast bacilli, nonetheless [69,70].

Microbiological and Histopathological approaches: Even the diagnosis of ocular tuberculosis, based on bacterial isolation, identification, and histological impressions is inconclusive and imperfect. In most case, it seems impractical to obtain ocular biopsy and adequate volume of ocular fluid for culture and histological examinations due to relative paucity of the pathogen in the lesions, prolonged incubation period for cultivation(up to six to eight weeks) and of lower sensitivities and specificities of these approaches [5,14].

On histological examinations, the specimens (biopsy or ocular fluid) with tuberculosis classically show granulomatous inflammation with central caseous necrosis involving the sclera, cornea, conjunctiva, iris, and ciliary body [5]. The granulomas are composed of plentiful epithelioid histiocytes, occasional giant cells of Langerhans type, and lymphomononuclear cells (Figure 7); however, acid-fast-bacilli may or may not be seen on

Ziehl-Neelsen staining [71]. The granulomas/ caseous necrosis and even AFB positive may also insufficiently put on forward confirmation of the infection; since other masquerading pathogens may attribute similar features [72].

Molecular techniques:

Polymerase chain reaction (PCR)

Polymerase chain reaction is becoming a landmark in the detection of *Mycobacterium* genus, using 16S ribosomal DNA, particularly from an extra-pulmonary sample including ocular samples.

qPCR or real-time PCR: The detection of PCR products in real-time PCR rely upon two common methods: either detection of non-specific fluorescent dyes intercalating any dsDNA or detection of sequence-specific DNA probes consisting of oligonucleotides labeled with a fluorescent reporter. After the hybridization of the probe with its complementary sequence in real-time; detection of the etiology can be achieved.

qPCR or real-time PCR emerges as a powerful tool in rapid detection of ocular tuberculosis from the various clinical sample: aqueous humor, vitreous, or sub-retinal fluid and even tissue specimens. Referencing, however, the previous studies higher specificity and variable sensitivity were attributed [4,73,74].

Multi-target PCR (Multiplex PCR): The Multiplex PCR, for amplification of multiple targets in a single PCR, has been used with higher sensitivities and specificities particularly in the detection of pathogens from clinical specimens.

Multi-target PCR, in the diagnosis of ocular TB, three target gene IS6110, MPB64, and protein b has been accessed [75,76]. Resulting, higher sensitivity (77.77%) and specificity (100%) in the diagnosis of ocular TB [75].

Nested PCR (n-PCR): Of a modification of the PCR, Nested PCR is intended to reduce non-specific binding in products due to amplification of an unexpected primer binding site. n-PCR involves the two set of primers (outer pair and inner pair) for a single locus and two successive PCRs. The outer pair primers may contain non-specifically amplified DNA fragments, in the first PCR run. The second set of primers (inner pair primers) bind inside the first PCR product to allow amplification of second PCR product which is shorter than the first one [77].

The clinical applicability of n-PCR accessed, in ocular TB diagnosis, in reference to the previous studies reveals the sensitivity and specificity in the range 21%-78%; 67%-96% [78,79].

Gene Xpert : Xpert MTB/Rif is a cartridge-based nucleic acid amplification test (NAAT); detects DNA sequence specific for MTB and Rifampicin resistance by the basic principle of PCR. The Gene Xpert, in a diagnosis of extra-pulmonary forms of tuberculosis reveals variable sensitivities and specificities. Depending upon the sample type, the sensitivities elucidated from previous studies as: CSF (33% to 59%) (80)(81); Pleural fluid (5% to 33%)(82)(83); tissue(50%) [84]; tubercular lymphadenitis(60%)(85). The aforementioned study on intraocular tuberculosis shows the sensitivities of 22% and the specificity of 100% accessed from the Gene Xpert testing [86].

Unlikely other diagnostic approaches in detection of ocular tuberculosis, PCR based diagnostic test augment the sensitivities and specificities (Table 2(iii)); nevertheless, is also inconclusive or imperfect due to the scantiness of the pathogen, poor lysis of the bacterial DNA during DNA extraction owing to interfering proteinaceous compounds in an ocular fluid and even in the ocular biopsy.

Loop-mediated isothermal amplification (LAMP) assay: Additionally to PCR, the Loop-mediated isothermal amplification (LAMP), targeting *mpb64* gene, has found significantly contributed to detection of intraocular tuberculosis [76]. The assay relies upon auto-cycling strand displacement DNA synthesis in the presence of Bst DNA polymerase under isothermal conditions [87]. It has been found, the assay confers 100% specificity and 87.5% sensitivity in intraocular samples [76].

Moreover, the laboratory technical issue—lacking high and sophisticated molecular laboratory—and the financial burden in patient, particularly in developing countries; often hinders global applications of these molecular tests and attributes further challenges, although much has been written on its applicability.

Conclusion

Notwithstanding but yet in practice, the diagnosis of ocular tuberculosis rely upon on presumptive clinical diagnosis, the clinicians are in a conundrum—often made a diagnosis

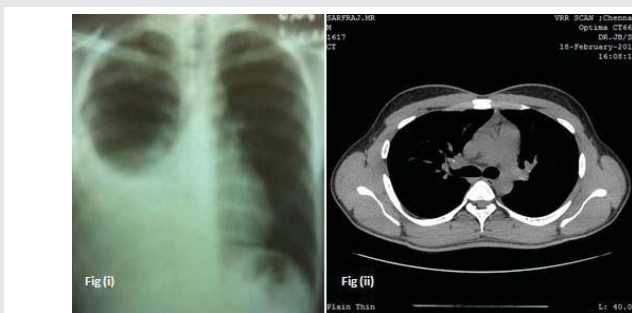


Figure 6: Pictorial visualization of lungs in presumed Pulmonary TB patient with disseminated ocular involvement (i) Chest X-ray showing right-sided tubercular pleural effusion; (ii) Chest CT scan showing bilateral nodules which became consolidated with air bronchogram sign inside.

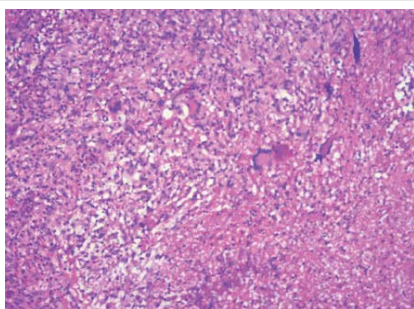


Figure 7: Histopathology slide of ocular tissue showing multiple giant cells surrounded by lymphocytes, plasma cells and epithelioid cells with surrounding areas of caseation in the vitreous (H & E X 200).

as probable and possible ocular tuberculosis—due to the alike clinical presentation as those of ocular infection with different etiology. Likewise, the microbiologists also are being confronted with the pathogen; as presumed gold standard tests are often curtailed. The relative paucity of the pathogen in lesions, bacterial cultures possessing low yield on the ocular sample, wanting a sensitive diagnostic test—even PCR lacking the perfection in DNA detection; expounded further diagnostic challenges. Therefore, the clinicians must resort to every possible test and clinical manifestations—TST or interferon-gamma release assays; chest X-ray/CT findings, and/or evidence of disseminated tuberculosis in an absence of other underlying diseases—so that supporting positive findings would be an auxiliary in the early and specific diagnosis of ocular tuberculosis.

Acknowledgment

The authors would like to thanks Department of Microbiology, Tribhuvan University Teaching Hospital, Nepal and B.P. Koirala Lions Centre for Ophthalmic Studies, Institute Of Medicine, Nepal.

Consent for publication

Written informed consent was obtained from the patient for relevant investigations and publication of the findings was taken from every patient and co-authors.

Authors' contribution

Both PK and RKS designed the manuscript, reviewed the literature, and prepare the article for submission. RKS gave the concept of a research paper and critically reviewed the manuscript.

References

- de Visser L (2009) Infectious Uveitis New Developments in Etiology and Pathogenesis. Utrecht University Repository. [Link: https://bit.ly/2KrC5bQ](https://bit.ly/2KrC5bQ)
- Alvarez S, McCabe WR (1984) Extrapulmonary tuberculosis revisited: a review of experience at Boston City and other hospitals. *Medicine (Baltimore)* 63: 25–55. [Link: https://bit.ly/2WPr3nm](https://bit.ly/2WPr3nm)
- Teixeira-Lopes F, Alfarroba S, Dinis A, Gomes MC, Tavares A (2018) Ocular tuberculosis – A closer look to an increasing reality. *Pulmonology* 24: 273-320. [Link: https://bit.ly/2WE1rtt](https://bit.ly/2WE1rtt)
- Abhinav Dhami RK (Sitaula), Biswas J (2018) Quantitative polymerase chain reaction analysis of serpiginous choroiditis with biopsy-proven testicular tuberculosis. *Indian J Ophthalmol* 66: 320-322. [Link: https://bit.ly/2JSD9pH](https://bit.ly/2JSD9pH)
- Shakarchi FI (2015) Ocular tuberculosis: Current perspectives. *Clin Ophthalmol* 9: 2223-2227. [Link: https://bit.ly/2MtZyVz](https://bit.ly/2MtZyVz)
- Ang M, Chee SP (2017) Controversies in ocular tuberculosis. *Br J Ophthalmol* 101: 6-9. [Link: https://bit.ly/2JY6lv9](https://bit.ly/2JY6lv9)
- World Health Organization (2017) Global Tuberculosis Report 2017: Leave no one behind - Unite to end TB. 146. [Link: https://bit.ly/2QGAMvp](https://bit.ly/2QGAMvp)
- Global Tuberculosis Report (2016) WHO Library Cataloguing-in-Publication.
- Chan RVP (2014) Ocular Tuberculosis (TB) - Asia Pacific. In: American Academy of Ophthalmology. [Link: https://bit.ly/2QIPTQ6](https://bit.ly/2QIPTQ6)
- Teixeira-Lopes F, Alfarroba S, Dinis A, Gomes MC, Tavares A (2018) Ocular tuberculosis – A closer look to an increasing reality. *Pulmonology* 24: 289-293. [Link: https://bit.ly/2WH50Ea](https://bit.ly/2WH50Ea)
- Venkata J, Rao N, Chandini J (2017) Systemic Association of Uveitis in Nepalese Population. *J Chitwan Med Coll* 4: 2673-2676.
- Smith I (2003) Mycobacterium tuberculosis pathogenesis and molecular determinants of virulence. *Clin Microbiol Rev.* 16: 463-496. [Link: https://bit.ly/316osV3](https://bit.ly/316osV3)
- Yang Z, Yang D, Kong Y, Zhang L, Marrs CF, et al. (2005) Clinical relevance of Mycobacterium tuberculosis plcD gene mutations. *Am J Respir Crit Care Med* 171: 1436-1442. [Link: https://bit.ly/2lipvz](https://bit.ly/2lipvz)
- Daniel M (2016) Albert MLR. Ocular Tuberculosis. *Microbiol Spectr* 4. [Link: https://bit.ly/2wAmdA](https://bit.ly/2wAmdA)
- Alvarez GG, Roth VR, Hodge W (2009) Ocular tuberculosis: diagnostic and treatment challenges. *Int J Infect Dis* 13: 432-435. [Link: https://bit.ly/2F30TDx](https://bit.ly/2F30TDx)
- Dalvin LA, Smith WM (2016) Orbital and external ocular manifestations of Mycobacterium tuberculosis: A review of the literature. *J Clin Tuberc Other Mycobact Dis* 4: 50-57. [Link: https://bit.ly/2Wj6Re1](https://bit.ly/2Wj6Re1)
- Khurana S PN, Naik SS, Kashyap S, Sen S BM (2014) Orbital tuberculosis in a paediatric population. *Trop Doct* 44: 148-151. [Link: https://bit.ly/2KrpISm](https://bit.ly/2KrpISm)
- Narula MK CV, Baruah D, Mathuria M AR (2010) Pictorial essay: Orbital tuberculosis. *Indian j Radiol Imaging* 20: 6-10. [Link: https://bit.ly/2WceMvT](https://bit.ly/2WceMvT)
- Salam T UJ, Collin JR, Verity DH, Beaconsfield M RG (2015) Periocular tuberculous disease: experience from a UK eye hospital. *Br J Ophthalmol* 99: 582-585. [Link: https://bit.ly/2Z43nZF](https://bit.ly/2Z43nZF)
- Gupta V SS, Mahajan S, Khairallah M, Rosenbaum JT, Curi A TK (2015) Clinics of ocular tuberculosis. *Ocul Immunol Inflamm* 23: 14-24. [Link: https://bit.ly/2We9BV9](https://bit.ly/2We9BV9)
- Gonzalez-Gonzalez LA M-PN DP (2012) Clinical features and presentation of infectious scleritis from herpes viruses: a report of 35 cases. *Ophthalmology* 119: 1460-1464. [Link: https://bit.ly/2MouBsp](https://bit.ly/2MouBsp)
- Tabbara K (2005) Ocular tuberculosis: anterior segment. *Int Ophthalmol Clin* 45: 57-69. [Link: https://bit.ly/2WnrPbF](https://bit.ly/2WnrPbF)
- Lou SM, Montgomery PA, Larkin KL, Winthrop K, Zierhut M RJ (2015) Diagnosis and treatment for ocular tuberculosis among uveitis specialists: the international perspective. *Ocul immunol inflamm* 23: 32-39. [Link: https://bit.ly/2ETl8mK](https://bit.ly/2ETl8mK)
- Dalvin LA, Smith WM (2017) Intraocular manifestations of mycobacterium tuberculosis: A review of the literature. *J Clin Tuberc Other Mycobact Dis* 7: 13-21. [Link: https://bit.ly/2EOzsNC](https://bit.ly/2EOzsNC)
- Prabhu S, Julie H, Tsai, Mohammed Al-Falah RWR (2017) Tuberculosis Uveitis. *Am Acad Ophthalmology.* [Link: https://bit.ly/2XooS7a](https://bit.ly/2XooS7a)
- Gupta V, Gupta A, Rao NA (2007) Intraocular Tuberculosis-An Update. *Surv Ophthalmol* 52: 561-587. [Link: https://bit.ly/2Z1ybKs](https://bit.ly/2Z1ybKs)
- Ang M, Vasconcelos-Santos DV, Sharma K, Accorinti M, Sharma A, et al. (2018) Diagnosis of Ocular Tuberculosis. *Ocul Immunol Inflamm* 26: 208-216. [Link: https://bit.ly/2XwTJ1z](https://bit.ly/2XwTJ1z)
- Abu El-Asrar AM, Abouammoh M, Al-Mezaine HS (2009) Tuberculous Uveitis. *Middle East Afr Journal of Ophthalmology* 16: 188-201. [Link: https://bit.ly/2WaaWfr](https://bit.ly/2WaaWfr)
- Gupta RBASA (2012) Intraocular tuberculosis. *Expert Rev Ophthalmol* 7: 341-349. [Link: https://wb.md/2XqsZiU](https://wb.md/2XqsZiU)

30. Rosen PH, Spalton DJ GE () Intraocular tuberculosis. *Eye(Lond)* 4: 486-492. [Link: https://bit.ly/2luPeOL](https://bit.ly/2luPeOL)
31. Pandey TR, Sitaula RK, Shah DN, Pant RP (2018) Pattern of presumed tuberculous uveitis in a tertiary eye care centre of Nepal. *Cogent Med* 5: 1-7. [Link: https://bit.ly/2JVHw36](https://bit.ly/2JVHw36)
32. Helm CJ, Holland GN (1993) Ocular tuberculosis. *Surv Ophthalmol* 38: 229-256. [Link: https://bit.ly/2KvHajN](https://bit.ly/2KvHajN)
33. Bansal R, Basu S, Gupta A, Rao N, Invernizzi A, et al. (2017) Imaging in tuberculosis-associated uveitis. *Indian Journal of Ophthalmology* 65: 264-270. [Link: https://bit.ly/2W9SjJM](https://bit.ly/2W9SjJM)
34. Patricio MS, Portelinho J, Passarinho MP, Guedes ME (2013) Tubercular retinal vasculitis. *BMJ Case Rep*. [Link: https://bit.ly/2HVUKec](https://bit.ly/2HVUKec)
35. JS Saini, AK Mukherjee, Nadkarni N (1986) Primary tuberculosis of the retina. *Br J Ophthalmol* 70: 533-535. [Link: https://bit.ly/31aZSmj](https://bit.ly/31aZSmj)
36. Raina UK, Tuli D, Arora R, Mehta DK TM (2000) Tubercular endophthalmitis simulating retinoblastoma. *Am J Ophthalmol* 130: 843-845. [Link: https://bit.ly/2Kpgkct](https://bit.ly/2Kpgkct)
37. Sharma A, Thapa B LP (2011) Ocular tuberculosis: an update. *Nepal J Ophthalmol* 3: 52-67. [Link: https://bit.ly/2Z6HeKa](https://bit.ly/2Z6HeKa)
38. Guly CM, Forrester JV (2010) Investigation and management of uveitis. *BMJ* 341: c4976. [Link: https://bit.ly/2lgAz9K](https://bit.ly/2lgAz9K)
39. El-sarar AMA, Abouammoh M, Al-mezaine HS (2009) Symposium - Uveitis Update Tuberculous Uveitis 16.
40. Matthew Witmer, Tampa F (2009) Unraveling the Difficult Diagnosis of Dacryoadenitis. *Rev Ophthalmology*. [Link: https://bit.ly/319gpXC](https://bit.ly/319gpXC)
41. Mark Wood FRCS (1999) Conjunctivitis: Diagnosis and Management. *Community Eye Health* 12: 19-20. [Link: https://bit.ly/2ER1BDv](https://bit.ly/2ER1BDv)
42. Madge SN, Prabhakaran VC, Shome D, Kim U, Honavar S, et al. (2008) Orbital tuberculosis: A review of the literature. *Orbit* 27: 267-277. [Link: https://bit.ly/2KoWf6c](https://bit.ly/2KoWf6c)
43. Hazlett L, Suvas S, Sharon McClellan SE (2016) Challenges of corneal infections. *Expert Rev Ophthalmol* 11: 285-297. [Link: https://bit.ly/2Wi56sM](https://bit.ly/2Wi56sM)
44. Gonzalez-Gonzalez M-PN (2014) Clinical features and presentation of posterior scleritis: a report of 31 cases. *Ocul Immunol Inflamm* 22: 203-207. [Link: https://bit.ly/2Z6HGbk](https://bit.ly/2Z6HGbk)
45. Prabhu S, Tsai JH, Mohammed Al-Falah RWR (2017) Tuberculosis Uveitis. *Am Acad Ophthalmology*. [Link: https://bit.ly/2Z80as5](https://bit.ly/2Z80as5)
46. Khadka P, Koirala S, Thapaliya J (2018) Cutaneous Tuberculosis : Clinicopathologic Arrays and. *Dermatology Res Pract* 2018. [Link: https://bit.ly/314gqMw](https://bit.ly/314gqMw)
47. Ang M, Htoon HM, Chee SP (2009) Diagnosis of Tuberculous Uveitis: Clinical Application of an Interferon-gamma Release Assay. *Ophthalmology* 116: 1391-1396. [Link: https://bit.ly/2JVq3aX](https://bit.ly/2JVq3aX)
48. Ang M, Hedayatfar A, Zhang R, Chee SP (2012) Clinical signs of uveitis associated with latent tuberculosis. *Clin Exp Ophthalmol* 40: 689-696. [Link: https://bit.ly/316Eheq](https://bit.ly/316Eheq)
49. Ball PM, Pernollet M, Bouillet L, Maurin M, Pavese P, et al. (2010) Usefulness of an in-vitro tuberculosis interferon- γ release assay (T-SPOT. TB) in the first-line check-up of uveitis patients. *Ann Med* 42: 546-554. [Link: https://bit.ly/2ENQf31](https://bit.ly/2ENQf31)
50. Tsiouris SJ, Coetzee D, Toro PL, Austin J, Stein Z, et al. (2006) Sensitivity analysis and potential uses of a novel gamma interferon release assay for diagnosis of tuberculosis. *J Clin Microbiol* 44: 2844-2850. [Link: https://bit.ly/2HVnHXE](https://bit.ly/2HVnHXE)
51. By A, Aap T (2000) Targeted tuberculin testing and treatment of latent tuberculosis infection. American Thoracic Society. *MMWR Recomm reports Morb Mortal Wkly report Recomm reports* 49: 1-51.
52. Ayub A, Yale SH, Reed KD, Nasser RM, Gilbert SR (2004) Testing for latent tuberculosis. *Clin Med Res* 2: 191-194. [Link: https://bit.ly/2QMI4ZF](https://bit.ly/2QMI4ZF)
53. Trad S, B Bodaghi DS (2017) Update on Immunological Test (Quantiferon-TB Gold) Contribution in the Management of Tuberculosis-Related Ocular Inflammation. *Journal Ocular Immunology and Inflammation* 26: 1192-1199. [Link: https://bit.ly/2WiGrca](https://bit.ly/2WiGrca)
54. Trad S, B Bodaghi DS (2017) Update on Immunological Test (Quantiferon-TB Gold) Contribution in the Management of Tuberculosis-Related Ocular Inflammation. *Journal Ocular Immunology and Inflammation* 26: 1192-1199. [Link: https://bit.ly/2WiGrca](https://bit.ly/2WiGrca)
55. Metcalfe JZ, Everett CK SK () Interferon-gamma release assays for active pulmonary tuberculosis diagnosis in adults in low- and middle-income countries: systematic review and meta-analysis. *J Infect Dis* 204: S1120-S1129. [Link: https://bit.ly/2IIMrMr](https://bit.ly/2IIMrMr)
56. Babu K, Satish V, Satish S, SubbaKrishna D, Abraham M, et al. (2009) Utility of QuantiFERON TB gold test in a south Indian patient population of ocular inflammation. *Indian J Ophthalmol* 57: 427-430. [Link: https://bit.ly/2Igrcqp](https://bit.ly/2Igrcqp)
57. Ang M, Wong W, Ngan CCL, Chee SP (2012) Interferon-gamma release assay as a diagnostic test for tuberculosis-associated uveitis. *Eye* 26: 658-665. [Link: https://bit.ly/2Knbv7n](https://bit.ly/2Knbv7n)
58. Ahuja OP, Bal A, Nath K (1967) Middlebrook-Dubos test in experimental ocular tuberculosis. *Am J Ophthalmol* 63: 1744-1748. [Link: https://bit.ly/316q80t](https://bit.ly/316q80t)
59. Sakai J, Matsuzawa S, Usui M, Yano I, Sakai J, et al. (2001) New diagnostic approach for ocular tuberculosis by ELISA using the cord factor as antigen. *Br J Ophthalmol* 85: 130-133. [Link: https://bit.ly/2F34f9B](https://bit.ly/2F34f9B)
60. Inoue K, Numaga J, Joko S (2001) A case of multiple sclerosis with granulomatous uveitis in Japan—use of the antilipoarabinomannan (LAM)-B test in differential diagnosis. *Am J Ophthalmol* 131: 524-526. [Link: https://bit.ly/2IbGhta](https://bit.ly/2IbGhta)
61. Nicholson BP, Nigam D, Miller D, Agrón E, Dalal M, et al. (2014) Comparison of wide-field fluorescein angiography and 9-field montage angiography in uveitis. *Am J Ophthalmol* 157: 673-677. [Link: https://bit.ly/2HVWm7K](https://bit.ly/2HVWm7K)
62. CP H (2009) Fluorescein and indocyanine green angiography for uveitis. *Middle East Afr J Ophthalmol* 16: 168-187. [Link: https://bit.ly/317aAdp](https://bit.ly/317aAdp)
63. CP H (2009) Indocyanine green angiography. Gupta A, Gupta V, Herbot CP KM, editor. New Delhi, India: Jaypee Brothers 88-144.
64. Brunell KS (2014) Ophthalmic ultrasonography. *J Diagnostic Med Sonogr* 30: 136-142. [Link: https://bit.ly/2wBM4mu](https://bit.ly/2wBM4mu)
65. Al-Mezaine HS, Al-Muammar A, Kangave D AE-AA (2008) Clinical and optical coherence tomographic findings and outcome treatment in patients with presumed tuberculous uveitis. *Int Ophthalmol* 28: 413-423. [Link: https://tinyurl.com/yxk95z5g](https://tinyurl.com/yxk95z5g)
66. Ganesh SK, Roopleen, Biswas J, Veena N (2011) Role of high-resolution computerized tomography (HRCT) of the chest in granulomatous uveitis: a tertiary uveitis clinic experience from India. *Ocul Immunol Inflamm* 19: 51-57. [Link: https://tinyurl.com/y6mphrx8](https://tinyurl.com/y6mphrx8)
67. Van Cleeff MR, Kivihya-Ndugga LE, Meme H, Odhiambo JA, KP (2005) The role and performance of chest X-ray for the diagnosis of tuberculosis: a cost-effectiveness analysis in Nairobi, Kenya. *BMC Infect Dis* 5: 111. [Link: https://tinyurl.com/y5jfogt](https://tinyurl.com/y5jfogt)
68. Kharel (Sitaula) R, Iyer V, Noronha V, Dutta Majumder P, Biswas J (2017) Role of high-resolution computerized tomography chest in identifying tubercular etiology in patients diagnosed as Eales' disease. *J Ophthalmic Inflamm Infect* 7: 1–6. [Link: https://tinyurl.com/y3grxelo](https://tinyurl.com/y3grxelo)

69. Biswas J, Madhavan HN, Gopal L (1995) Intraocular tuberculosis. Clinicopathologic study of five cases. *Retina* 15: 461-468. [Link: https://tinyurl.com/y2n585bj](https://tinyurl.com/y2n585bj)
70. Rao A, Saraswathy S, Smith R (2006) Tuberculous Uveitis: Distribution of Mycobacterium tuberculosis in the Retinal Pigment Epithelium. *Ann Ophthalmol* 124: 1777-1779. [Link: https://tinyurl.com/y45rjkyt](https://tinyurl.com/y45rjkyt)
71. Sen S (2017) Pathogenesis and Pathology of Ocular Tuberculosis. In: Al. AK et, editor. *Essentials in Ophthalmology*. Springer International Publishing AG.
72. Garg P (2011) Fungal, Mycobacterial, and Nocardia infections and the eye: An update. *Eye* 26: 245-251. [Link: https://tinyurl.com/y3blbjbj](https://tinyurl.com/y3blbjbj)
73. Sharma P, Bansal R, Gupta V, Gupta A (2011) Diagnosis of tubercular uveitis by quantitative polymerase chain reaction. *J Ophthalmic Inflamm Infect* 1: 23-27. [Link: https://tinyurl.com/y34kxvd2](https://tinyurl.com/y34kxvd2)
74. Kharel (Sitaula) R, Janani MK, Madhavan HN, Biswas J (2018) Outcome of polymerase chain reaction (PCR) analysis in 100 suspected cases of infectious uveitis. *J Ophthalmic Inflamm Infect* 8: 1-8. [Link: https://tinyurl.com/y54co86e](https://tinyurl.com/y54co86e)
75. Sharma K, Gupta V, Bansal R, Sharma A, Sharma M, et al. (2013) Novel multi-targeted polymerase chain reaction for diagnosis of presumed tubercular uveitis. *J Ophthalmic Inflamm Infect* 3: 25. [Link: https://tinyurl.com/y5qvgkat](https://tinyurl.com/y5qvgkat)
76. Kumar Balne P, Ranjan Barik M, Sharma S, Basu S (2013) Development of a loop-mediated isothermal amplification assay targeting the mpb64 gene for diagnosis of intraocular tuberculosis. *J Clin Microbiol* 51: 3839-3840. [Link: https://tinyurl.com/yyc5uj9t](https://tinyurl.com/yyc5uj9t)
77. Hays E van P-VA van BJP (2008) Principles and Technical Aspects of PCR Amplification. Springer Science & Business Media. [Link: https://tinyurl.com/y28d4cke](https://tinyurl.com/y28d4cke)
78. Madhavan HN, Therese KL, Gunisha P, Jayanthi U, Biswas J (2000) Polymerase chain reaction for detection of Mycobacterium tuberculosis in epiretinal membrane in Eales' disease. *Invest Ophthalmol Vis Sci* 41: 822-825. [Link: https://tinyurl.com/ybyh8nol](https://tinyurl.com/ybyh8nol)
79. Madhavan HN TK, DK (2002) Further investigations on the association of Mycobacterium tuberculosis with Eales' disease. *Indian J Ophthalmol* 50: 35-39. [Link: https://tinyurl.com/y46zp3hx](https://tinyurl.com/y46zp3hx)
80. Vadwai V, Boehme C, Nabeta P, Shetty A, Alland D, et al. (2011) Xpert MTB/RIF: a 101 new pillar in diagnosis of extrapulmonary tuberculosis? *J Clin Microbiol* 49: 2540-2545. [Link: https://tinyurl.com/y6g68s45](https://tinyurl.com/y6g68s45)
81. Nhu NT, Heemskerck D, Thu do DA, Chau TT, Mai NT, et al. (2014) Evaluation of 117 GeneXpert MTB/RIF for diagnosis of tuberculous meningitis. *J Clin Microbiol* 52: 226-233. [Link: https://tinyurl.com/y43lnknb](https://tinyurl.com/y43lnknb)
82. Malbruny B, Le Marrec G, Courageux K, Leclercq RCV (2011) Rapid and efficient 120 detection of Mycobacterium tuberculosis in respiratory and non-respiratory samples. *Int J Tuberc Lung Dis* 15: 553-555. [Link: https://tinyurl.com/y5hqekz5](https://tinyurl.com/y5hqekz5)
83. Tortoli E, Russo C, Piersimoni C, Mazzola E, Dal Monte P, et al. (2012) Clinical 123 validation of Xpert MTB/RIF for the diagnosis of extrapulmonary tuberculosis. *Eur Respir J* 40: 442-447. [Link: https://tinyurl.com/yvrc46o](https://tinyurl.com/yvrc46o)
84. Armand S, Vanhuls P, Delcroix G, Courcol RLN (2011) Comparison of the Xpert 126 MTB/RIF test with an IS6110-TaqMan real-time PCR assay for direct detection of 127 Mycobacterium tuberculosis in respiratory and nonrespiratory specimens. *J Clin Microbiol* 49: 1772-1776. [Link: https://tinyurl.com/y22xcy5j](https://tinyurl.com/y22xcy5j)
85. Tadesse M, Abebe G, Abdissa K, Aragaw D, Abdella K, et al. (2015) GeneXpert 130 MTB/RIF Assay for the Diagnosis of Tuberculous Lymphadenitis on Concentrated Fine Needle 131 Aspirates in High Tuberculosis Burden Settings. *PLoS One* 10: e0137471. [Link: https://tinyurl.com/y535tkvc](https://tinyurl.com/y535tkvc)
86. Sharma K, Gupta V, Sharma A, Singh R, Sharma M, et al. (2016) Gene Xpert MTB/RIF assay for the diagnosis of intra-ocular tuberculosis from vitreous fluid samples. *Tuberculosis* 102: 1-2. [Link: https://tinyurl.com/y4h47vfr](https://tinyurl.com/y4h47vfr)
87. Notomi T, Okayama H, Masubuchi H, Yonekawa T, Watanabe K, et al. (2000) Loop-mediated isothermal amplification of DNA. *Nucleic Acids Res* 28: E63. [Link: https://tinyurl.com/y54smjl6](https://tinyurl.com/y54smjl6)
88. Ang M, Wong WL, Li X, Chee SP (2013) Interferon γ release assay for the diagnosis of uveitis associated with tuberculosis: a Bayesian evaluation in the absence of a gold standard. *Br J Ophthalmol* 97: 1062-1067. [Link: https://tinyurl.com/y3fqmuru](https://tinyurl.com/y3fqmuru)
89. Al-Shakarchi FI (2014) Pattern of uveitis at a referral center in Iraq. *Middle East Afr J Ophthalmol* 21: 291-295. [Link: https://tinyurl.com/y34un3mk](https://tinyurl.com/y34un3mk)
90. Kurup SK, Buggage RR, Clarke GL, Ursea R, Lim WK, et al. (2006) Gamma interferon assay as an alternative to PPD skin testing in selected patients with granulomatous intraocular inflammatory disease. *Can J Ophthalmol / J Can d'Ophthalmologie* 41: 737-740. [Link: https://tinyurl.com/y37n7yo8](https://tinyurl.com/y37n7yo8)
91. Ahn SJ, Kim KE, Woo SJ, Park KH (2014) The Usefulness of Interferon-gamma Release Assay for Diagnosis of Tuberculosis-related Uveitis in Korea. *Korean J Ophthalmol* 28: 226-233. [Link: https://tinyurl.com/y5yjc8sw](https://tinyurl.com/y5yjc8sw)
92. Ang M, Wong WL, Kiew SY, Li X, Chee SP (2014) Prospective head-to-head study comparing 2 commercial interferon gamma release assays for the diagnosis of tuberculous uveitis. *Am J Ophthalmol* 157: 1306-1314. [Link: https://tinyurl.com/yys8djy3](https://tinyurl.com/yys8djy3)
93. Urzua CA, Liberman P, Abuauad S, Sabat P, Castiglione E, et al. (2017) Evaluation of the Accuracy of T-SPOT.TB for the Diagnosis of Ocular Tuberculosis in a BCG-vaccinated, Non-endemic Population. *Ocul Immunol Inflamm* 25: 455-459. [Link: https://tinyurl.com/y32rvqgx](https://tinyurl.com/y32rvqgx)
94. Arora SK, Gupta VGA (1999) Diagnostic efficacy of polymerase chain reaction in granulomatous uveitis. *Tuber Lung Dis* 4: 229-233. [Link: https://tinyurl.com/yxvdsmsf](https://tinyurl.com/yxvdsmsf)
95. Biswas J, Therese KL MH (1999) Use of polymerase chain reaction in detection of Mycobacterium tuberculosis complex DNA from vitreous sample of Eales' disease. *Br J Ophthalmol* 83: 994. [Link: https://tinyurl.com/y6jdtzd7](https://tinyurl.com/y6jdtzd7)
96. Singh R, Toor P, Parchand S, Sharma K, Gupta V, et al. (2012) Quantitative polymerase chain reaction for mycobacterium tuberculosis in so-called eales' disease. *Ocul Immunol Inflamm* 20: 153-157. [Link: https://tinyurl.com/ydwj6j6f](https://tinyurl.com/ydwj6j6f)
97. Sharma K, Gupta V, Bansal R, Sharma A, Sharma M, et al. (2013) Novel multi-targeted polymerase chain reaction for diagnosis of presumed tubercular uveitis. *J Ophthalmic Inflamm Infect* 3: 25. [Link: https://tinyurl.com/y5qvgkat](https://tinyurl.com/y5qvgkat)
98. Kataria P, Kumar A, Bansal R, Sharma A, Gupta V, et al. (2015) devR PCR for the diagnosis of intraocular tuberculosis. *Ocul Immunol Inflamm* 23: 47-52. [Link: https://tinyurl.com/y6gl8vwn](https://tinyurl.com/y6gl8vwn)
99. Barik MR, Rath S, Modi R, Rana R, Reddy MM, et al. (2018) Normalised quantitative polymerase chain reaction for diagnosis of tuberculosis-associated uveitis. *Tuberculosis* 110: 30-35. [Link: https://tinyurl.com/y6furomd](https://tinyurl.com/y6furomd)
100. Balne PK, Modi RR, Choudhury N, Mohan N, Barik MR, et al. (2014) Factors influencing polymerase chain reaction outcomes in patients with clinically suspected ocular tuberculosis. *J Ophthalmic Inflamm Infect* 4: 10. [Link: https://tinyurl.com/y4e5o4tp](https://tinyurl.com/y4e5o4tp)

Copyright: © 2019 Khadka P, et al. This is an open-access article distributed under the terms of the Creative Commons Attribution License, which permits unrestricted use, distribution, and reproduction in any medium, provided the original author and source are credited.