

Katarzyna Stolorz¹, Krzysztof Nowosielski^{1,2*}, Izabela Ulman Włodarz¹, Patrycja Sodowska³ and Krzysztof Sodowski^{1,3}

¹Department of Gynecology and Obstetrics, Specialistic Teaching Hospital in Tychy, Poland

²Department of Sexology and Family Planning, Medical College in Sosnowiec, Poland

³Clinical Department of Gynecology and Obstetrics, Municipal Hospital in Ruda Śląska, Poland

Dates: Received: 21 December, 2015; Accepted: 28 January, 2016; Published: 29 January, 2016

***Corresponding author:** Krzysztof Nowosielski, Department of Sexology and Family Planning, Medical College in Sosnowiec, Poland, Tel: +48-502-027-943; E-mail: dr.krzysztof.nowosielski@gmail.com

www.peertechz.com

Keywords: Ovarian hyperstimulation syndrome; Spontaneous pregnancy; Management

Case Report

Ovarian Hyperstimulation Syndrome in Spontaneous Pregnancy

Abstract

Background: Ovarian hyperstimulation syndrome (OHSS) is an iatrogenic complication of supraphysiologic ovarian stimulation but infrequently has been described in spontaneous pregnancy.

Aim: To present a case of a woman in spontaneous pregnancy complicated by OHSS.

Results: A 32-year-old gravida 1, para 1 with spontaneous conception, was diagnosed with moderate OHSS at the 11th week of gestation and was managed conservatively. The woman delivered vaginally at term a healthy female infant.

Conclusion: Although the ovarian hyperstimulation syndrome is characteristic for patients undergoing ovarian stimulation or assisted reproductive technologies it may also occur in spontaneous pregnancy. Multidisciplinary approach has to be taken in managing of those patients.

Abbreviations

OHSS: Ovarian Hyperstimulation Syndrome; VEGF: Vascular Endothelial Growth Factor; hCG: Human Chorion Gonadotropine; CRL: Crown-Rump Length; RBC: Red Blood Cells; HGB: Hemoglobin; HCT: Hematocrit; WBC: White Blood Cells; PLT: Platelets; CA125: Cancer Antigen 125; PCOS: Polycystic Ovary Syndrome; SNPs: Single Nucleotide Polymorphism; FSHR: Follicle-Stimulating Hormone Receptor; TSH: Thyrotropin; LH: Lutropin; IL-2 Interleukin 2; SOCS-1: Suppressor Of Cytokine Signaling-1; PBMCs: Peripheral Blood Mononuclear Cells; HES: Hydroxyethyl Starch; mTOR: Mammalian Target Of Rapamycin; MI: Myo-Inositol; COX-2 Cyclooxygenase-2; Cb2: Cabergoline;

Introduction

Ovarian hyperstimulation syndrome (OHSS) is an iatrogenic complication of supraphysiologic ovarian stimulation but infrequently has been described in spontaneous pregnancy. OHSS is classified as mild, moderate, severe, and critical [1,2]. The symptoms of OHSS is believed to be a result of action of vasoactive peptides (mostly vascular endothelial growth factor – VEGF) released from the granulosa cells in hyperstimulated ovaries. The clinical manifestations of OHSS are: ovarian enlargement, ascites, oliguria, abdominal pain, electrolyte imbalance, hemoconcentration, and even thrombosis in severe cases. The syndrome are nearly always associated with exogenous gonadotropin stimulation (after a luteinizing hormone surge) or exposure to human chorion gonadotropine (hCG) analogues. It is also observed after clomiphene citrate treatment or protocols in in vitro fertilization procedures. Additionally, it was described as spontaneous syndrome in a virgin girl, in multiple pregnancy, polycystic ovary syndrome, gonadotropic pituitary adenoma, fetal trisomy and in few patients with gestational trophoblastic disease [3-12]. Spontaneous OHSS is generally reported to develop between 8 and 14 weeks of gestation, differing from iatrogenic OHSS usually starting between 3 and 5 weeks. We describe a case of a 32-year-

old patient in her first physiological pregnancy with non-iatrogenic causes of ovarian hyperstimulation syndrome.

Case Presentation

A 32-year-old gravida 1, para 1 with spontaneous conception, was admitted to the Department of Gynecology and Obstetrics, Specialistic Teaching Hospital in Tychy at 11+0 gestation weeks. The patient complained of low abdominal pain and dyspnea. The medical and gynecological history of the patient was irrelevant - regular menstrual cycles and no past medical treatment or illness. The patient conceived spontaneously and denied having taken any ovulation inducing agent. Upon admission the patient appeared unwell but her vital signs were stable: a pulse rate of 90/min, temperature of 36.5°C, and blood pressure of 110/70 mmHg. Abdominal examination revealed local tenderness in the area of adnexa with no rebound tenderness. No clinical evidence of ascites and no symptoms of peritonitis were discovered. Transvaginal ultrasound scans were performed showing a single live intrauterine gestation with a fetal crown-rump length (CRL) of 41 mm, which corresponded to 11+0 weeks of gestation, no chorion abnormalities, bilaterally enlarged multicystic ovaries with right ovary measuring 75 x 53mm, left ovary 60 x 42mm (Figure 1) and trace amounts of liquid.

The total blood cell count and other blood test were within normal ranges (Table 1). The mild OHSS was diagnosed (Table 2 for diagnostic criteria) and the conservative management was introduced – bed rest, oral fluid intake (drink to thirst) with fluid balance chart, paracetamol 2x500 mg daily, progesterone 2x100 mg vaginally, daily abdominal girth and weight, blood pressure, pulse, respiratory rate 4 hourly, transvaginal ultrasound scan every second day.

During hospitalization, abdominal pain has intensified. Sonographic examination showed ovarian size increase - right ovary measuring 93 x 70mm, left ovary - 84x61mm with ultrasound evidence of ascites (moderate OHSS).

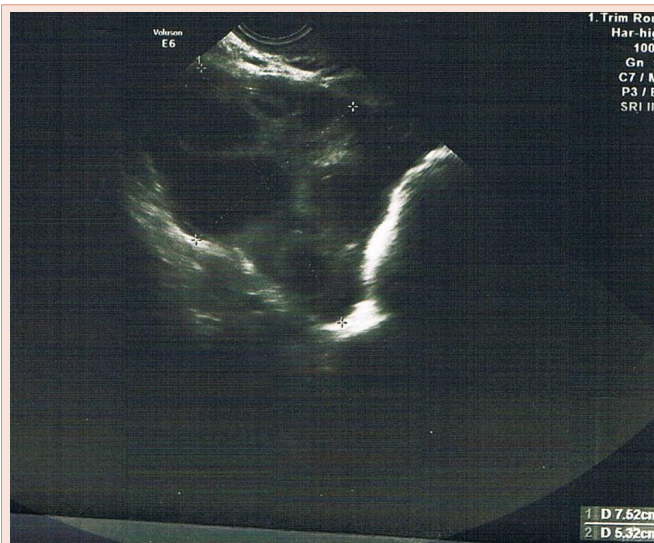


Figure 1: Ultrasonography scan of the patient's ovaries.

Table 1: Blood tests of the patient at admission and at the day of discharge.

Parameter	Day of admission	Day of discharge
Red blood cells	4.7x106/ μ l	4.3x106/ μ l
Hemoglobin	13.1 g/dl	12.8 g/dl
Hematocrit	38.8 %	39.2 %
White blood cells	11.28 x103/ μ l	10.86 x103/ μ l
Platelets	258 x103/ μ l	270 x103/ μ l
Serum protein level	80 g/l	69 g/l
Serum alanine aminotransferase	18 U/l	21 U/l
Serum aspartate aminotransferase	19 U/l	25 U/l
Serum C-reactive protein	0.11 mg/dl	0.32 mg/dl
Serum CA125 antigen concentration	26.2 U/ml	27.1 U/ml

Table 2: Classification of OHSS1 - grade symptoms [1].

Mild OHSS	Abdominal bloating Mild abdominal pain Ovarian size usually < 8 cm
Moderate OHSS	Moderate abdominal pain Nausea \pm vomiting Ultrasound evidence of ascites Ovarian size usually 8 to 12 cm
Severe OHSS	Clinical ascites (occasionally pleural effusion) Oliguria Hemoconcentration hematocrit (> 45%) Hypoproteinemia Ovarian size usually > 12 cm
Critical OHSS	Tense ascites or large pleural effusion Hematocrit (> 55%) White cell count > 25 000 Oligouria/anuria Thromboembolism Acute respiratory distress syndrome

Abbreviations: OHSS: Ovarian Hiper Stimulation Hyndrome.

The prophylactic anticoagulant therapy with low molecular weight heparin (Fragmin 5000 once daily subcutaneously) was introduced and 100 ml of 25% albumin were given intravenously. The patient was also offered cabergoline but did not agree for the proposed treatment. Few days after next ultrasound scan revealed reduction of the ovary size (right 77x52mm, left 69x43mm); the pain gradually subsided and the condition of patient improved. The pregnant patient was discharged from hospital in a good general condition after 3 weeks of hospitalization. On the last day of hospitalization ultrasound scans showed no liquid and normal values ovary. Blood test were also in the normal range (Table 1).

The patient was next under continuous medical care seeing obstetrician every 14 days. The patient was admitted to the labor ward in 39 gestation weeks and delivered vaginally a female infant weighing 3505 g and scoring 10 points in the Apgar scale [13]. 6 weeks after the labor on ultrasound examination at postpartum checkup both ovary were of the normal size. Regular menstrual cycles was returned when the patient discontinued breast-feeding.

Discussion

OHSS has been extensively documented in the literature as a complication of treatment with ovulation-inducing agents. However, some cases of moderate or severe ovarian hyperstimulation syndromes have been reported in spontaneously pregnant patients without the use of any drugs. Severe OHSS is considered a life-threatening condition and occurs in 0.2%-1.2% of stimulated cycles. It is characterized by enlargement of ovaries, increased vascular permeability, fluid shift from intravascular to extravascular space (abdomen, pleura, pericard) and ovarian neoangiogenesis. A consequent are hemoconcentration, decreased renal clearance, oliguria/anuria, modification in coagulation factors and thromboembolic risks. Hemoconcentration leads to an increase of the hematocrit, of the concentration of platelets and leucocytes, creatinin, ureum and liver enzymes in the plasma, as well as to hyperkalemia and acidosis. Serum albumin decreases as a result of extravasation of fluid and ascites formation [1].

Primary risk factors for development of OHSS include: young age, polycystic ovary syndrome (PCOS), lean body weight, high dose of gonadotropins, elevated estradiol and hCG levels, previous history of OHSS, molar pregnancy, multiple pregnancy, hypothyroidism, high basal anti mullerian hormone levels, while secondary are high or rapidly increasing oestradiol levels, high number of follicles, high vascular endothelial growth factor and high inhibin B levels [7]. In our case there were none of primary risk factors.

The etiologic and pathophysiologic mechanisms of OHSS are still poorly understood but it has been suggested that various factors, especially VEGF might increase the capillary permeability and cause fluid loss to the third space. VEGF triggers its signaling via a set of three main tyrosine kinas receptors, named VEGF receptor 1 to 3 (VEGFR1, VEGFR2, VEGFR3). VEGFR-1 shows a strong tyrosine kinas activity response to pro-angiogenic signals and positively affects angiogenesis, while VEGFR-1 functions as an endogenous VEGF inhibitor.

Nauri et al. used the single nucleotide polymorphism (SNPs) in the VEGF gene for genotyping the VEGFR1 and VEGFR2 polymorphism. 116 women diagnosed with OHSS were included in the study. The authors found that VEGF-405 polymorphism and VEGFR1-519 SNP are significantly associated with OHSS [8]. This findings also showed a possibility of correlation between other fertility-related pathologies like PCOS and endometriosis [9,10], but larger studies should be performed to explore putative gene-epidemiology interaction.

In some cases recurrent spontaneous OHSS is caused by mutations of the follicle-stimulating hormone receptor (FSHR). It displayed abnormally high sensitivity to the pregnancy hormone hCG and increased sensitivity to thyrotropin (TSH). FSHR belongs to the glycoprotein hormone receptor family, which includes the thyrotropin TSHR and lutropin/chorionic gonadotropin (LH/hCG) receptors. De Leener et al., classified this syndrome into three types: Type I: caused by FSH receptor mutations; Type II: caused by elevated hCG; Type III: hypothyroidism related [11].

Spontaneous form of ovarian hyperstimulation syndrome may result from a FSH-producing pituitary adenoma (FSH-oma), activating mutations of the FSH receptor (FSHR), and cross reactivity of the FSHR to elevated hCG. Uchida et al., extracted genomic DNA from peripheral blood leukocytes of the patient and from the saliva of her mother and two sisters. Sequencing of all exons of the FSHR gene revealed that the patient was heterozygous for a guanine to adenosine that substituted methionine for isoleucine at position 512 (the mutation was maternal in origin and patient's mother and two sister had the same heterozygous mutation) [12].

Last year Smits et al., identified a mutation in the FSH receptor gene in a patient presenting spontaneous OHSS during each of her four pregnancies. The mutation consisted of a substitution of an adenine for a guanine at the first base of codon 567 in exon 10 of the follitropin receptor gene, resulting in the replacement of an aspartic acid with an asparagine [14]. Similarly, Vasseur et al., revealed a heterozygous substitution of a thymidine for a cytosine in exon 10, resulting in the substitution of isoleucine for threonine at position 449 of the follicle-stimulating receptor protein. The mutation was found in the DNA of two sisters who similarly presented spontaneous OHSS during their pregnancies but not in that of a third unaffected sister [15].

All this molecular studies may help to elucidate the pathogenesis of both the spontaneous and iatrogenic forms of OHSS; FSH and hCG may have synergistic roles in the development of ovarian hyperstimulation syndrome because of hypersensitivity of its receptors. The interaction between hCG and the FSH receptor could be an essential requisite in the development of spontaneous OHSS and could explain why symptoms in spontaneous appear later than in iatrogenic OHSS. It can be assumed that the stimulation of the mutated FSH receptor occurs at a threshold level of hCG and could vary according to the type of mutation. HCG usually peaks between 8 and 10 weeks of pregnancy. Excessive follicular recruitment in association with luteinization of granulosa cells secondary to activation of both the follicle-stimulating hormone receptor and the luteinizing hormone receptor by chorionic gonadotropin can be an explanation for spontaneous ovarian hyperstimulation syndrome

which usually develops as of 8 weeks of gestation (Figure 2). It is than believed that the *FSHR* gene and other gene variations may play a role in modulating receptor sensitivity and intracellular second messenger cascades to hCG and other gonadotropins [16].

In the last study by Orvieto et al. interleukin (IL-2) and suppressor of cytokine signaling (SOCS-1) expressions in the peripheral blood mononuclear cells (PBMCs) in patients suffering from severe OHSS was evaluated. They suggest that the normal negative effect of hCG on PBMCs IL-2 production is lost in women that developed OHSS and the resulting dysregulation of IL2 expression and SOCS activation, might be the culprit of OHSS [17].

OHSS has no specific therapy. Outpatient management is usually possible in women with mild and moderate OHSS. Abdominal discomfort can be treated with paracetamol. To prevent additional hemoconcentration women should be encouraged to drink 2 to 3 liters of fluids per day. Women with severe and critical ovarian hyperstimulation syndrome and who are unable to maintain adequate oral hydration and/or unable to overcome the discomfort of abdominal distension with oral analgesia need to be admitted to hospital. Patients should be considered at risk of thrombosis secondary to hemoconcentration (daily prophylactic doses of low-molecular weight heparin is 5000 subcutaneously /day) [1,2]. In the management of these patients abdominal circumference and fluid balance are crucial and blood tests must be checked frequently. Common finding in these patients is hyponatremia and crystalloids are the first choice for fluid replacement (daily fluid needs change from 1.5 to 3 l). Volume expanders such as dextran, albumin, hydroxyethyl starch (HES), and fresh plasma can also be used [1,2].

A few studies have evaluated medications that could be used in preventing of severe forms of OHSS. Kitsuo et al., analyzed the efficiency of vascular endothelial growth factor, COX-2, calcium and aromatase inhibitors. They concluded that targeting calcium pathways could be beneficial for the vascular permeability control in an OHSS [18]. Kosmas et al., evaluated different pathways linked to vascular endothelial growth factor. They found that Everolimus, an inhibitor of mammalian target of rapamycin (mTOR pathway inhibitor), is highly successful on ovarian hyperstimulation syndrome in animal model by reducing ovarian size, number of corpus luteum and progesterone levels. That finding are promising but future larger studies should be performed [19]. The other treatment option is bevacizumab. That monoclonal antibody can lower VEGF production and ovarian weight what was confirmed in Engin-Ustun et al., study [20]. Another promising treatment for prevention of OHSS is myo-inositol, widely used insulin-sensitizing agent. Turan et al., evaluated the efficiency of myo-inositol (MI) alone and compared with metformine in prevention of OHSS in high risk patients. They showed that MI and metformine are effective in reducing severity of hyperstimulation by reducing vascular permeability, VEGF and COX-2 expressions. Blood oestradiol levels were decreased compared with control group. These two agents act through distinct mechanisms but no study examined additional benefit of co-treatment [21]. The VEGF/VEGFR-2 interaction plays very important role in OHSS pathogenesis. Eskicioglu et al., in the experimental study, examined the efficiency of Montelukast compared with Cabergoline in reducing

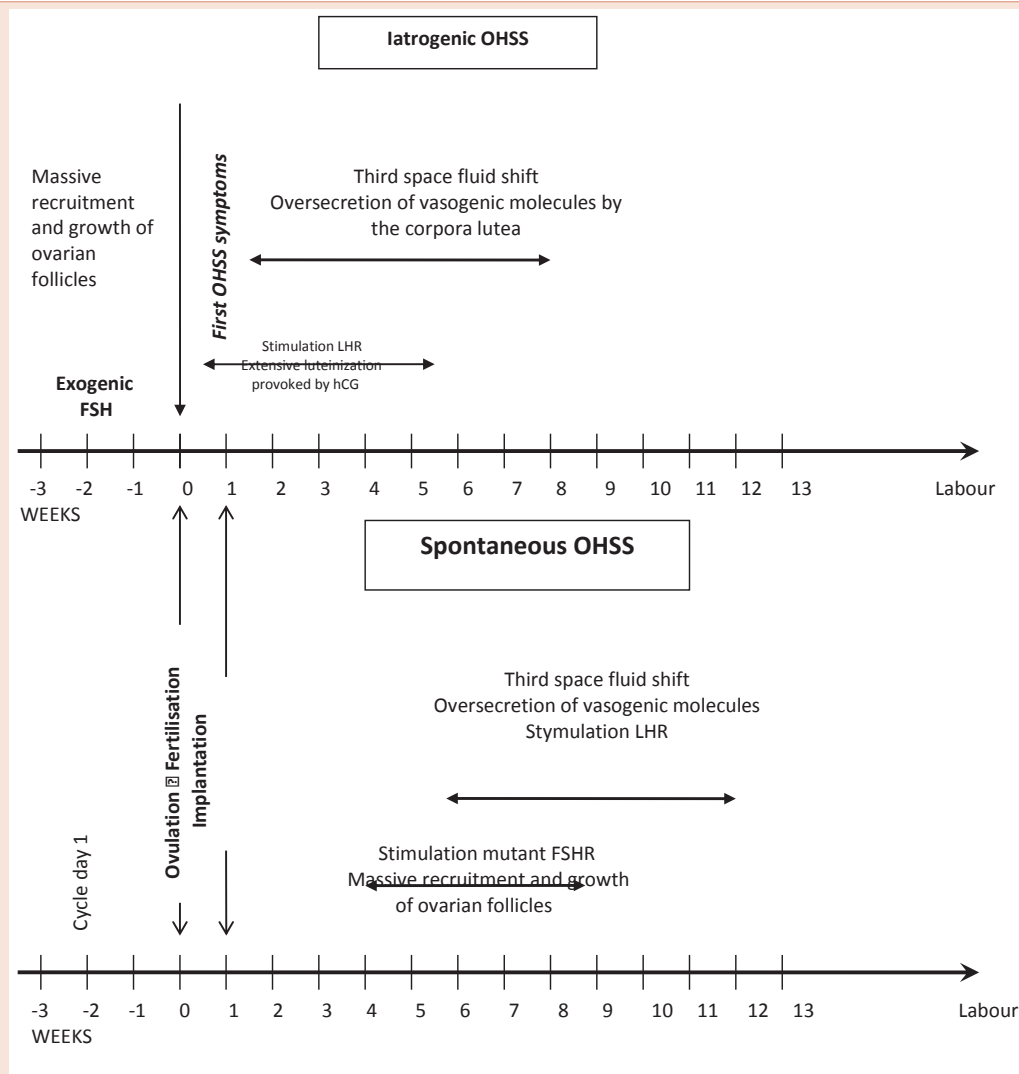


Figure 2: Chronology of iatrogenic and spontaneous ovarian hyperstimulation syndrome [16].

the VEGF expression. Cabergoline is a dopamine receptor agonist and Montelukast is a receptor antagonist of cysteinyl leukotrienes (they decrease the VEGF expression by inhibiting VEGF receptors and reduce vascular permeability). While Montelukast had a significant limiting effect on VEGF expression, vascular permeability and increased ovarian diameter, Cabergoline was superior in limiting an increase in body weight and VEGFR-2 expression. These results proved that both are effective therapies for the prevention of severe OHSS [22].

Cabergoline (Cb2) is the most popular and examined option for prevention and treatment of severe OHSS. A first meta-analysis evaluating impact of Cb2 on the incidence and severity of OHSS was published in 2010 [23]. The VEGF molecule is crucial for the increased vascular permeability that determines OHSS. Dopamine agonists, like Cabergoline, selectively inhibit VEGF-induced vascular permeability without interfering with angiogenesis. Reduced

VEGFR-2 phosphorylation seems to underlie this effect. Most studies of Cb2 administration showed promising results with a daily dose of 0.25-0.5 mg but there are also reported cases a woman who received Cb2 treatment with the increased dose of 1 mg/day. As there is a lot of evidence for overactivation of the VEGF/VEGFR2 system which is major pathologic event leading to OHSS, Cabergoline administration is a specific method of interrupting this process. In some cases complete evasion of the syndrome has not been possible with a daily 0.5 mg dose? Some authors suggest that higher Cb2 doses and longer treatment duration might be required for these patients. Randomized controlled trials assessing the efficacy and safety of different doses and durations of dopamine agonist administration are required [24-26]. It is suggested that in patients using dopamine agonists the occurrence of obstetric or neonatal complications is not different from those seen in normal population [27]. Despite promising study results, the patient describe in our study refuse to take Cabergoline.

Conclusion

It has to be emphasized that although the ovarian hyperstimulation syndrome is characteristic for patients undergoing ovarian stimulation or assisted reproductive technologies it may also occur in spontaneous pregnancy. Obstetricians and other specialists should be aware of the possibility of OHSS in pregnant women manifesting low abdominal pain in the first trimester. Multidisciplinary approach has to be taken in managing of those patients who develop OHSS.

Conflict of Interest

There were no actual or potential conflict of interest including any financial, personal or other relationships with other people or organizations.

References

- Ovarian Hyperstimulation Syndrome (OHSS) Diagnosis and Management. Institute of Obstetricians and Gynaecologists, Royal College of Physicians of Ireland and Directorate of Strategy and Clinical Programmes, Health Service Executive Version 1.0 April 2012 Guideline No. 9 Revision date: April 2014.
- Joint Society of Obstetricians and Gynaecologists of Canada-Canadian Fertility Andrology Society Clinical Practice Guidelines Committee; Reproductive Endocrinology and Infertility Committee of the SOGC; Executive and Council of the Society of Obstetricians; Gynaecologists of Canada; Board of the Canadian Fertility and Andrology Society, Shmorgun D, Claman P (2011) The diagnosis and management of ovarian hyperstimulation syndrome. *J Obstet Gynaecol Can* 33: 1156-1162.
- Sahin L, Yavuzcan A (2013) Recurrent spontaneous ovarian hyperstimulation in a virgin girl. *Ginekol Pol* 84: 647-649.
- Rachad M, Chaara H, Zahra FF, Bouguern H, Melhouf A (2011) Ovarian hyperstimulation syndrome in a spontaneous pregnancy with invasive mole: report of a case. *Pan Afr Med J* 9: 23.
- Sridev S, Barathan S (2013) Case report on spontaneous ovarian hyperstimulation syndrome following natural conception associated with primary hypothyroidism. *J Hum Reprod Sci* 6: 158-161.
- Wieczorek A, Sobancka S, Pietrzak Z, Kunert A, Krasomski G (2011) Spontaneous ovarian hyperstimulation syndrome with pregnancy - a case report. *GinPolMedProject* 1: 62-66.
- Lodh M, Mukhopadhyay J, Sharma V (2014) A case of Severe Ovarian Hyperstimulation Syndrome. *Indian J Clin Biochem* 29: 386-389.
- Nouri K, Haslinger P, Szabo L, Sator M, Schreiber M, et al. (2014) Polymorphism of VEGF and VEGF receptors are associated with occurrence of ovarian hyperstimulation syndrome (OHSS) - a retrospective case-control study. *J Ovarian Res* 7: 54-60.
- Peitsidis P, Agrawal R (2010) Role of vascular endothelial growth factor in women with PCO and PCOS a systematic review. *Reprod Biomed Online* 20: 444-452.
- Li YZ, Wang LJ, Li X, Li SL, Wang JL, et al. (2013) Vascular endothelial growth factor gene polymorphisms contribute to the risk of endometriosis: an updated systematic review and meta-analysis of 14 case-control studies. *Genet Mol Res* 12: 1035-1044.
- De Leener A, Montanelli L, Van Durme J, Chae H, Smits G, et al. (2006) Presence and absence of follicle-stimulating hormone receptor mutations provide some insights into spontaneous ovarian hyperstimulation syndrome pathophysiology. *J Clin Endocrinol Metab* 91: 555-561.
- Uchida S, Uchida H, Maruyama T, Kajitani T, Oda H, et al. (2013) Molecular analysis of a mutated FSH receptor detected in a patient with spontaneous ovarian hyperstimulation syndrome. *PLoS One* 8: e75478.
- (2015) The Apgar score. Committee Opinion No. 644. American College of Obstetricians and Gynecologists. *Obstet Gynecol* 126: e52-55.
- Smits G, Campillo M, Govaerts C, Janssens V, Richter C, et al. (2003b) Glycoprotein hormone receptors: determinants in leucine-rich repeats responsible for ligand specificity. *EMBO J* 22: 2692-2703.
- Vasseur C, Rodien P, Beau I, Desroches A, Gérard C, et al. (2003) A chorionic gonadotropin-sensitive mutation in the follicle-stimulating hormone receptor as a cause of a familial gestational spontaneous ovarian hyperstimulation syndrome. *N Engl J Med* 349: 753-779.
- Delbaere A, Smits G, Olatunbosun O, Pierson R, Vassart G, et al. (2004) New insights into the pathophysiology of ovarian hyperstimulation syndrome. What makes the difference between spontaneous and iatrogenic syndrome? *Hum Reprod* 19: 486-489.
- Orvieto R, Dratviman-Storobinsky O, Lantsberg D, Haas J, Mashiah R, et al. (2014) Interleukin-2 and SOCS-1 proteins involvement in the pathophysiology of severe ovarian hyperstimulation syndrome-a preliminary proof of concept. *J Ovarian Res* 7: 106.
- Kitsou C, Kosmas I, Lazaros L, Hatzi E, Euaggelou A, et al. (2014) Ovarian hyperstimulation syndrome inhibition by targeting VEGF, COX-2 and Calcium pathways: a preclinical randomized study. *Gyn Endoc* 8: 587-592.
- Kosmas IP, Kitsou C, Lazaros L, Markoula S, Peschos D, et al. (2015) Everolimus, an mTOR pathway inhibitor, is highly successful on ovarian hyperstimulation syndrome by reducing ovarian weight and progesterone levels: a preclinical experimental randomized controlled study. *Gynecol Endocrinol* 31: 702-707.
- Engin-Ustun Y, Yilmaz S, Timur H, Ustun Y, Moraloglu O, et al. (2013) Comparison of bevacizumab and cabergoline in the treatment of ovarian hyperstimulation syndrome in a rat model. *Gynecol Endocrinol* 29: 851-854.
- Turan GA, Eskicioglu F, Sivrikoz ON, Cengiz H, Adakan S, et al. (2015) Myo-inositol is a promising treatment for the prevention of ovarian hyperstimulation syndrome (OHSS): an animal study. *Arch Gynecol Obstet* 292: 1163-1171.
- Eskicioglu F, Turan GA, Sivrikoz ON, Cengiz H, Zafer A, et al. (2015) Montelukast is effective in preventing of ovarian hyperstimulation syndrome: an experimental study. *Ginekol Pol* 86: 566-573.
- Youssef MA, van Wely M, Hassan MA, Al-Inany HG, Mochtar M, et al. (2010) Can dopamine agonists reduce the incidence and severity of OHSS in IVF/ICSI treatment cycles? A systematic review and meta-analysis. *Hum Reprod Update* 16: 459-466.
- Ata B, Seyhan A, Urman B (2009) High dose cabergoline in management of ovarian hyperstimulation syndrome. *Fertil Steril* 92: 31168e1-1168e4.
- Sergio SR (2012) Etiology of OHSS and use of dopamine agonists. *Fertil Steril* 97: 517-522.
- Leitao VM, Moroni RM, Seko LM, Natri CO, Martins WP (2014) Cabergoline for the prevention of ovarian hyperstimulation syndrome: systematic review and meta-analysis of randomized controlled trials. *Fertil Steril* 101: 664-675.
- Lei R, Xiao S, Xue M, Deng X (2013) Successful delivery in a woman with natural pregnancy and severe ovarian hyperstimulation syndrome: a case report and literature review. *Nan Fang Yi Ke Da Xue Xue Bao* 33: 1225-1228.

Copyright: © 2016 Stolorz K, et al. This is an open-access article distributed under the terms of the Creative Commons Attribution License, which permits unrestricted use, distribution, and reproduction in any medium, provided the original author and source are credited.

Citation: Stolorz K, Nowosielski K, Włodarz IU, Sadowska P, Sadowski K (2016) Ovarian Hyperstimulation Syndrome in Spontaneous Pregnancy. *J Gynecol Res Obstet* 2(1): 005-009. DOI: <http://dx.doi.org/10.17352/jgro.000007>