

S P P S Rao, Mazin S Ibrahim\*,  
Gurdip Chahal and James Ramos

Heart of England NHS trust, UK

**Dates:** Received: 16 April, 2014; Accepted: 15 July, 2014; Published: 17 July, 2014

\*Corresponding author: Mazin S Ibrahim, Heart of England NHS trust, UK, Email: dibrm80@yahoo.com

[www.peertechz.com](http://www.peertechz.com)

ISSN: 2455-5487

## Review Article

# Talar Neck Fractures: An Overview

### Abstract

Talar injuries are infrequently encountered in practice as the majority require a high energy force such as road traffic accident or fall from height and they are often presented as complex injuries. Talar neck fracture accounts for half of these injuries. Because of the high rate of avascular necrosis (AVN) and posttraumatic arthritis associated with these injuries, it is difficult to predict the prognosis of AVN with the current classification systems. The anatomical position, difficulty of surgical approaches and its complex blood supply add to the challenges. Early recognition and a robust management plan are essential in treating such injuries. Failure to recognize a displaced talus fracture can result in Osteonecrosis, osteoarthritis, malunion or non-union which affects the hind foot function and results in pain, loss of motion and deformity. The integrity of this bone is vital for the function of the ankle, subtalar and mid tarsal joints. This article is an overview of this challenging injury including the mechanism of injury, classification, management and rehabilitation.

## Introduction

Talus fractures and dislocations are infrequently encountered in practice, therefore; scarce evidence is available in the literature on these fractures and their management. However, talar neck fracture accounts for 50% of these injuries [1-3] making its management clearer in the literature. However, a recent study on the patterns of talus fractures showed that the most common talus injury is talus body fracture (61%) [4]. The anatomical position of this bone and its complex blood supply render this bone prone to avascular necrosis and osteoarthritis following injury especially to its neck. Talus fractures are second in frequency after calcaneum fractures of all tarsal bone injuries [1]. Talus fractures account for 6% of all foot injuries [2]. Half of the talus injuries are secondary to road traffic accident (RTA) [2,3,5]. However, Santavirta et al. [6], found in his series that the most common cause of injury is falling from height followed by RTAs. The incidence of talus fractures ranges from 0.1% to 0.85% of all fractures [1-3,5,6].

This article presents a thorough evidence-based review of talus neck fractures, their management and their rehabilitation.

## Mechanism of Injury

The mechanism of injury of talar neck fracture involves mostly acute dorsiflexion force directed at the midpoint of forefoot especially during falls, motor car accident and airplane crash. In 1919, Anderson in his 8 cases review, highlighted that forced dorsiflexion of the foot was the main mechanism of injury of what he described "aviator's astragalus" [1].

With forced dorsiflexion, the anterior tibial edge compress the thin trabecular bone of the talar neck and causes the fracture, with more dorsiflexion, the talocalcaneal ligament and the ligamentous complex of the posterior ankle and subtalar joints will be disrupted causing subluxation or dislocation of the body from its articulation. If forced supination accompanied this, a medial talar neck comminution and subluxation of subtalar joint will occur [1,3].

Medial malleolus fracture is associated with talar neck fracture in 19-28% of cases [2]. In Hawkins study in 1970; found that 26% of talar neck fractures are associated with medial malleolus fracture, and Canale and Kelly found the incidence to be of 15% of talar neck fractures. This highlights the presence of rotational forces associated with these injuries [2,3,5-7].

Lumbar spines fractures are less commonly encountered with this injury but have been found to be associated [2,3,5].

## Blood supply of the talus comes from three arteries

These form extra osseous circulation as described by Wildenaur around the talar neck and sinus tarsi<sup>1</sup>.

Anterior tibial artery gives off the medial tarsal artery branches and anterior medial malleolar branches to supply the superior aspect of the talar neck at the level of ankle joint. The dorsalis pedis artery which is the continuation of anterior tibial artery, gives off the tarsal sinus artery, together with the lateral malleolar branch of the peroneal artery [2], they supply the talar head and distal talar body before anastomosing with tarsal canal artery [5].

Posterior tibial artery branches are divided into calcaneal branches which supply the periosteum and most of the posterior aspect of the talus. It also divides to form artery of tarsal canal, 2 cm below the ankle and passes through the deltoid ligament to give off the deltoid branch to supply the medial talar body and then anastomose with dorsalis pedis over the neck of the talus and also it supplies the middle of talar body as it passes through the superior part of the tarsal canal [2,5].

Perforating branch of peroneal artery gives small branches to anastomose with both calcaneal branches of posterior tibial artery and to dorsalis pedis to form the artery of tarsal sinus [5].

Fortin et al. described the arteries of tarsal canal and tarsal sinus as discrete blood vessels that form anastomotic sling inferior to the talus; these give branches to the talar neck. He described that the body

is mainly supplied by the branches of the tarsal canal artery while the neck and head supplied mainly by the artery of tarsal sinus and dorsalis pedis artery [3]. Deltoid artery is an important source of blood to talar body, it comes from the tarsal canal artery which arises from posterior tibial artery within the deltoid ligament below medial malleolus, therefore; it is essential to preserve the deltoid ligament during reduction or fixation of the talar neck and body [2].

There is intraosseous circulation between all parts of the talus which has been found in 60% of the anatomic specimens [2]. The intraosseous circulation of the talar head comes from dorsalis pedis and the tarsal sinus arteries while those of the body comes from the artery of the tarsal canal inferiorly, deltoid artery medially and tarsal sinus artery network inferolaterally and posteriorly [5].

The anterolateral surface of the body and the posterior tubercles of the talus are relatively avascular [1].

The head has a rich blood supply comes from the anterior tibial artery, the tarsal sinus artery, and the lateral tarsal artery [1,3,5].

The posterior part of the talus is supplied by branches of the posterior tibial artery via calcaneal branches that enter through the posterior tubercle. During injuries of the talus, initial fracture displacement, timing of the reduction and soft tissue handling at the time of surgery are all factors can affect integrity of talar blood supply [3].

### Clinical assessment

These injuries usually present with swelling and haematoma over the ankle with Painful and restricted movements of ankle, subtalar and midtarsal joints [8]. Difficulty in weight bearing and ankle deformity are other signs. The presence of wound over the ankle area should raise suspicion of open fractures.

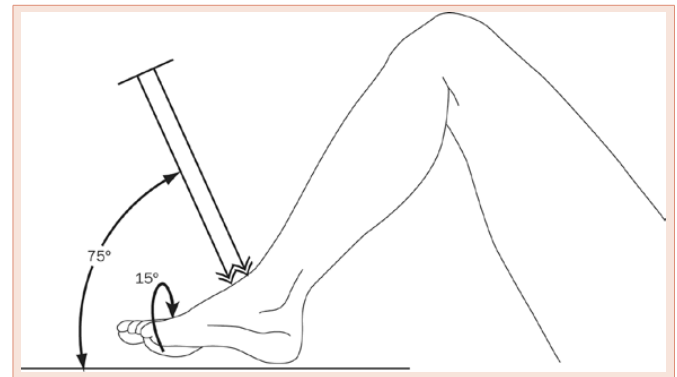
### Radiological assessment

There is a special oblique view described by Canale and Kelly which provides a good evaluation of the talar neck angulation, shortening and comminution. The technique requires maximum equinus, the foot should be pronated at 15 degree and the X-ray tube should be directed cephalad at 75 degree from the surface top (Figure 1). In the acute situation is difficult to perform this technique and the CT supplies this radiographic view. The Canale view is useful in the patient follow-up to detect talar neck consolidation in varus [7-9].

The Talonavicular joint can be assessed with a dorso-plantar view with X-ray tube tilted 20 degrees caudally [8]. Computed tomography is invaluable investigation and this involves 2-mm-thickness sections in the axial and semi coronal planes with sagittal reconstruction [3]. It is usually used even when the fractures are obvious on X-rays as part of pre-operative preparation and planning for surgery [8].

### Classification

Hawkins [10] in 1970 developed a classification system for talar neck fractures; this classification was for vertical neck fractures and based on X-ray appearance at time of the injury, the classification depends on the degree of original displacement and the number of joints involved, it is the most commonly used:



**Figure 1:** Technique of obtaining the talar neck view described by Canale and Kelly [7].

#### Type 1: (Non-displaced).

Is a non-displaced vertical neck fracture with no subluxation. The fracture is extending to the subtalar joint between the middle and posterior facets.

#### Type 2: (dislocated at the subtalar joint).

It is a displaced vertical talus neck fracture with subtalar subluxation or dislocation, the ankle joint must be intact.

#### Type 3: (dislocated at subtalar and tibiotalar joints).

Includes complete displacement of the talar neck, from the body of the talus and which displaced from subtalar and ankle joints.

In this type, Hawkins found that over half of them are open and have associated neurovascular and/or skin compromise with an infection rate as high as 38% [3].

In 1978, Canale and Kelly [3] included Type 4 to Hawkins classification:

#### Type 4: (Dislocation at Subtalar, Tibiotalar and Talonavicular joints)

This includes talar neck fracture with dislocation of the talar body from the ankle and subtalar joints and dislocation of the talar head from the talonavicular joint. Canale and Kelly, reported 4% of their series as of type 4 with unsatisfactory results [3].

This classification has been found to be of prognostic value in predicting outcome and the occurrence of Avascular necrosis (AVN) [7]. It has been found that with more talar neck displacement; the incidence of mal-union, osteoarthritis and osteonecrosis will be higher [1].

Another classification introduced by Marti [7]:

Type 1: Fractures of the talar neck “distal” and including talar head and process fractures.

Type 2: undisplaced talar proximal head and body fractures.

Type 3: displaced talar neck and body fractures.

Type 4: Talar neck and body fractures with dislocated talar body.

## Risk of a vascular necrosis

Range from 10% in non-displaced types to 70% in class 3 injuries [2]. In a large retrospective review of talar fractures, Halvorson et al. [11] reported the overall rate of posttraumatic talar osteonecrosis in a series of 848 patients to be 33.3% (282 patients). Incidence of osteonecrosis was 5.7% (nine) of 159 Hawkins type-I fractures, 18.4% (fiftyeight) of 314 Hawkins type-II fractures, 44.7% (102) of 228 Hawkins type-III fractures, and 12.1% (four) of thirty-three Hawkins type-IV fractures [11]. Canale and Kelly in their study on seventy one patients with talar neck fracture, they found that AVN of the talar body occurred in 52% of the talar neck fractures; two were undisplaced fractures, sixteen with complete dislocation of the body of the talus and half of the patients with subluxation or dislocation of subtalar joint [10]. Vallier et al. [12] revealed that osteonecrosis occurred in approximately 39% of Hawkins type-II fractures and 64% of Hawkins type-III fractures. A recent study concluded that early reduction of dislocation and early treatment of open talar fracture reduces the risk of osteonecrosis in these types of injuries [12]. The main aim of the treatment of these injuries is to minimize the risk of osteonecrosis and osteoarthritis [3].

Hawkins sign (Patchy subchondral osteopenia) is a good objective prognostic sign which indicates revascularization. It is a specific and reliable early indicator of vascular viability and that osteonecrosis is unlikely. It is usually evident at 6-8 weeks and can be visualized on AP or mortis view but not lateral X-ray view. On the lateral view it is difficult to identify the abnormality due to the confusion between the double lines of the talar dome and the patchy subchondral osteopenia. The absence of this sign is not as reliable in predicting the development of osteonecrosis [1,3].

## Treatment

The main aim in the treatment is to achieve anatomical reduction and biomechanical stability in the hind foot. Displacement as little as 2 mm results in changing of contact characteristic of the subtalar joint as shown in one of the cadaveric studies. It has been recommended that any displacement with talar neck fractures, should be treated with Open reduction and internal fixation [3].

In fracture-dislocation of the talus, immediate reduction is recommended to prevent severe soft tissue injury and to protect blood supply to the posterior portion of the talar body [13-16]. Closed reduction may be attempted under adequate analgesia. However, 8 hours delay was acceptable by 60% of American surgeons at level 1 trauma centres who responded to a survey versus 46% surgeons who accepted a delay of more than 24 hours in treating displaced talar neck fractures [8]. Vallier et al. [12] in their study of 100 patients with 102 fractures found no correlation between the timing of reduction and fixation and the development of osteonecrosis. In another recent study Vallier et al. looked into the incidence of osteonecrosis of the talar body following talar neck fractures in a total of 80 patients. They found that the amount of actual fracture displacement and separation involving the Hawkins type II fractures into those with types IIA (subtalar subluxation) and with IIB (subtalar dislocation) helped them to predict the development of osteonecrosis in their series [17].

**Type 1** is difficult to be seen by conventional radiographs,

therefore; Computed tomography and magnetic resonance imaging may be necessary for confirmation [6]. In this type only one source of blood supply will be affected which is the one coming from the dorsal and lateral aspect of the neck moving proximally to the body. No avascular necrosis was identified in the Hawkins series (6 patients) and there was radiological union in all of them [10].

This type can be treated with a cast immobilization (short leg cast) and non-weight bearing for 6 to 8 weeks; mobilization can be resumed when trabeculations can be seen at the fracture site. This type of treatment requires regular radiographs to check for any new displacement at follow up [2]. Osteonecrosis does occur in around 10% of type 1 fractures [2].

**Type 2:** There will be interruption to two of the blood sources; the first one is that extending proximally from the lateral vessels entering the neck and the second is the one entering the foramina in both tarsal canal and sinus tarsi [10].

Reduction usually attempted in accident and emergency first to release pressure on soft tissues, however, many attempts should be avoided as this can add on the sever tissue compromise. Reduction is usually by plantar-flexing the foot to bring the head in line with the body, followed by heel manipulation with inversion or eversion depends on subtalar orientation. If this is successful, the foot should be immobilised in a significant plantar flexion position [2]. This is practically difficult to achieve and to stand the forced position for the patient, therefore, open reduction and internal fixation is recommended.”

Adelaar recommends open reduction as closed one will not achieve anatomical reduction; this is especially when there is 3-5 mm dorsal displacement, subtalar malrotation and 5 degree of neck rotation [1,2].

**Type 3:** Around 50% of them are open and the incidence of osteonecrosis is more than 50% [1]. Urgent reduction (closed or open) of the posteriorly dislocated body is essential to preserve the remaining blood vessels and to relieve the medial neurovascular bundle and the compromised skin as the body tends to dislocate posterior and medial to Achilles tendon [1,3]. This can be assisted using a traction pin through the calcaneum as well as external fixation. Adelaar et al. recommends the use of posteromedial approach to reduce the body and k-wire can be used temporarily to keep in position and to use it as a joy stick to get it back into its normal place [7]. Definitive treatment is to anatomically reduce and use rigid internal fixation using a medial osteotomy anteromedial approach [1].

Weight bearing depends on the healing rate, controlled weight bearing should be achieved with full attention to prevent varus and valgus stresses on the talus [2].

**Type 4:** The treatment of this type is similar to type 3. Urgent open reduction and rigid internal fixation is essential. If there is any instability of the talonavicular joint after fixation, then pinning of that joint is advised [3].

## Surgical approaches to the talar Neck fractures

Anterolateral approach to the talus: The skin incision is over the fourth metatarsal and lines up with this bone. The muscle of extensor

digitorum brevis lies underneath the skin incision and once the muscle is split the lateral talus and subtalar joint is directly visible underneath and can be utilized (Figure 2).

The anteromedial approach uses the safe plane between tibialis anterior and extensor hallucis longus tendons. This skin incision is from the medial malleolus proximally to the base of the first metatarsal distally (Figure 3) [2,17,18].

Direct lateral approach to the talus: The skin incision is centered over the lateral process of the talus and immediately in front of the fibula parallel to the peroneal tendons (Figure 4).

Incision is over the posterior medial aspect of the ankle joint between the flexor hallucis longus and the Achilles tendon (Figure 5). The neurovascular structures lie posteromedially behind the medial malleolus and must be protected. The tendon sheath of the flexor hallucis longus must be opened to approach the posterior talar body [17,18].

Posterolateral approach to the hind foot (Figure 6).

This approach is very useful as it is a true internervous and intermuscular approach. It is useful as an approach to the posterior talus, the posterior aspect of the distal tibia, the posterior distal fibula and the posterior portion of the calcaneus.

The skin incision is made vertically between the peroneal tendons anteriorly and the Achilles tendon posteriorly.

Medial malleolar osteotomy (Figure 7).

Skin incision extends proximally from the medial malleolus to the base of the first metatarsal distally. Care must be maintained, to avoid damage the deltoid branch of the posteromedial vasculature which supplies a majority of the medial talus.

Lateral malleolar osteotomy (Figure 8).

Landmarks for this incision are based on the anterior fibula proximally and in line with the fourth ray distally. The superficial branch of the peroneal nerve must be carefully protected. The anterior distal tibiofibular ligaments are incised. Fibular osteotomy is planned 3 cm above the joint surface, just above the insertion of the distal tibiofibular ligaments [17].

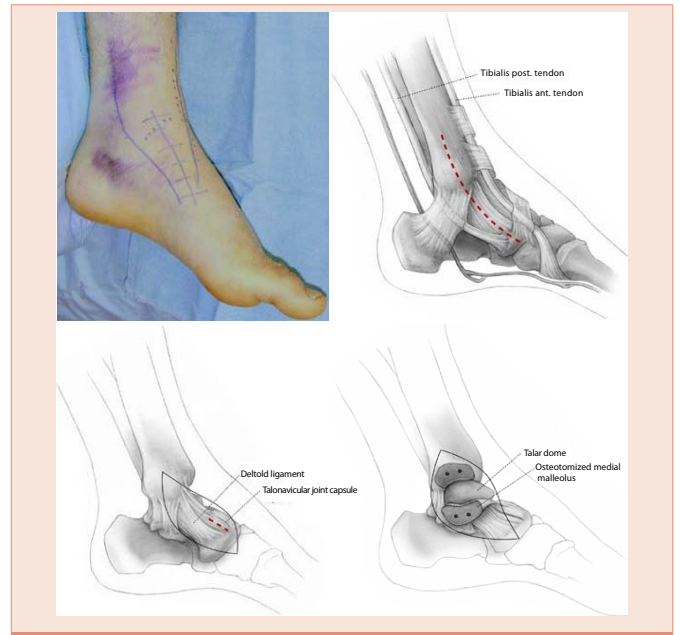

Figure 3: Approach showing the bony landmarks and exposure leading to direct visualisation of the bones [12].

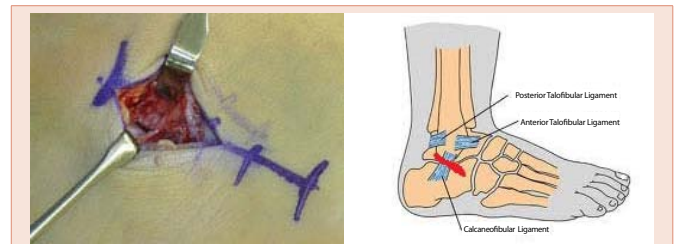


Figure 4: Lateral approach to the talus. Red line shown is the skin incision [12,18].

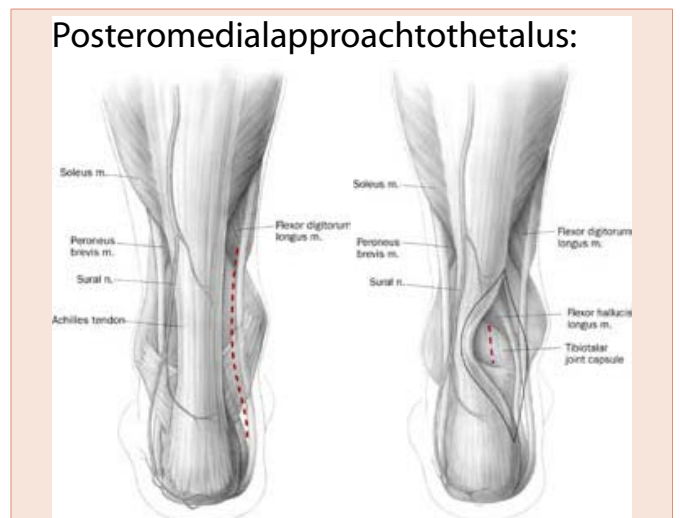


Figure 5: Schematic posteromedial approach to the talar body [18].

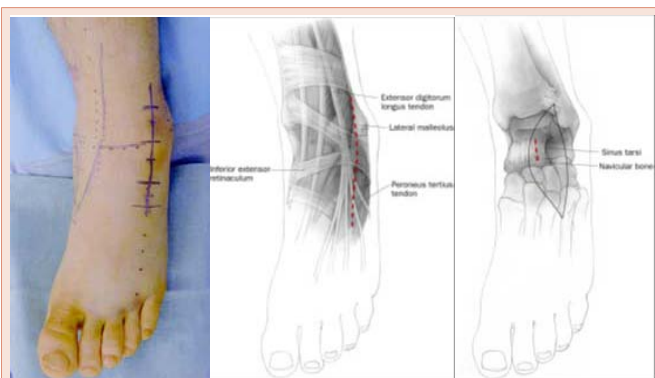
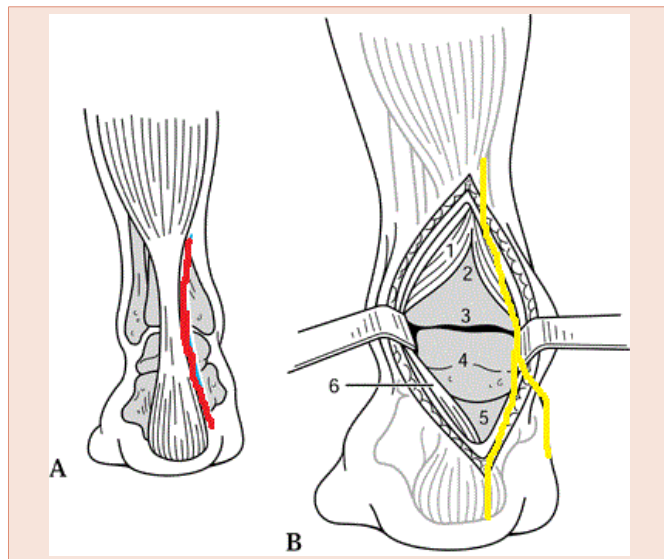


Figure 2: Approach to the talus utilizing the anterolateral skin incision and the medial branch of the superficial peroneal nerve is seen [2,17,18].



**Figure 6:** Schematic diagrams showing the red skin line incision and yellow neurovascular structures of sural nerve and its lateral calcaneal branch encountered in the posterolateral approach to the talus [17]. 1. Flexor hallucis longus; 2. Tibia; 3. Ankle Joint; 4. Talus; 5. Subtalar Joint; 6. Achilles tendon.

**Fixation Materials and Preferred methods**

All the above mentioned approaches are used in combination with various permutations and combinations possible.

Fortin et al. described the medial approach through incision medial to tibialis anterior tendon starting at the level of navicular tuberosity and can be extended proximally to fix malleolar fractures [3]. Attention should be paid to avoid stripping the dorsal neck blood vessels and those entering at the level of deep deltoid ligament [5]. Some authors also described the anterolateral approach; this starts lateral to common extensor digitorum longus peroneus tertius sheath; this provides exposure to the stronger lateral talar neck [3].

A posterior approach is recommended for a better mechanical fixation with incision either lateral or medial to the achilles tendon [2]. Adelaar also recommend using a small anterolateral incision as well to obtain accurate reduction of the talar neck. A combination of either anteromedial or anterolateral approaches for initial reduction and temporary fixation with Kirschner wires followed by posterolateral approach for screw insertion from posterior to anterior direction [6].

Fixation can be achieved using AO cancellous screws, AO malleolar screws, cannulated screws and Kirschner wire under image intensifier control to obtain reduction and maintain rotational control [2,18,17].

Fortin et al. advocate the use of headless lag screws if anterior to posterior screw insertion required as headed screws can interfere with talonavicular joint if the head is slightly prominent. Post-operative instructions will include eight to twelve weeks non-weight bearing [3].

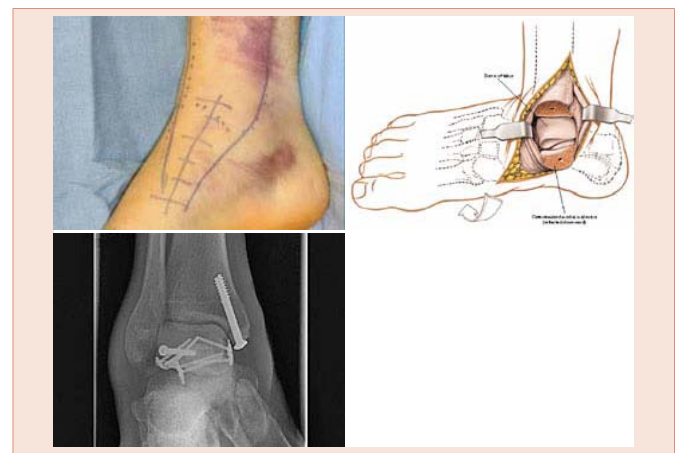
In Hawkins series 1970, 42% of these fractures developed AVN, but all of them had union [10].

Adelaar et al. 1997 advised against a closed reduction for displaced talar neck fractures and the use of K-wires as a sole mean of treatment as they have been found to be weaker than screws. He recommends screw insertion from posterior to anterior direction rather than the other way round as they provide a better biomechanical stability. He also recommends the use of titanium screws in unstable fractures with more risk of osteonecrosis in case we need to use MRI scan, the latter can be used in the presence of these screws [1,3].

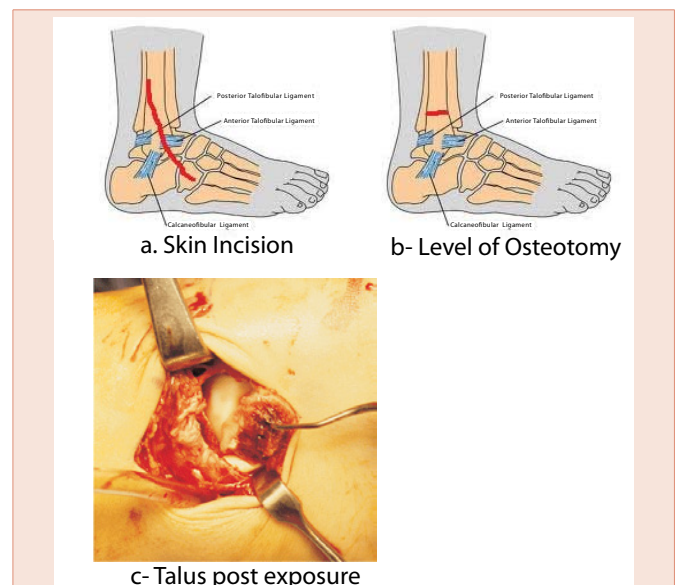
**Complications of talar neck fractures**

Avascular necrosis: discussed earlier.

Arthritis of the ankle or subtalar joints, mal-union, AVN, delayed union or non-union, infection can occur in all types of talar fractures [1].



**Figure 7:** Diagrammatic representation of the medial malleolar osteotomy approach and final fixation x-ray [17].



**Figure 8:** Diagrammatic representation of the lateral malleolar osteotomy approach to the Talus [17].

Osteoarthritis (subtalar and ankle arthritis): The incidence of degenerative joint disease with type 1 quoted as 0-30% with type 1 to 70-100% with type 3 [3].

Mal-union: Fortin et al. summarized the incidence of mal-union with talar neck fractures as follows: 0-10% with type 1, 0-25% with type 2 and 18-27% with type 3 and 4 [3].

The incidence of these complications increase by the increase in Hawkins type fracture [2,3].

MRI scan is a valuable investigation to quantify osteonecrosis but it is useful from 3 weeks after injury with reported false negatives [1-3].

## Conclusion

Talar neck fractures are difficult injuries to treat. Early identification, treatment and rehabilitation are important to avoid long-term complications especially the risk of avascular necrosis. The choice of the treatment plan is based on the type of neck fracture and the degree of displacement. The knowledge of the blood supply of this bone is essential for any surgeon to avoid damage to the blood supply which can result in long term problems.

## References

1. Adelaar RS (1997) Complex fractures of the talus. Instr Course Lect 46: 323-338.
2. Adelaar RS (1990) Fractures of the talus. Instr Course Lect 39: 147-156.
3. Fortin PT, Balazsy JE (2001) Talus fractures: evaluation and treatment. J Am Acad Orthop Surg 9: 114-127.
4. Dale JD, Ha AS, Chew FS (2013) Update on Talar Fracture Patterns: A Large Level I Trauma Center Study. Am J Roentgenol 201: 1087-1092.
5. Higgins TF, Baumgaertner MR (1999) Diagnosis and treatment of fractures of the talus: a comprehensive review of the literature. Foot Ankle Int 20: 595-605.
6. Santavirta S, Seitsalo S, Kiviluoto O, Myllynen P (1984) Fractures of the talus. J Trauma 24: 986-989.
7. Canale ST, Kelly FB (1978) Fractures of the neck of the talus. Long-term evaluation of seventy-one cases. J Bone Joint Surg Am 60: 143-156.
8. Rammelt S, Zwipp H (2009) Talar neck and body fractures. Injury 40: 120-135.
9. Adelaar RS (1989) The treatment of complex fractures of the talus. Orthop Clin North Am 20: 691-707.
10. Hawkins LG (1970) Fractures of the neck of the talus. J Bone Joint Surg Am 52: 991-1002.
11. Halvorson JJ, Winter SB, Teasdall RD, Scott AT (2013) Talar neck fractures: a systematic review of the literature. J Foot Ankle Surg 52: 56-61.
12. Vallier H, Nork SE, Barei DP, Benirschke SK, Sangeorzan BJ (2004) Talar neck fractures: results and outcomes. J Bone Joint Surg Am 86-A: 1616-1624.
13. Berlet GC, Lee TH, Massa EG (2001) Talar neck fractures. Orthop Clin North Am 32: 53-64.
14. Frawley PA, Hart JA, Young DA (1995) Treatment outcome of major fractures of the talus. Foot Ankle Int 16: 339-345.
15. Smith PN, Ziran BH (1999) Fractures of the talus. Operative Tech Orthop 9: 229-238.
16. Schulze W, Richter J, Russe O, Ingelfinger P, Muhr G (2002) Surgical treatment of talus fractures: a retrospective study of 80 cases followed for 1-15 years. Acta Orthop Scand 73: 344-351.
17. Vallier HA, Reichard SG, Boyd AJ, Moore TA (2014) A new look at the Hawkins classification for talar neck fractures: which features of injury and treatment are predictive of osteonecrosis? JBJS Am 96: 192-197.
18. Buckley R, Sands A, AO Foundation approaches to the Talus. Accessed online on 1/3/2014.
19. Vallier HA, Nork SE, Benirschke SK, Sangeorzan BJ (2004) Surgical Treatment of Talar Body Fractures. J Bone Joint Surg Am 86-A Suppl 1(Pt 2): 180-192.

**Copyright:** © 2014 Rao SPPS. This is an open-access article distributed under the terms of the Creative Commons Attribution License, which permits unrestricted use, distribution, and reproduction in any medium, provided the original author and source are credited.

**Citation:** Rao SPPS, Ibrahim MS, Chahal G, Ramos J (2014) Talar Neck Fractures: An Overview. J Nov Physiother Phys Rehabil 1(1): 013-018. DOI: 10.17352/2455-5487.000003