

**Abdisa Tagesu\***

Jimma University, School of Veterinary Medicine,  
Jimma, Oromia, Ethiopia

Received: 14 May, 2018

Accepted: 13 August, 2018

Published: 14 August, 2018

\*Corresponding author: Abdisa Tagesu, Jimma University, School of Veterinary Medicine, Jimma, Oromia, Ethiopia, Tel: +251933681407, E-mail: [abdisatagesu@gmail.com](mailto:abdisatagesu@gmail.com)

<https://www.peertechz.com>

## Research Article

## Regional or systematic clinical examination

### Clinical Examinations of the head and neck region

The clinical examination of head and neck can be undergone by further visual inspections and observations, before examination of head and neck the following question could be asked: [1]:

- \* Movements of head and neck – normal or abnormal
- \* Carriage of head – normal or tilted,
- \* Can the animal see?
- \* Can the animal hear?
- \* Ocular or nasal discharge,
- \* Salivation – normal or excessive,
- \* Ability to prehend, masticate and swallow food
- \* Mobility of the neck.

The perspective of this examination is to identify pale and discolored mucus membranes; assess problems of oral cavity and deranged appetite. The following points should be considered:

- \* Visible mucous membrane
- \* Eyelids, conjunctivae and eyes
- \* Nasal regions and nasal mucous membrane
- \* Prehension, mastication and deglutition
- \* Salivation
- \* Teeth eruption

### Procedures

- \* Visible mucous membrane examined by visual inspection to note the presence of lesions, discharge, glaucoma, nystagmus.
- \* Examine the nose and nasal sinuses; lesions, discharges should be noted by percussion, palpation
- \* Examine the mouth and appetite; oral lesions, salivation, feed intake should be noted. The rigidity of tetanus, the cunning leer or maniacal expression of rabies and acute lead poisoning are cases in point.

The symmetry and configuration of the bony structure should be examined. Doming of the forehead occurs in some cases of congenital hydrocephalus and in chondrodysplastic dwarfs, and in the latter there may be bilateral enlargement of the maxillae. Swelling of the maxillae and mandibles occurs in osteodystrophia fibrosa; in horses swelling of the facial bones is usually due to frontal sinusitis; in cattle enlargement of the maxilla or mandible is common in actinomycosis. Opisthotonos is an excitation phenomenon associated with tetanus, strychnin poisoning, acute lead poisoning, hypomagnesemic tetany, polioencephalomalacia and encephalitis <sup>2</sup>. Visible discharge should be noted; protrusion of the eyeball, as occurs in orbital lymphomatosis, and retraction of the bulb, as occurs commonly in dehydration, are important findings; spasm of the eyelids and excessive blinking usually indicate pain or peripheral nerve involvement; prolapse of the nictitating membrane usually characterizes central nervous system derangement, generally tetanus <sup>2</sup>. Excessive salivation or frothing at the mouth denotes painful conditions of the mouth or pharynx or is associated with tremor of the jaw muscles due to nervous involvement. Swellings below the jaw may be inflammatory, as in actinobacillosis and strangles, or edematous, as in acute anemia, protein starvation or congestive heart failure.

### Examination of skin and appendages

The skin provides protection against minor physical injuries supports hair growth and offers some defence against microbial invasion. The condition of the skin is a reflection

of the general health of the animal, deteriorating in cases of ill health, ill thrift and debility. In some conditions, such as jaundice, the skin may provide through discolouration direct diagnostic evidence of a specific disease process. In other conditions, such as parasitism or severe mineral deficiency, a nonspecific general deterioration of skin health may occur causing a greater number of hairs than normal to enter the telogen or resting phase and a delay in their replacement, leaving the coat in poor condition with little hair [1].

Sebaceous secretions may be reduced, allowing the skin to become abnormally dry and inflexible and less able to perform its normal defence role in an already debilitated animal. In other cases, sebaceous secretion increases causing the skin to have either a greasy or a dry seborrhoeic, flaky Appearance [1]. Structures or parts associated with skin as its appendages are hoofs, hairs, horns, quills, claws, nails, sebaceous glands and sweat glands. Discrete skin lesions range in type from urticarial plaques to the circumscribed scabs of ringworm, pox and impetigo. Diffuse lesions include the obvious enlargements due to subcutaneous edema, hemorrhage and emphysema. Enlargements of lymph nodes and lymphatics are also evident when examining an animal from a distance [2,3].

The perspective point to assessing the condition of skin and coat to identify clinical signs of skin lesions such as:

- \* Condition of the coat
- \* Elasticity of the coat
- \* Pruritus
- \* Primary and secondary skin lesions
- \* Dermatitis
- \* Hyperkeratosis or parakeratosis
- \* Presence of ectoparasites.

Discoloration of the skin may arise due to anaemia, cyanosis, jaundice, hyperaemia. In febrile conditions hair may be erect and in all chronic diseases with disturbances in nutrition, hair become rough, lusterless dry and coarse. Alopecia (Loss of hair) may occur due to diseases like ring worm, scabies, eczema, iodine and Vit A deficiencies, Procedure: Examine the skin and coat: grasp the skin of the upper part of the body and notice the elasticity, visual inspection of the condition of the coat and presence of skin lesions should be noted. The abnormalities which occurred from skin due to disease and others are summarized in table 1. The disease of skin can be divided into two lesions, primary and secondary. As it is described in table 1 the following is the most common caused by diseases:

### Primary lesion

- \* Macule: cause by early stage of pox –Tick bites.
- \* Vesicle is caused by: Vesicular stomatitis or Foot and mouth disease
- \* Pustules: caused by pastular dermatitis

- \* Wheals: cause by urticarial, allergic conditions
- \* Papulae: caused by eczema, pox

### Secondary skin lesion

- \* *Dandruff or scales* or pityriasis cause by: Mange, Vit. A deficiency, Ringworm.
- \* *Crust or scab* caused by: Pox, Dermatitis.
- \* *Erosion or ulcers* caused by: Foot and mouth disease, Ulcerative dermatitis, Burns, uncreative lymphangite, epizootic lymphangite.

### Examinations of the thoracic cavity

Examination of the thoracic cavity guides to show the regional anatomy of the lungs and the heart, and perform physical examination of the lung and the heart area. Regional anatomy of the lungs –locate the lung area. The lung is located on the external surface of the thoracic region by forming an imaginary triangle by using the points at the angle of the scapula, olicranun process and the second intercostals space from the last [1,4].

#### Physical examination of the thorax (lung area)

- Inspection –note respiratory movements
- Palpation –check the presence of pain by applying pressure
- Percussion –notice resonant sound
- Auscultation –note bronchial sounds (trachea and anterior part of the lungs) and alveolar sounds

### Palpation

Chest palpation can be useful to identify thoracic pain which may be caused by rib fractures and pleuritis. Gentle pressure should be applied to the thorax using the palm of the hand and the animal observed for a pain response. The entire thorax should be explored in a systematic manner to identify focal areas of pain. In addition to pain, subcutaneous emphysema may be detected as a spongy sensation which may be accompanied by crackling noises. This clinical sign is sometimes seen in outbreaks of respiratory syncytial virus and is caused by rupture of emphysematous bullae in the lungs [1].

**Table 1:** The pathological lesion of skin in domestic animals and its causative agents.

Primary skin lesions	Description	Causative agents	Secondary skin lesions	Description
Spot	Circumscribed red area of skin which is not elevated or swollen	Flea bites	Erosion	Destructive separation of the epidermis (contagious pustular dermatitis of sheep and goat).
Papule	Firm elevation of skin surface caused by cellular infiltration	Pox	Ulcer	Circumscribed shallow destructive area of tissue with or without elevated edges (equine ulcerative lymphangitis).
Vesicle	Elevation of superficial layer of skin with accumulation of serous fluid beneath it.	FMD, vascular stomatitis, pox	Crust	A firm mass consisting of dried inflammatory exudate or blood.
Blister	A large vesicle	?	Dandruff	Secondary to ectoparasites
Pustule	A pus-filled vesicle	?	?	

## Auscultation

During auscultation, the stethoscope should be moved systematically to cover the whole of thoracic lung fields with the aim of identifying any abnormal sounds present, their location and their occurrence in relation to the respiratory cycle. The location of an abnormal sound is deduced from the position of maximal intensity. Particular attention should be given to the apical lobe if bacterial pneumonia is suspected or the diaphragmatic lobe if lungworm is suspected [1,2].

**Abnormal sound and its causative which is heard from auscultation of lung are listed as (www.bu.edu.eg):**

- ✓ Moist rales: pulmonary edema, bronchopneumonia, chronic bronchitis and pulmonary hemorrhage.
- ✓ Dry rales: Spasm in bronchial muscle, bronchitis, early stage of pneumonia
- ✓ Crepitate rales: it is rise from; Bronchiolitis, interstitial pneumonia.
- ✓ Emphysematous sound: pulmonary emphysema, pneumothorax.
- ✓ Frictional sound: pleurisy, pericarditis.
- ✓ Absence (dull) sound: Tumor, TB, consolidation of lung, lung collapse.
- ✓ Grunting sound: It is forced expiration associated with closed epiglottis and usually associated with painful conditions either in thoracic or in the abdominal cavity.

**Pulmonary grunting sound are like:** pleurisy, traumatic pericarditis, sever pneumonia and pulmonary emphysema.

**Abdominal grunting sounds are like:** Sever pain in Vaginitis, Urethritis, Urolithiasis, Cystitis, Nephritis, Pyometria, Peritonitis, Traumatic reticuloperitonitis, Bloat and Impaction

**Abnormalities associated with respiratory system:**

**Epistaxis:** It is bleeding from nostril of animals; it is caused by some disease like: Trauma, Pulmonary hemorrhage, Rhinitis, Anthrax and High blood pressure

**Sneezing:** It is caused by irritation or some response occur in mucous membrane of nose. It can occurred when rhinitis is occurred, aspiration pneumonia and in halation of irritant smoke.

**Nasal discharge:** When serous or some discharge is coming out of nostril in some cases. The discharge can be Serous (in early stage of diseases or mucoid in late stage or after secondary bacterial infection). The discharge may contain gas bubbles, Copious (acute diseases or scanty in chronic form of disease). Tinged with blood -With bad odor (infection or in gangrenous pneumonia). Unilateral (in unilateral affection of upper respiratory tract) or bilateral in affection of lower respiratory tract. The causes of nasal discharge may be: Bacterial pneumonia, chronic bronchitis, IBR (Infectious

Bovine Rhinotracheatitis), Gangrenous pneumonia, Rhinitis Pyogenic infection of Paranasal sinuses.

**Dyspnea:** difficulty to breath, it is characterized by mouth breath, dilated nostrils, pumped anus, abnormal respiratory rhythm, extension of head and neck, cyanosis of mucous membrane. The major causes of dyspnea are like: Stenosis of upper respiratory tract, Bronchopneumonia, Bronchitis, Impaction, Pulmonary edema and congestion, Traumatic pericarditis

**Coughing:** Coughing may occur by irritation around larynx and respiratory tract. It is caused by Bronchitis, Parasitic pneumonia, interstitial pneumonia (viral pneumonia), Pericarditis, Pneumonia (bacterial pneumonia), and Pleurisy.

## Regional anatomy of the heart

The heart is suspended by great vessels and located on the left median mediastinum of ventral thorax. The left side of the heart apex reaches the chest wall. The percussion examination in all animals is the same in cranial and dorsal border.

**Cranial limit:** Cranial limit is the caudal border of the triceps, from the caudal angle of the scapula to the olecranon of the radius bone in standing animals.

**Dorsal border:** Dorsal border is on the line, which runs from caudal angle of the scapula to the tuber coxae of os coxae bone.

**Basal border:** Basal border is from olecranon of the radius to the last intercostal space at the dorsal border. The basal border line is straight in cattle but is concave in horse and dog.

In case of ox, the basal border of the lungs runs in almost straight line from the sternal end of the 6<sup>th</sup> rib to 11<sup>th</sup> intercostal space at dorsal border. In horse, the basal border of the lungs runs in a strong curve from the sternal end of the 6<sup>th</sup> rib through the middle of the 11<sup>th</sup> or 12<sup>th</sup> intercostal space and onto the vertebral end of the 16<sup>th</sup> intercostal space. In dog, the basal border of the lungs runs in a strong curve from the sternal end of the 6<sup>th</sup> rib to the 11<sup>th</sup> intercostal space.

## Topographic location of the heart

**Ox:** The heart extends from 3<sup>rd</sup> to the 5<sup>th</sup> or 6<sup>th</sup> rib. Five seventh of the heart lies to the left of the median plane and it is in contact with the left thoracic wall between the 4<sup>th</sup> and 5<sup>th</sup> intercostal spaces. Heart auscultation is restricted to a small area near the olecranon.

**Horse:** three fifth of the heart lies to the left of the median plane and in direct contact with the left thoracic wall in the region of 4<sup>th</sup> and 5<sup>th</sup> rib, auscultation and percussion can be done on the left side between the 3<sup>rd</sup> and 5<sup>th</sup> intercostal space.

**Dog:** about fourth seventh of the heart lies on the left side of the midline. It occupies the thoracic space between the 3<sup>rd</sup> and the 7<sup>th</sup> rib and between the sternum and half the height of thoracic cavity.

For clinical observation, it is necessary to pull forward the fore limb, by doing so the heart is felt in the lower third of

the chest between 4<sup>th</sup> and 6<sup>th</sup> ribs, especially the 5<sup>th</sup> intercostals space. And also anatomy location of heart is summarized in Table 2.

After locating the heart the following should be noted through physical examination (palpation, percussion, auscultation) the following would be examined [1,5,6] (Table 2).

- \* Heart rate
- \* Abnormal variation in heart rate
- \* Heart sounds
- \* Normal heart sounds (dub-lab)
- \* Adventitious heart sounds (murmurs)
- \* Pericardial frictional sounds
- \* Venous pulsation (jugular pulsation)

#### Anatomical locations of valves<sup>5</sup>

- ✓ Mitral valves: Examined on the left side in the 5<sup>th</sup> intercostals space, 4 inches above the sternal extremity of 5<sup>th</sup> rib.
- ✓ Tricuspid valves: Present on the right side in the 3<sup>rd</sup> intercostals space and 3 inches above the sternal extremity of the 4<sup>th</sup> rib.
- ✓ Aortic semi-lunar valve: Present on the left side in the 4<sup>th</sup> intercostals space level with the shoulder point [5].

### Examinations Digestive System

The clinical examination of digestive system is to check the normal motility and rate of abdominal normality in domestic animals<sup>9</sup>. The examination of digestive system of animals may start from mouth into rectum. The examination which applied over mouth, esophagus can show the manner of regurgitation, mastication, prehension and etc. Regurgitation in ruminat or other animals may rise from different abnormality like: Megaoesophegus, Oesophegitis, Pharyngeal paralysis, obstruction or pharyngitis and Hypomagnesaemia. The abnormality of prehension which mean when animals fail to take food by their mouth is caused by the following diseases:

- \* Tetanus
- \* Trauma in the jaw or mandible

- \* Stomatitis
- \* Glossitis
- \* Foreign body in the mouth
- \* Actinobacillosis
- \* Actinomycosis
- \* Foot and mouth disease

Pica is the most common abnormal behavior of animals, it is usually due to nutritional deficiencies and it may be manifested in the form of eating of abnormal or unusual diet of large ruminants, excessive licking or urine drinking. This abnormality may rise from:

- ✓ Rabies
- ✓ Actinomycosis
- ✓ Water deprivation
- ✓ Salt deficiency
- ✓ Lack of roughage
- ✓ Hypophosphatemia
- ✓ Ketosis (acetonemia)

Excessive salivation results either from excessive production of saliva, dysphagia or as a response of painful condition in the oral cavity. It is caused by:

- ✓ Hypomagnesaemia
- ✓ Esophageal obstruction
- ✓ Stomatitis
- ✓ Lead poisoning
- ✓ Foot and mouth diseases
- ✓ Pharyngeal paralysis or pharyngitis
- ✓ Calf diphtheria
- ✓ Esophageal obstruction
- ✓ Paralysis or esophegitis.

Swallowing or deglutition means that transportation of masticated food from the oral cavity to the stomach through the pharynx and esophagus. However, when animals fail to swallow clinically it is called as dysphagia, dysphagia can be caused by esophageal and pharyngeal disease (obstruction, inflammation and paralysis).

### The examination of rumen, reticulum and omasum

Examination of rumen can be performed by inspection, palpation, percussion and auscultation; stomach tube can be used as well. In bloat case, the left side would be bulged, and

**Table 2:** Anatomical location heart in equines and ruminants [5].

Area	Equines	Ruminants
Base	From 2 <sup>nd</sup> to 6 <sup>th</sup> intercostal space	From 3 <sup>rd</sup> to 6 <sup>th</sup> rib
Apex	Half an inch from the last sternal	One inch from the diaphragm segment
Posterior border	Opposite to the 6 <sup>th</sup> rib	Opposite to the 5 <sup>th</sup> rib
Left surface	Composed of left ventricle and extends from 3 <sup>rd</sup> to 6 <sup>th</sup> rib	Extends from 3 <sup>rd</sup> to 4 <sup>th</sup> rib
Right surface	Extends from 3 <sup>rd</sup> to 4 <sup>th</sup> rib	Not examined

the motility would be decreased. The reticulum is a pouch-like structure in the forward area of the body cavity. It is the most cranially situated compartment of the stomach apposite to 6–8th intercostal spaces on the left side of the abdomen. It is known as honeycomb for it arranged in network resembling honeycomb. A small fold of tissue lies between the reticulum and the rumen, but the two are not actually separate compartments.

The reticulum lies close to the heart (<https://www.extension.umn.edu>). The reticulum is examined for the presence of foreign object lodge in honeycomb appearance tissue and the method is by backgrasp, below pole lifting, up and down hill leading, hand palpation. The examination of omasum and abomasums is done by exploratory puncture. Abomasum has 'U' shaped structure laying on the abdominal floor on the right side opposite to 7–9th ribs or intercostal spaces. Abomasum can produce sound like "tinkling or high pitched metallic sound" once per 15 minutes and can be stimulated by tactile percussion over the abdomen. Abomasal movement may be absent in case of abomasal displacement (right or left), Impaction, abomasal ulcers. The examination of the displacement of abomasums is done by inspection, palpation, and auscultation.

The disorder of stomach can be detected by taking stomach contents sample. Insert the stomach tube or nasal tube after cleaning, disinfecting and lubrication or trocarisation.

**Palpation of rumen:** When touching rumen with fist or hand, in normal animal it gives resilient palpation. However in abnormal case it produces the following:

- ✓ *Doughy palpation: impaction*
- ✓ *Emphysematous palpation: tempany*
- ✓ *Painful palpation: peritonitis, traumatic reticulitis*

**Auscultation of rumen:** It is the procedure by which checking the sound which produced from rumen by stethoscope. Normally "Gurgling or Booming" sound in the normal rate of 2–5 / 2 minutes, the sound occurred due to the movement of the fluid and food particles in the rumen. The abnormal auscultation of rumen reveals that, the sound which varies from normal it is in case of:

- ✓ Increased ruminal sound: Early stage of diarrhoea, early stage of tempany vagal indigestion and Esophageal obstruction.
- ✓ Decreased ruminal sound: Ketosis (acetonemia), Febrile condition, Vagal indigestion Mild impaction, Abomasal displacement, Simple indigestion and Traumatic reticulitis
- ✓ Absent of ruminal sound: Acute impaction, Sever tempany, Abomasal impaction, Diaphragmatic hernia, late stage of vagal indigestion, Ruminitis and Sugar beet arsenic or organophosphorous poisoning.

**Ruminal atony and lack of rumination:** It is a condition which characterized by lack of ruminal movement and lack of rumination together with decrease of food intake and decreases the amount of faecal matter output. It is caused by the following abnormality (<http://www.bu.edu.eg>):

- ✓ Acidosis or alkalosis,
- ✓ Vagal indigestion
- ✓ Abdominal pain
- ✓ Sudden change in the diet,
- ✓ Ruminal tempany and impaction
- ✓ Traumatic reticulitis
- ✓ Prolonged oral use of sulphonamide and antibiotics.

#### **Causes of distended or increased sized abdomen:-**

In examination of abdomen of animals, abnormal shaped abdomen in large ruminants may be either by increased sized (distended) or reduction in the size of the abdomen. This abnormality can be caused by:

- ✓ **Distention of abdomen or increased sized abdomen:** Abomasal displacement, Tempany, Ascitis or liver diseases, Impaction, Urine retention, Pyometria, Normal after heavy meal or in the late stage of pregnancy.
- ✓ **Decreased sized abdomen:** Pyelonephritis, Sever diarrhea, TB and liver abscess, Starvation and malnutrition or deficiencies

#### **Rectal examination of internal abdominal structures**

The internal abdomen like intestine and some organs can be examined in large animals through rectum. The method and procedure for rectal palpation is by making cut and smooth the nail; wear shoulder long glove; lubricate; cone shape of the fingers; insert in rotating way; notice: the hand cannot open, or even grasp organs inside. It's necessary or possible to use tranquilizer to reduce the sensitivity of the rectum in horse. In bloat case, the pressure in the abdomen would be very high, so it would be difficult to insert the hand inside.

The pathological condition occurring in the ruminant and other domestic animals ruminant are listed as following [1]:

- ✓ **Reticulum**– actinobacillosis/actinomycosis infection of the oesophageal groove, neoplasia of the oesophageal groove, reticular abscess, reticuloperitonitis.
- ✓ **Rumen**– secondary free gas bloat, frothy bloat, ruminal acidosis, cold water ruminal atony, neoplasia of rumen, rumen collapse syndrome, rumen foreign body, rumen impaction, vagal indigestion.
- ✓ **Omasum**– omasal impaction.
- ✓ **Abomasum**– right abomasal dilatation and torsion,

abomasal rupture, left abomasal displacement, abomasal impaction (dietary), abomasal ulceration, abomasal neoplasia.

- ✓ *Small intestine* – Johne's disease, salmonellosis, winter dysentery, bovine virus diarrhoea, gut tie (intestinal strangulation), foreign body intestinal obstruction, intussusception, neoplasia of small intestine, prolapse of the intestines through the mesentery, torsion of the root of the mesentery, small intestine rupture post calving, spasmodic colic.
- ✓ *Large intestine* – caecal dilatation and torsion.
- ✓ *Rectum* – rectal perforation, rectal prolapsed
- ✓ *Abdomen/peritoneum* – ascites, uroperitonium, fat necrosis, focal or diffuse peritonitis, acute pneumoperitonium.
- ✓ *Liver* – abscessation, hepatitis, cholangitis, Fasciolosis

Auscultation of the rumen help in recognizing the rate, quality and rhythm of the normal ruminal movements. The ruminal movements arise from the churning action of the organ. The rate of ruminal movement in health animals is 2-5 in cattle, 3-6 in sheep, 2-4 movements every two minutes in goats. It decreases in cases of rumen atony; diseases of reticulum, omasum and abomasum; impaction and late stage of tympany; also in severe feverish conditions and in traumatic reticuloperitonitis. Increased rate is seen in early stage of digestive disorders such as tympany and the form of vagus indigestion with hypermotility [1].

**Absence of rumen movements is occurred by the following causes [1,5]:**

- ✓ Severe dilation of the rumen with gases (tympany) or with food (impaction).
- ✓ Toxic conditions.
- ✓ The quality could be described as strong in healthy animals, weak in cases of ruminal atony and very strong as in early stages of digestive disorders such as tympany and vagus indigestion with hypermotility.

Constipation is the abnormality in movement of faeces in intestine of animals; it is occurred when there is reduction in the movement of alimentary tract resulting in passage of small hard amount of faecal matter. It may also associate with tensmus or straining (sign of pain when there are problems in the pelvic cavity, alimentary tract or urogenital organs. The major causes of constipation are like:

- ✓ Fever
- ✓ Tetanus
- ✓ Septicemic conditions
- ✓ Zinc poisoning

- ✓ Ruminal atony
- ✓ Traumatic reticulitis
- ✓ Lack of water Indigestion
- ✓ Ketosis (acetonemia)
- ✓ Abomasal impaction
- ✓ Hepatitis
- ✓ Abomasal displacement (right)
- ✓ Ruminal impaction
- ✓ Tapeworm infestation

Colic is an abnormal or the sign of disease of intestinal, it is common in horse and also ruminant animals. Signs of colic in large ruminants in the form of restlessness, kicking of the abdomen, or rising and laying down frequently are similar to that of horses but in horse are clearer than that in large ruminants. It is cause by:

- ✓ Peritonitis
- ✓ Traumatic reticulitis
- ✓ Abomasitis
- ✓ Omasal or abomasal impaction
- ✓ Ruminal tempny
- ✓ Abomasal displacement
- ✓ Impaction (lactic acidosis)
- ✓ Hepatitis
- ✓ Cystitis
- ✓ Traumatic pericarditis
- ✓ Urolithiasis
- ✓ Obstruction of intestine of horse
- ✓ Parasitic obstruction of intestine

Diarrhea: when faeces of animals become water due to some disease, it is most common problem in large ruminants and there are many factors that affecting in the type of diarrhea according to age of the animal, physical conditions of the animal, feeding system, aim of breeding, infectious agents (virus, bacteria, protozoas well as physical causes of diarrhea .

**The major causes of diarrhea in young calf are as:**

- ✓ Coccidiosis
- ✓ Colibacillosis
- ✓ Salmonellosis

- ✓ Sodium chloride poisoning
- ✓ Copper and vitamin A deficiency
- ✓ Lead, mercury and nitrate poisoning
- ✓ Dietary scour due to bad feeding management
- ✓ Rotavirus
- ✓ Parvovirus
- ✓ Enterovirus

#### *Causes of diarrhea in adult and growing animals:*

- ✓ Lactic acidosis (ruminal impaction)
- ✓ Fasciolosis
- ✓ Salmonellosis
- ✓ Coccidiosis
- ✓ Antibiotic induced diarrhea
- ✓ Aflatoxicosis
- ✓ Parasitic gastroenteritis
- ✓ Ecoli
- ✓ John's disease ( no blood, no mucous membrane, only dark watery diarrhea)

#### **Examination of the urogenital system**

In the horse and cow only the left kidney is accessible for palpation from the rectum. The right kidney lies further forward and cannot be reached by the hand. In the horse, the left kidney extends back to about four inches behind the last rib and its inner border is separated from the median line by about the same distance. In ruminants, it is loosely suspended below the lateral processes of the first lumbar vertebrae. Sometimes it may be shifted over to the right side. In dogs the kidneys lie in the lumbar region.

The manifestations of the urinary tract diseases include abnormal constituents and appearance of urine, changes in the volume of daily urine flow and frequency, pain and dysuria and uremia<sup>6</sup>. Examination of urogenital examination is important to identify the regional anatomy, undertake clinical and physical examination of urinary system and assess urinary abnormalities, perform clinical examination of female and male reproductive organs as well as the mammary glands and teats. Identify the anatomic structure of the kidney on live animal: the left kidney is located ventral of the transverse process of the 3<sup>rd</sup> to 5<sup>th</sup> lumbar vertebrae. Normally left kidney its position varies according to the degree of fullness of the rumen as when the rumen is fully distended, the left kidney present ventral to the transverse process of 5 and 6<sup>th</sup> lumbar vertebrae. While when the rumen not distended, the left kidney lies ventral to transverse process of 1, 2 or 3<sup>rd</sup> lumbar vertebrae. Normally

right kidney present ventral to transverse process of the 2, 3<sup>rd</sup> lumbar vertebrae. The kidney can be examined by inspection, external palpation, rectal palpation, and urinalysis. The examination of the urinary bladder is performed by stimulating the sense of urination from the lower part between the two hind legs on small animals or rectal palpation on large animals. Attention should be paid to the paralysis of the bladder and retention of urine and rupture. During palpation the size of kidney may increase due to neoplasm, hydronephrosis, acute nephritis and pyelonephritis, But the size is decreased due to dehydration and advanced chronic interstitial nephrosis<sup>6</sup>.

- \* Take the sample of urine examine through physical methods
- \* Fresh urine is collected with test tube after stimulating urination by palpating the perineal region or by inserting catheter
- \* Clinical examination of the mammary glands and teat- inspection and palpation to detect the presence of swelling and lesions on the teats/decrease in size and shape, any discharge, temperature of the udder, consistency, and pain reactions are performed.
- \* Clinical examination of milk samples: after collecting the milk samples in clean test tubes one can apply different physical and laboratory examinations
- \* For the gross examination of the milk, the change of the color, odor, viscosity and flakes in the milk should be identified.

External palpation of the kidneys in the horse is not performed due to the considerable thickness and rigidity of the abdominal wall. Kidneys can be palpated through the abdominal wall in the majority of small and medium sized dogs. In sheep, goat and pigs, external palpation of the kidneys is of little value. In the cat, kidneys are large and pendulous therefore easily palpable. Identification is aided by recognition of the hilus on the attached border. In cattle, rectal palpation may help in examination of the kidneys<sup>1</sup>.

#### **Abnormality which associated with urinary system are as:**

**Frequency of urination:** Frequency may increase due to: cystitis, calculi (incomplete obstruction), increase the fluid intake especially in winter, injection of diuretic. However, frequency of urination can be decreased in case of dehydration, urethral obstruction, and diarrhea.

**Anuria and dysuria:** Anuria is complete absence of urination which may be associated with painful urination (dysuria), while stranguria means that dripping of urine as in case of cystitis, urethral calculi, urethritis, spinal cord trauma and hemorrhage into urinary tract.

**Haematuria:** Presence of blood in the urine due to blood parasite, hypophosphatemia, pyelonephritis, systitis, trauma in the kidney or urethra, urolithiasis, and inappropriate use of urethral catheterization.

**Pyuria:** Presence of pus in the urine due to inflammation lesion in the pyelonephritis, abscesses in kidney and urethra.

### Examination of reproductive system of animals

Clinical examination of male genital organs, visual inspection and palpation are employed to examine the testes, prepuce and the penis after withdrawing from the prepuce. The abnormality which observed from male genital are like orchitis, cryptorchidism, scrotum hernia, obstruction of urethra by calculi, phimosis, paraphimosis, inflammation of the prepuce, testes and penis are noted<sup>1, 2, 7</sup>. Clinical examination of female genital organs, visual inspection and palpation of the vaginal region, use of vaginal speculum to examine the inside of vagina and intra-rectal examination of the cervix, uterus and ovaries would be performed [1,2,4].

#### The procedures of rectal palpation:

- First of all restraining of animals( cow): by approaching from rear and tail is grasped firmly about midway of its length, the animal may jump from side to side as the hand is inserted into the rectum. The veterinarian or technician must be move readily from one side to other with the cow.
- Preparation of safety: the arm must be covered with plastic sleeve with lubrication. Hand is inserted by forming the thumb and fingers into a cone tip and with a slight rotary motion, forcing into rectum. When hand is inserted, there may wave of peristaltic contraction will encountered from rectal wall.
- If the animal show defecation, the clinician or technician should have to expel it from rectum, then the floor of rectum is depressed with the hand which has been inserted half way to the elbow.
- The genital tract should be lie just below and wholly on the floor of the pelvis. The whole part of genital tract may be contracted and lying in the caudal part of pelvic canal, genital tract s position may vary forward until uterus is hanging over the brim of the pelvis into the abdominal cavity, but with only the vagina and cervix in the pelvic canal.
- The abnormality which is present in diseased animals are like:
  - Pyometra
  - Tumor and abscesses in the retroperitoneal tissues around the vulva and vagina.
  - Cervix will appear a firm, rope like structure, cervix may feeling like aturkey neck which mean long.
  - A pedunculous uterus, if empty may pulled up into pelvic canal.
  - Cervix ordinarily lies along the middle of the pelvis, directly under rectum and above bladder. But, if bladder

is full with urine, the remain part of cervix is present in pelvic canal, reproductive tract. Particularly, cervix, may lie over on the right side of the pelvis and wedge in between the bladder and wall of the pelvis.

- The cervix ordinarily lies along the midline of the pelvis, directly under the rectum and above the bladder. But if the bladder is full and remains in the pelvic canal, the reproductive tract, particularly the cervix, may lie over on the right side of the pelvis and be wedged in between the bladder and the wall of the pelvis.

Examination for pregnancy involves palpation of the uterine horns to determine size differences and then later the presence of fetal membranes, cotyledons and increased blood flow in the uterine artery. The palpation of ovary is started from the position where the hand is placed over the coiled uterine horns. The ovaries are palpated to detect the presence and size or degree of developments of follicles and corpora lutea. The ovary, when picked up under the edge of the broad ligament is turned up and backward on the top of the broad ligament for examination. It is held in a transverse position with the free edge of the ovary toward the examiner and the mesovarial edge away from the examiner. The attached end of the ovary (end to which the bursa is attached) is lateral. The determination of size and location of ovarian structures requires measurement with the finger tips and the consistent orientation of the ovary with respect to the body wall; also the identification of the structure as being in certain defined regions of the ovary. Finger widths constitute a rough unit of measurement. There are about nine regions of the ovary; they are upper surface, lower surface and greater curvature along free margin. Each of these has right, left and middle regions.

### Examinations of the nervous and musculoskeletal system

An animal can response to change in the environment and complete linking of the different in the body that this response is called coordination. There are two types of coordination system; they are like nervous and endocrine system. The nervous system also classified into central and peripheral nervous system. The interaction of nervous and muscular system aids the animals to stand, walk and coordinating with its environment. The examination of nervous and musculoskeletal system is to detect the clinical signs of various problem associate with these systems.

#### Observation the behavior of the animal and checking the responses of the animals while applying different stimuli:

- Examine the brain by corneal reflex, the pupil reflex.
- Examine the spinal cord of the neck and thorax by withers reflex.
- Examine the spinal cord of the back part by applying hoof stimuli and anus stimuli.
- Move the animal to and from or uncomfortable position to examine the locomotors.



- Examine the joints long bones and different muscles: arthritis, dislocation of the joints, rickets or osteocalcin, muscular atrophy, central or peripheral origin paralysis [1,2].

### Examination of skeletal muscle of an animal

The musculoskeletal system is composed of the bones of the skeleton, joints, ligaments, muscles and tendons. In addition to the nervous system, the musculoskeletal system is important for the maintenance of posture and for locomotion. The aim of the clinical examination is to identify the site and the cause of the lameness. Identification of the affected limb, the site of the lesion within the limb and assessment of the severity of the lesion, are primary aims of the initial part of the examination. Localization to a foot or an upper limb problem may be possible by observation. Abnormalities of posture and gait, weight bearing and gross swellings, wounds and deformities should be noted. Posture means the anatomical configuration of animals when they remain standing. And sitting in other words, it means how the animal stands and sits. Postural abnormalities can be of great help in making a diagnosis (Table 3).

**Gait:** Gait is denotes the locomotor processes of the animals. A locomotor disturbance of the animal is judged by the movements (Walking, running, trotting, circling etc.). There are certain diseases, which interfere with the process of locomotion (Table 4). The gaits of the dog are commonly used patterns of locomotion that can be divided into two main groups: symmetric and asymmetric. With symmetric gaits such as the walk, trot, and pace, the movement of the limbs on one side of the dog's body repeats the motion of the limbs on the opposite side with the intervals between foot falls being nearly evenly spaced. With asymmetric gaits such as the gallop, the limb movements of one side do not repeat those of the other and the intervals between foot falls are unevenly spaced. When considering gaits, one full cycle is referred to as a stride [8].

### Examination of superficial lymphnodes of animals

Examination of superficial lymphnode istocompare each paired node for size and consistency with the contralateral node. Grossly enlarged lymph nodes may have been seen during observation of the patient before it is handled. Observation and palpation is possible when the animal is restrained. Normal characteristic of lymphnode can be identified as ther following:

- \* Size: lymphnode vary greatly in large animals, but it is larger in young animals than adult.
- \* Consistency: firm on palpation
- \* Surface: lobulated in large lymphnode and smooth surface
- \* Temperature: it takes the normal skin temperature
- \* Pain: painless on palpation
- \* Skin: movable freely over surface of examined lymph node

**Table 3:** Abnormal posture in domestic animals.

Animals	Site of pulse taking
Equine	<b>External maxillary artery</b> Transverse facial artery Median artery Great metatarsal artery
Cattle and pig	<b>Middle coccygeal artery</b> Facial artery Median artery
Sheep, Goat, Calf	Femoral artery.
Piglet, Dog and Cat	Femoral artery.

**Table 4:** Abnormality of gait in domestic animals.

Gait	Disease
Lameness and disinclination to move	Laminitis, foot rot
Stiff gait	Arthritis
Walking in circles / head pressing	Gid (Coenuruses)/otitis/ listeriosis
Dragging of the hind leg	Subluxation of medial patellar ligament

- \* Movement: mobile in relation to the neighboring tissues

### Anatomical Location of lymphnodes (LN):

Lymph nodes are round or bean-shaped structures that are widely distributed throughout the body. Lymph node are Imbedded in connective tissue or fat, which concentrated in cervical, axillary, and inguinal regions of neck, armpits, and groin, respectively. They are typically less than 1/2 inch in length, depending on the size of the animal. The lymph nodes filter the lymph before returning it to the veins [1,9].

**Submandibular lymph nodes:** situated and are palpable on the medial aspect of the 'angle of the jaw' where the horizontal and vertical rami of the mandible meet. (Normal size is 1.5 to 2 cm)

**Prescapular lymph nodes:** It lies subcutaneously and underneath the cutaneous muscle just anterior to the shoulder joint (Normal size 1 cm × 3.5 cm)

**Axillary lymph nodes:** Found on each side of the chest in the armpit area. Normally only palpable in young calves without heavy muscling (Normal size 1.5 cm)

**Popliteal lymph nodes:** These nodes are found surrounded by dense muscle tissue immediately behind the stifle. It found on each rear leg on the opposite side of the knee. They are relatively superficial and easy to feel (normal size 1-1.5 cm)

**Inguinal lymph nodes:** These are usually palpable as a small group of fairly mobile and firm structures adjacent to the inguinal canal. (Normal size 0.5 cm)

**Supramammary lymph nodes:** These are normally readily palpated on the caudal aspect of the udder just above the upper limit of the mammary glandular tissue, normal size 2.5 cm [4,10] (Figure 1).

Abnormalities of lymph node in large animals may be enlarged and inflamed by disease like: Blood parasites, Actinobacillosis, 3 days fever [ephemeral fever], caseous lymphadenitis (corynebacterium) or edematous skin disease and epizootic lymphangitis, mastitis.

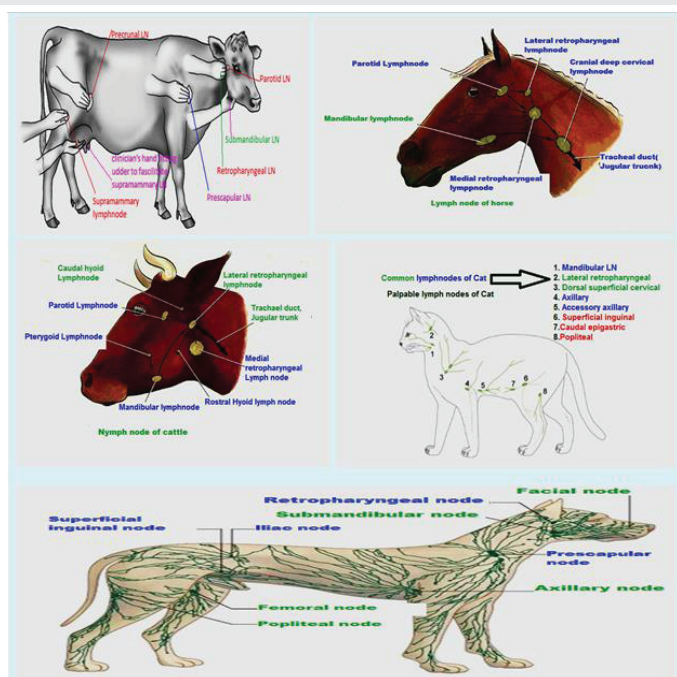


Figure 1: Anatomical location of animals node.

## References

- Jackson P, Cockcroft P (2002) Clinical Examination of Farm Animals. Blackwell Science, UK.
- Radostits OM, Gay CC, Hinchcliff KW, Constable PD (2007). Veterinary Medicine: A textbook of the diseases of cattle, sheep, pigs and goats, horses. 10th edn. St. Louis: Saunders (Elsevier).
- Radostits OM, Mayhew IG, Houston DM (2000). Veterinary clinical examination and diagnosis. London: WE Saunders
- Duguma A (2016). Practical Manual on Veterinary Clinical Diagnostic Approach. J Vet Sci Technol 7: 337. doi:14.4172/2157-7579.1000337
- Chauhan RS, Agarwal DK (2008) Textbook of Veterinary, Clinical and Laboratory Diagnosis. 2nd edn. Jaypee Publishers, New Delhi, India.
- Internal medicine: website available at: <http://www.aun.edu.eg/developmentvet/Internal%20medicine/amly3.htm>
- Ajello, S.E. (1998). The Merck Veterinary Manual, 8th edition, Published by Merck and Company, INC, USA
- Nunamaker, D. M., and Blauner, P. D. (1985). Normal and abnormal gait. Textbook of small animal orthopaedics, 1083-1095.
- Kahn CM (2010): Merck Veterinary Manual. 10th edn. Whitehouse Station, Merck, NJ, USA.
- Griffin, Dicky D.; Smith, David R.; and Grotelueschen, Dale M., "G98-1351 Proper Injection Procedures for Cattle" (1998). Historical Materials from University of Nebraska-Lincoln Extension. Paper 349.
- Electronics
- [http://vet.uga.edu/oldvpp/programs/afvet/attachments/reproductive\\_pathology.pdf](http://vet.uga.edu/oldvpp/programs/afvet/attachments/reproductive_pathology.pdf)
- [http://www.bu.edu.eg/portal/uploads/Veterinary%20Medicine/Animal%20medicine/3468/crs\\_11347/Files/mohamed%20zain%20eldein\\_Examination%20of%20Large%20Ruminant.pdf](http://www.bu.edu.eg/portal/uploads/Veterinary%20Medicine/Animal%20medicine/3468/crs_11347/Files/mohamed%20zain%20eldein_Examination%20of%20Large%20Ruminant.pdf)