



Aysegul Firat^{1*} and Fadime Irsel Tezer Filik²

¹Hacettepe University Faculty of Medicine
Department of Anatomy, Ankara, Turkey

²Hacettepe University Faculty of Medicine
Department of Neurology, Ankara, Turkey

Dates: Received: 16 December, 2016; Accepted: 29 December, 2016; Published: 30 December, 2016

***Corresponding author:** Aysegul Firat, Hacettepe University Faculty of Medicine Department of Anatomy, Ankara, Turkey, Tel: +90(312)3052132; Fax: +90(312)3107169; E-mail: aysfirat@hacettepe.edu.tr

Keywords: Corpus callosum; Tractography; Interhemispheric connections

<https://www.peertechz.com>

Mini Review

Morphometry of the Corpus Callosum

Abstract

Corpus callosum (CC) is the largest fiber pathway linking the two cerebral hemispheres of the brain. These connections through the CC are either homotopic that connect the same or similar areas on each hemisphere or heterotopic that connect functionally similar, but anatomically different areas in two hemispheres. That means it plays an important role in integration and communication of hemispheres. As having morphological differences among people, being a structure that completes its myelination later and because of its functional importance, it appeal to researchers. The aim of this review was to evaluate the functional anatomy of the CC. By the use of tractographies and functional MRIs, topographic organization of CC and the effect of neurodevelopmental and neurodegenerative processes may be well understood.

Introduction

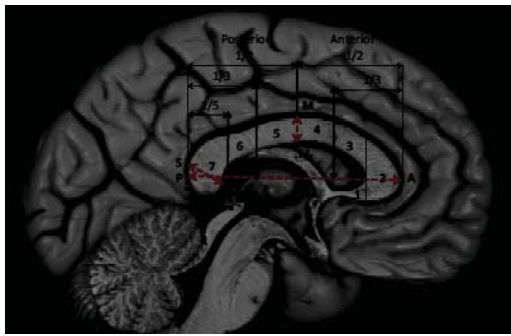
The corpus callosum (CC) is the largest interconnection between the brain hemispheres. The interhemispheric connections through the CC may connect functionally same or similar areas in the hemispheres. Nowadays by the help of the higher imaging techniques it has been shown that these fibers exhibit a topographic organization [1]. In the literature CC is examined in details according to its dimensions, parts, morphology, age and gender differences and also according to the changes related to the neuropsychiatric diseases [1-7]. It has now been accepted that the morphological change of the brain development is affected by growth, development, aging, environmental factors and diseases [8,9]. The CC is one of the very important structures that is affected by these factors and these changes appeal to researchers [1-4]. In this review, we will investigate the significant studies related with the morphological differences and changes of the CC.

In classical anatomy textbooks [10], CC is divided into five parts: rostrum, genu, body, isthmus and splenium. Fibers of the CC have a topographical organisation based on structural connectivity. Map of these cortical tracts within the CC can be obtained by in vivo imaging techniques [1,11]. But borders of the topographies, number and diameter of the fibers in each tract, accurate route of the fibers cannot be evaluated by now. These topographical maps might help us to understand the effects of damage on CC in neurodevelopmental and neurodegenerative diseases.

Increased total callosal area would be because of myelination, fiber thickness, increased density of fibers and increased number of fibers. When we consider the development

of CC, it has been established that there was not an increase in the number of fibers after birth. Controversial to that, during this period there has been a decrease in the number of axons because of some regressive reasons. This developmental callosal analysis was declared by Koppel and Innocenti [12], by a quantitative electron microscobic study in the cat and by LaMantia and Rakic [13], in the developing rhesus monkey. According to these studies during the early postnatal life, in both rhesus monkey and cat, there is a loss of callosal fibers; lasting at least for 3 or 4 months postnatally. Now we know that this process might extend beyond the first year of life in human [8,9,14].

Especially by the developing imaging techniques like functional magnetic resonance imaging (fMRI), many studies related with the fiber organisation and functional anatomy of the CC have been produced. Zarei et al. [1], used diffusion tensor imaging (DTI) tractography to produce a two-dimensional map of the CC of 11 right-handed healthy subjects in the mid-sagittal plane. By using DTI tractography they observed an antero-posterior topography of interhemispheric connections within the CC and compared volumes between hemispheres. In this study, cortical connections were successfully traced within CC in all subjects and they found the antero-posterior locations of the connections: connections of the prefrontal cortex were located within the genu and anterior part of the body; premotor followed by motor and sensory connections were located in the midbody region; parietal, temporal and occipital connections were located at posterior parts of the CC in orderly (Figure 1). They have found no effect of hemisphere and gender for absolute CC volume. Wahl et al. [11], also have found results that are in agreement with other previous DTI studies examining



Areas of the CC: 1 Rostrum, 2 Genu, 3 Anterior body, 4 Midbody, 5 Posterior body, 6 Isthmus, 7 Splenium

Figure 1: Topographical parts of the CC.

callosal topography. Wahl et al. [11], have demonstrated that novel MRI and tractographies can be effectively combined to investigate the link between structure and function *in vivo* in human subjects. Their results suggest that the role of the CC in interhemispheric integration, as it relates to structure, should be re-examined in light of the new approaches to studying the morphometry and morphology of the CC like transcranial magnetic stimulation technique.

This map may be useful in the study of interhemispheric interactions as well as the study of neurodegenerative disorders. Hynd et al. [6], studied morphology of CC of the MRIs of dyslexic children. Analysis of the corpus callosum revealed that the anterior region of interest (the genu) was significantly smaller. Moreover significant correlations existed between reading achievement and the region-of-interest measurements for the genu and splenium. Measured intelligence, chronologic age, and gender were not related to region-of-interest measurements of the corpus callosum in this study. Wang et al. [5], studied magnetic resonance images of the corpus callosum in adolescents with Down and Williams syndromes. They have found a distinct rounded CC and decreased width of rostrum from the MRIs of Down syndrome adults. CC of subjects with Williams's syndrome generally resembled the control group. In another study Yamauchi et al. [7], studied the pattern of atrophy in frontotemporal dementia, progressive supranuclear palsy, and Alzheimer's disease. In this study they have found that atrophy of the corpus callosum was not specific to any degenerative dementia, the patterns of the atrophy are different among patients with FTD, PSP, or early onset AD. They revealed that the patterns of callosal atrophy might reflect characteristic patterns of neocortical involvement in each degenerative dementia.

Witelson [2], has studied the hand and sex differences in the human CC in a postmortem morphological study. In this study, she has subdivided the midsagittal surface of the callosum into seven regions, roughly approximating the topography of callosal fibres in relation to their cortical fields of origin and termination. This possible functional organisation has been supported by many animal and clinical experiments previously and also by developing imaging techniques like fMRI nowadays [1,15-19]. Witelson [2] was measured midsagittal area of the CC in 50 autopsy brains. They found sex differences in many aspects of CC anatomy:

1. Handedness was a factor in callosal size in males and this result was consistent with the general hypothesis of females having less clear lateralization than males,
2. Females did not have a larger CC or a larger splenium,
3. Among all the CC regions, only the genu and the anterior body region were found to be larger in absolute size in males,
4. CC size decreased with aging in males but not in females.

Although isthmus and posterior body regions showed a significantly greater area in, the mean area values were tended to be larger in all seven subregions in left handers. In one region, the isthmus, the absolute area tended to be larger in females. Left handers have a greater prevalence and a greater degree of bihemispheric representation of language and spatial conceptual skills. This situation requires greater interhemispheric communication for greater bihemispheric functional representation. In this study, only the isthmus was larger in females with right handers.

In almost all studies males were tended to have larger callosal sizes [2-4]. Whether there are gender differences in the size or the morphology of the CC is still a question. In spite of all these discussions; De Lacoste-Utamsing and Holloway [20], have measured the midsagittal callosal area in 14 postmortem brains and they found that females had greater CC. This difference was prominent in splenium and they explained the situation as a result of the cognitive and speech abilities of women. Holloway and De-Lacoste [21], have repeated the same study (n=16) and they have found that genu, anterior body and total area of CC were greater in men and isthmus was greater in women when compared with right-handed men. Hand preference did not make any difference among women and there was a decrease in size in men with aging. But in both studies number of the groups were very small and this was decreasing the valubility of the results.

Berberi et al. [22], studied total callosal area, perimeter and thickness of the CC in newborn rats. They found that all measurements were greater in male brains. One group of rats was handled 110 days, other group was handled for 215 days in the same study and the results were compared with a control group. At 110 days handling stimulation increased callosal parameters and resulted in a more regular CC in males, but this effect was no longer apperent in 215 days. Within the CC region specific effects were found, suggesting that certain fibers of CC were involved. It has been shown that animals given extra stimulation in early life have more lateralized brains [23,24]; thus at least in this experiment, increased callosal size and regularity is associated with greater hemispheric specialisation. Denenberg et al. [23,24] has postulated in his study that handling stimulation increases the size of the CC and this increase means more competition between the hemispheres which result in laterality.

All these studies provide evidence that the morphometry of CC is important in the diagnosis of many neurological diseases.

It has been discussed that these measurements might also be related to with the impairment of functional interactions both within each hemisphere and between the two hemispheres. The degree of the impairment diminishes the cognitive, verbal and executive performances. In the clinical trials normal and pathological developmental processes and effects of some diseases on these processes very striking subjects. White matter is essential for impulse conduction, for that reason the white matter plasticity widens the area of research beyond the electrophysiology in the absence of pathology. But much work needs to be done to explore these interesting networks. This includes determining the nature of the white matter structural changes in both normal processes and in the pathological processes in the next years. Imaging and cellular and molecular modalities reveal that white matter changes with possible functional and psychological disorders are important for the normal CC function and for the clinical conditions.

References

- Zarei M, Johansen-Berg H, Smith S, Ciccarelli O, Thompson AJ, et al. (2006) Functional anatomy of interhemispheric cortical connections in the human brain. *J Anat* 209: 311-320. [Link: https://goo.gl/a8AWrk](https://goo.gl/a8AWrk)
- Witelson SF (1989) Hand and sex differences in the isthmus and genu of the human corpus callosum. *Brain* 112:799-835. [Link: https://goo.gl/KwmZMQ](https://goo.gl/KwmZMQ)
- Weber G, Weis S (1986) Morphometric analysis of the human corpus callosum fails to reveal sex-related differences. *J Hirnforsch* 27: 237-240. [Link: https://goo.gl/pVxpKZ](https://goo.gl/pVxpKZ)
- Demeter S, Ringo JL, Doty RW (1988) Morphometric analysis of the human corpus callosum and anterior commissure. *Hum Neurobiol* 6: 219-226. [Link: https://goo.gl/4j4lm6](https://goo.gl/4j4lm6)
- Wang PP, Doherty S, Hesserling JR, Belugi U (1992) Callosal morphology concurs with neurobehavioral and neuropathological findings in two neurodevelopmental disorders. *Arch Neurol* 49: 407-411. [Link: https://goo.gl/pFzSlg](https://goo.gl/pFzSlg)
- Hynd GW, Hall J, Novey ES, Eliopoulos D, Black K, et al. (1995) *Dyslexia and corpus callosum morphology*. *Arch Neurol* 52: 32-38. [Link: https://goo.gl/kfQuG6](https://goo.gl/kfQuG6)
- Yamauchi H, Fukuyama H, Nagahama Y, Katsumi Y, Hayashi T, et al. (2000) Comparison of the pattern of atrophy of the corpus callosum in frontotemporal dementia, progressive supranuclear palsy, and Alzheimer's disease. *J Neuro Neurol Psychiatry* 69: 623-629. [Link: https://goo.gl/bmyKSq](https://goo.gl/bmyKSq)
- Kostovic I, Rakic P (1990) Developmental history of the transient subplate zone in the visual and somatosensory cortex of the macaque monkey and human brain. *J Comp Neurol* 297: 441-470. [Link: https://goo.gl/Gxszjk](https://goo.gl/Gxszjk)
- Kostović I, Kostović-Srzićentić M, Benjak V, Jovanov-Milošević N, Radoš M (2014) Developmental dynamics of radial vulnerability in the cerebral compartments in preterm infants and neonates. *Front Neurol* 29: 139. [Link: https://goo.gl/nVwqbV](https://goo.gl/nVwqbV)
- Stranding S (2008) *Gray's Anatomy: The Anatomical Basis of Clinical Practice*. 40th Ed. London: Churchill Livingstone Elsevier 354-356. [Link: https://goo.gl/bK6KN5](https://goo.gl/bK6KN5)
- Wahl M, Lauterbach-Soon B, Hattingen E, Jung P, Singer O, et al. (2007) Human motor corpus callosum: topography, somatotomy, and link between microstructure and function. *J Neurosci* 27: 12132-12138. [Link: https://goo.gl/9YYYZ3](https://goo.gl/9YYYZ3)
- Koppel H, Innocenti GM (1983) Is there a genuine exuberancy of callosal projections in development? A quantitative electron microscobic study in the cat. *Neurosci Letters* 41: 33-40. [Link: https://goo.gl/5okoM7](https://goo.gl/5okoM7)
- LaMantia AS, Rakic P (1984) The number, size, myelination, and regional variation of axons in the corpus callosum and anterior commissure of the developing rhesus monkey. *Soc for Neurosci Abstr* 10:1081.
- Petanjek Z, Judaš M, Šimic G, Rasin MR, Uylings HB, et al. (2011) Extraordinary neoteny of synaptic spines in the human prefrontal cortex. *Proc Natl Acad Sci* 108: 13281-13286. [Link: https://goo.gl/LAlrb0](https://goo.gl/LAlrb0)
- Pandya DN, Karol EA, Heilbron D (1971) The topographical distribution of interhemispheric projections in the corpus callosum of the rhesus monkey. *Brain Res* 32: 31-43. [Link: https://goo.gl/886mNK](https://goo.gl/886mNK)
- Cipolloni PB, Pndya DN (1985) Topography and trajectories of commissural fibers of the superior temporal region in the rhesus monkey. *Exp Brain Res* 57: 381-389. [Link: https://goo.gl/IKj2jR](https://goo.gl/IKj2jR)
- Barbas H, Pndya DN (1984) Topography of commissural fibers of the prefrontal cortex in the rhesus monkey. *Exp Brain Res* 55:187-191. [Link: https://goo.gl/disLn8](https://goo.gl/disLn8)
- De Lacoste MC, Kirkpatrick JB, Ross ED (1985) Topography of the human corpus callosum. *J Neuropathol and Exp Neurol* 44: 578-591. [Link: https://goo.gl/886mNK](https://goo.gl/886mNK)
- Shaltenbrand G, Spuler H, Wahren W (1972) The anatomy of the corpus callosum determined electrically during stereotactic stimulation in man. *Conf Neurol* 34: 169-172. [Link: https://goo.gl/QYEvs](https://goo.gl/QYEvs)
- DeLacoste-Utamsing C, Holloway RL (1982) Sexual dimorphism in the human corpus callosum. *Science* 216:1431-1432. [Link: https://goo.gl/Wx2W3B](https://goo.gl/Wx2W3B)
- Holloway RL, DeLacoste MC (1986) Sexual dimorphism in the human corpus callosum: an extension and replication study. *Hum Neurobiol* 5: 87-91. [Link: https://goo.gl/9IUP4y](https://goo.gl/9IUP4y)
- Berberi AS, Fitch RH, Ralphe DL, Denenberg JO, Friedrich Jr. VL, et al. (1988) Corpus callosum: region specific effects of sex, early experience and age. *Brain Res* 438: 216-224. [Link: https://goo.gl/r3KECq](https://goo.gl/r3KECq)
- Denenberg, V H (1977) Assessing the effects of early experience. In R.D. Myers, (Ed.), *Methods m Psychobiology*, Academic Press, New York 127-14. [Link: https://goo.gl/886mNK](https://goo.gl/886mNK)
- Denenberg VH (1978) Infantile stimulation induces brain lateralization in rats. *Science* 201: 1150-1152. [Link: https://goo.gl/lw9i4P](https://goo.gl/lw9i4P)