

Hannah Bykar<sup>1</sup>, Gowrie Mohan S<sup>1</sup>,  
Amit Patel<sup>2</sup>, Ahilan Pathmanathan<sup>3</sup> and  
Nikhil Vasdev<sup>3,4\*</sup>

<sup>1</sup>Department of Anaesthetics, Lister Hospital,  
Stevenage, UK

<sup>2</sup>Department of Radiology, Lister Hospital,  
Stevenage, UK

<sup>3</sup>School of Life and Medical Sciences, University of  
Hertfordshire, UK

<sup>4</sup>Hertfordshire and Bedfordshire Urological Cancer  
Centre, Department of Urology, Lister Hospital,  
Stevenage, UK

**Dates:** Received: 04 December, 2015; Accepted:  
12 December, 2015; Published: 15 December, 2015

**\*Corresponding author:** Mr Nikhil Vasdev,  
Hertfordshire and Bedfordshire Urological Cancer  
Centre, Department of Urology, Lister Hospital,  
Stevenage, E-Mail: [nikhilvasdev@doctors.org.uk](mailto:nikhilvasdev@doctors.org.uk)

[www.peertechz.com](http://www.peertechz.com)

## Case Report

# Emergency JJ Stent for Septic Shock under Remifentanyl Sedation - An Option when Interventional Radiology is not available

## Case Report

A 75-year-old man presented to the emergency department with a 2 day history of feeling generally unwell and with pain in his left renal angle. His past medical history included ischaemic heart disease, peripheral vascular disease with a previous AAA repair 6 years ago and 5 vessel CABG 3 years ago. He had prostate cancer with bone metastases and completed his 4th cycle of chemotherapy 3 days earlier. He was also in full remission for Non-Hodgkin's lymphoma since 2001. He was an ex-smoker, with a reduced exercise tolerance of 90 meters due to claudication, but independent in his activities of daily living.

On assessment he had a blood pressure of 96/55mmHg, heart rate of 100 beats per minute, respiratory rate of 18 on 24% oxygen, saturations of 98%, and a temperature of 36.5°C. He had a capillary refill time of 6 seconds, and was cool and clammy. Blood tests demonstrated a hemoglobin of 101g/L, hematocrit 0.315L/L, platelets 316x10<sup>9</sup>/L, white cell count 17.9x10<sup>9</sup>/L, C - reactive protein 123mg/L, INR 1.2, creatinine 157umol/L, and urea 11.7mmol/L. A venous blood gas revealed metabolic derangement: pH 7.38, pCO<sub>2</sub> 4.11KPa, pO<sub>2</sub> 5.27KPa, bicarbonate 19.1mmol/L, base excess -6.0mmol/L and lactate 6.32mmol/L. Fluids were given, blood cultures taken and antibiotics initiated. An abdominal CT scan demonstrated a 9mm focus of calcification in the left distal ureter with a left hydronephrosis, swollen kidney and perinephric stranding (Figure 1). There was also fluid tracking into the left lumbar region and iliac fossa. Additionally, the scan showed small pleural effusions, atelectasis, and bone metastasis.

The patient's condition deteriorated. He was in septic shock. Blood pressure was 86/43mmHg, heart rate 112 beats per minute, respiratory rate 25, 95% saturations on 2L nasal cannula, and temperature 36.0°C. An arterial blood gas on 2L oxygen showed: pH 7.27, pCO<sub>2</sub> 3.27KPa, pO<sub>2</sub> 13.18KPa, bicarbonate 11.1mmol/L, base excess -13.8mmol/L, lactate 8.77mmol/L. Blood results demonstrates

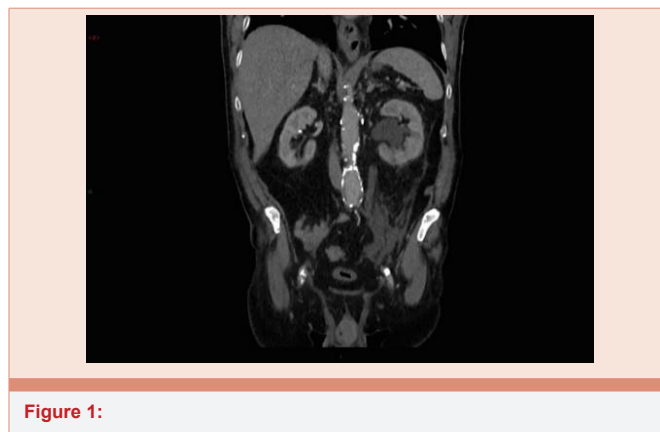


Figure 1:

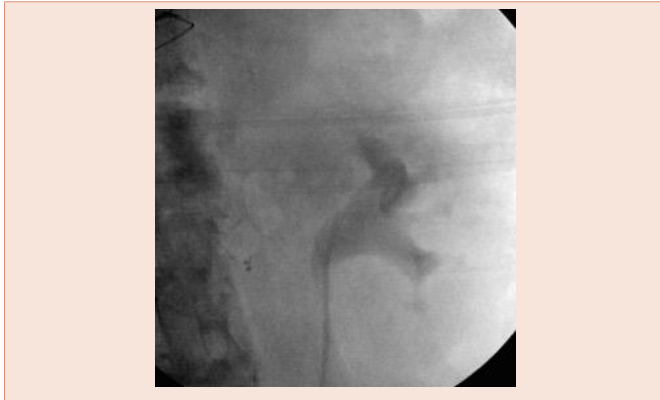hemoglobin 88g/L, hematocrit 0.269L/L, platelets 311x10<sup>9</sup>/L, white cells 24.0x10<sup>9</sup>/L, c-reactive protein 230mg/L, INR 1.4, creatinine 149umol/L, and urea 12.4mmol/L. In view of the patient's acute deterioration an urgent un-obstruction of the infected system was required. An interventional radiology service was not available on-site and the patient was not stable to transfer to a surrounding hospital in view of his rapidly deteriorating condition.

After discussing the situation with the patient and family, consent was obtained to organize an urgent JJ stent insertion to achieve source control.

In the anesthetic room a vascath was inserted, along with arterial and central lines. Noradrenaline was initiated. Goals for resuscitation included CVP 8-12mmHg, mean arterial pressure ≥65mmHg, adequate urine output, and superior vena cava venous oxygen saturations of 70% in accordance with the Surviving Sepsis Campaign [1].

Due to sepsis and cardiovascular instability, central neuraxial blockade was deemed inappropriate, with the possible risk of a spinal abscess resulting in neurological sequelae not justifiable. A general anesthetic, in such a cardiovascular unstable patient with such significant co-morbidities is complicated and associated with several risks, including prolonged post-operative ventilation in critical care.

Following a multi-disciplinary team discussion involving critical care doctors, anesthetists, surgeons and the patient, a decision was made to attempt rigid cystoscopy and JJ stent insertion under sedation (Figure 2). The patient was positioned in theatre with high



**Figure 2:** Retrograde pyelogram post JJ stent placement.

flow oxygen, fluids, and noradrenaline. Intravenous paracetamol was given, a target-controlled infusion of remifentanyl was initiated, and the procedure commenced. The patient was comfortable throughout, with minimal cardiovascular instability due to instrumentation of the urological tract. Resuscitation continued throughout the procedure with adjustments made to achieve optimal oxygen delivery to the tissues. Mixed venous saturations achieved a maximum of 64.9%. The procedure finished promptly within 10 minutes.

Post-operatively in critical care, noradrenaline was weaned quickly and the patient made a good recovery, both symptomatically and metabolically. He did however develop atrial fibrillation on day 2, which was treated with amiodarone and bisoprolol. He was discharged from critical care 4 days postoperatively.

Early recognition and management of sepsis according to the recommendations from the Surviving Sepsis Campaign were fundamental in the final outcome of this patient [1]. Sepsis and septic shock is a major cause of death in intensive care units worldwide, especially in immunocompromised or elderly patients [2]. Additionally, the use of sedation in an operation that usually necessitates general anesthesia or central neuraxial blockade, is a novel approach and should be considered in patients where general or spinal anesthesia are associated with substantial risks or contraindicated.

## References

1. Dellinger RP, Levy MM, Rhodes A, Annane D, Gerlach H, et al. 2013) Surviving Sepsis Campaign: International guidelines for management of severe sepsis and septic shock. *Intensive Care Med* 39: 165-228.
2. Martin GS, Mannino DM, Eaton S, Moss M (2003) The epidemiology of sepsis in the United States from 1979 through 2000. *N Engl J Med* 348: 1546-1554.

**Copyright:** © 2015 Bykar H, et al. This is an open-access article distributed under the terms of the Creative Commons Attribution License, which permits unrestricted use, distribution, and reproduction in any medium, provided the original author and source are credited.

**Citation:** Bykar H, Gowrie MS, Patel A, Pathmanathan A, Vasdev N (2015) Emergency JJ Stent for Septic Shock under Remifentanyl Sedation - An Option when Interventional Radiology is not available. *Arch Clin Nephrol* 1(1): 010-011. DOI: <http://dx.doi.org/10.17352/acn.000003>