



Case Report

Transient camptocormia with citalopram treatment in a patient with mixed dementia—A case report

Inbal Segal, Galia Fisher RN and Doron Merims*

Director, Dementia Special Care Unit, Shoham Medical Center, Technion (Israel), Israel

Received: 27 July, 2020

Accepted: 05 August, 2020

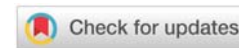
Published: 06 August, 2020

*Corresponding author: Dr. Doron Merims, Director, Dementia Special Care Unit, Shoham Medical Center, Technion (Israel), Israel, Tel: 972-4-6375664; E-mail: doronm@shoham.health.gov.il

ORCID: <https://orcid.org/0000-0002-9066-6011>

Keywords: Case report; Camptocormia; Citalopram

<https://www.peertechz.com>



Abstract

This case report reviews a patient who suffered mixed dementia with depression. The addition of citalopram to the medication regimen was shortly followed by the manifestation of camptocormia, or “bent-spine.” Clinical findings available, without attempting invasive diagnostic procedures, point to a citalopram induced camptocormia. The frequent use of SSRI medications in the geriatric population call for an increased awareness of the possibility of SSRI induced postural side effects.

Introduction

Camptocormia, or “bent spine,” is an involuntary flexion of the spine that is exaggerated while standing or walking but diminished when supine. It was described in the medical literature between the years 1917 and 1928 [1,2]. Soldiers who spent time in the trenches during World War I continued walking in a bending position even after the war was over. The phenomenon was considered “a war neurosis” [3]. Today, camptocormia is mainly regarded as a symptom of Parkinson’s disease, described as a forward bended prominent posture while standing or walking [4]. The mechanism is considered to be associated with dystonia or paravertebral muscle myopathy [5]. Additional medical conditions presenting with camptocormia include Alzheimer’s disease [6], parietal lobe ischemia [7] and bipolar disorder [8]. Certain medications, such as sodium valproate and olanzapine, have been suspected to induce camptocormia [9–11]. Here we present a patient who experienced severe transient camptocormia with the induction of citalopram treatment. To our knowledge, camptocormia has not been described as a side effect of Selective Serotonin Reuptake Inhibitors (SSRI’s) as a class or of citalopram specifically.

Case

A 70-year-old retired sculptor was admitted to a dementia

special care unit due to severe cognitive impairment and tendency to wander around aimlessly. According to his family, the cognitive impairment began 5 years earlier. Memory and visuospatial functioning were the first domains to be affected. Severe worsening of the cognitive impairment and behavioral symptoms began near the time of a cardiac pacemaker insertion. The patient was seen crawling on the floor, looking for objects that were not there. When questioned, he could not explain why, and so the behavior was attributed as a reaction to visual hallucinations. Brain imaging supported diffuse vascular disease. Apart from mixed dementia, his medical history included ischemic heart disease, sick sinus syndrome and permanent pacemaker.

On admission, verbal communication was limited to single words. Memory, orientation and attention could not be formally assessed. The patient tended to wander around for hours unable to locate his room. Neurological examination revealed increased tone in the left limbs—a sequelae of a previous stroke. The patient experienced recurrent episodes of crying. Differential diagnoses included pseudobulbar palsy and depression. The diagnosis of major depressive disorder in patients with dementia is challenging. A limited ability to communicate shifts the focus to other clinical signs, such as crying, decreased appetite or altered sleep patterns. The crying, along with the impressions of the patient’s spouse

and the staff, lead to a diagnosis of depression. Citalopram treatment was started at a 10mg daily dose and was increased to 20mg a week later. At the time of citalopram initiation, the patient's medication regimen included haloperidol, zolpidem and donepezil. Within a couple of days, the patient's posture had severely changed. While the patient walked upright prior to initiating citalopram, after initiation the patient acquired a forward bending position with a nearly 90-degree angle between the legs and torso. Lying in bed, the bending posture resolved. Discontinuation of citalopram was followed by a swift and complete resolution of the symptom.

Discussion

As previously mentioned, camptocormia is thought to be a result of either dystonia or focal myopathy of the paravertebral muscles [5]. Determining a myopathic mechanism requires invasive diagnostics such as an EMG and muscle biopsy. In general, we try to avoid or postpone invasive diagnostic procedures for patients with advanced dementia until after all non-invasive methods have been attempted to reach a diagnosis. Therefore it was first attempted to remove the newest prescribed medication—citalopram—as it is possible that this patient experienced transient camptocormia in relation to citalopram initiation.

The patient most probably suffered mixed dementia – a combination of Alzheimer's disease and cerebral vascular changes. The transient nature of the symptom rules out degenerative disease as a single cause. It is unlikely attributed to a stroke as there were no other new symptoms nor neurological finding on examination. The temporal proximity to citalopram initiation and the fast improvement in relation to its discontinuation support the hypothesis of a dystonic mechanism in relation to citalopram.

It is relatively common for patients with degenerative brain diseases whom are diagnosed with depression to be treated with various SSRI medications [12]. However, most do not experience this symptom. The question arises as to whether and why this patient was prone to develop this phenomenon. The medical condition most frequently associated with camptocormia, Parkinson's disease, was not part of the patient's medical history. Although the medication regimen included haloperidol when citalopram was initiated, camptocormia did not occur with haloperidol alone, nor with risperidone, which the patient received in the past. Use of donepezil has been cited in the literature associated with "pisa syndrome", another type of postural abnormality characterized as a lateral flexion of the trunk [13]. Like the other medications, the patient had been taking donepezil for a long time. Although this supports the assumption that citalopram was the trigger of the camptocormia, it leaves the possibility that it was not the only pharmaceutical factor.

Another possible contributing factor may be the patient's profession. Working as a sculptor exposed him to spending hours a day in a bending position. Theoretically, this may resemble a "task specific dystonia," contributing to a dystonic mechanism in the development of camptocormia.

We suggest addressing the bending posture as a range of severities from normal age-related bending to the extreme posture of camptocormia, instead of an "all or none" phenomenon. It is possible that an accumulation of factors increases the risk of developing bent spine, such as neurological diseases, medications, genetic predisposition and even physical fitness.

Camptocormia may have a major impact on the quality of life of older persons, as walking with a bent spine may lead to functional decline and increased risk of falling. In addition, a patient with camptocormia may suffer from low self-esteem that may induce or worsen social isolation and depression.

Conclusion

Although we describe citalopram induced camptocormia, we suggest increasing awareness to the possibility that this may be a side effect of other SSRI medications. Given the high prevalence of depression in the geriatric population, and the high frequency of SSRI use, one might consider reducing the dose or switching to another anti-depressant. SSRIs are known to increase the risk of falls. If the bending posture is a range from normal aging to clinical camptocormia this may be a possible mechanism by which SSRI medications worsen stability and increases the risk of falling. This case report may contribute to increasing awareness of camptocormia and its possible relation to SSRI treatment.

References

- (1917) A rare form of war neurosis. *Lancet* 189: 267-269. [Link: https://bit.ly/2DEGJBz](https://bit.ly/2DEGJBz)
- Walker GF (1928) A note on camptocormia. *Lancet* 211: 808-809. [Link: https://bit.ly/33AtLQe](https://bit.ly/33AtLQe)
- Lieut Colonel AF, Hurst RAMC (1917) The bent back of soldiers. *Br Med J*.
- Bloch F, Houeto JL, Tezenas du Montcel S, Bonneville F, Etchepare F, et al. (2006) Parkinson's disease with camptocormia. *J Neurol Neurosurg Psychiatry* 77: 1223-1228. [Link: https://bit.ly/39V3VI4](https://bit.ly/39V3VI4)
- Margraf NG, Wrede A, Deuschi G, Schulz-Schaeffer WJ (2016) Pathophysiological concepts and treatment of camptocormia. *Journal of Parkinson's Disease* 6: 485-501. [Link: https://bit.ly/3igggcV](https://bit.ly/3igggcV)
- Brucki S, Ricardo N (2008) Camptocormia in Alzheimer's disease: an association?. *Mov Disord* 23: 156-157. [Link: https://bit.ly/3igfsEV](https://bit.ly/3igfsEV)
- Oh JH, Ryu DW, Lee SH, Kim JS (2017) Camptocormia with transient ischemic attack. *J Mov Disord* 10: 62-63. [Link: https://bit.ly/33spyy5](https://bit.ly/33spyy5)
- Gomez EA (1987) Camptocormia in a Case of Manic-Depressive Disorder. *Psychosomatics* 28: 594-595. [Link: https://bit.ly/31iXkMM](https://bit.ly/31iXkMM)
- Kiuru S, Matti I (1987) Camptocormia, a new side effect of sodium valproate. *Epilepsy Research* 1: 254-257. [Link: https://bit.ly/3fsIJLH](https://bit.ly/3fsIJLH)
- Robert F, Koenig M, Robert A, Boyer S, Cathebras P, et al. (2010) Acute camptocormia induced by olanzapine: a case report. *J Med Case Reports* 4: 192. [Link: https://bit.ly/2Xv6UC0](https://bit.ly/2Xv6UC0)
- Vela L, Jiménez Morón D, Sánchez C, Pareja JA, Barón M (2006) Camptocormia induced by atypical antipsychotics and resolved by electroconvulsive therapy. *Mov Disord* 21: 1977-1980. [Link: https://bit.ly/33vmAZY](https://bit.ly/33vmAZY)

12. Baquero M, Nuria M (2015) Depressive symptoms in neurodegenerative diseases. *World J Clin Cases* 3: 682-693. [Link: https://bit.ly/33uUw92](https://bit.ly/33uUw92)

13. Pollock D, Cunningham E, McGuinness B, Passmore AP (2017) Pisa syndrome due to donepezil: pharmacokinetic interactions to blame?. *Age Ageing* 46: 529-530. [Link: https://bit.ly/2DpuQjp](https://bit.ly/2DpuQjp)

Discover a bigger Impact and Visibility of your article publication with Peertechz Publications

Highlights

- ❖ Signatory publisher of ORCID
- ❖ Signatory Publisher of DORA (San Francisco Declaration on Research Assessment)
- ❖ Articles archived in worlds' renowned service providers such as Portico, CNKI, AGRIS, TDNet, Base (Bielefeld University Library), CrossRef, Scilit, J-Gate etc.
- ❖ Journals indexed in ICMJE, SHERPA/ROMEO, Google Scholar etc.
- ❖ OAI-PMH (Open Archives Initiative Protocol for Metadata Harvesting)
- ❖ Dedicated Editorial Board for every journal
- ❖ Accurate and rapid peer-review process
- ❖ Increased citations of published articles through promotions
- ❖ Reduced timeline for article publication

Submit your articles and experience a new surge in publication services
(<https://www.peertechz.com/submission>).

Peertechz journals wishes everlasting success in your every endeavours.

Copyright: © 2020 Segal I, et al. This is an open-access article distributed under the terms of the Creative Commons Attribution License, which permits unrestricted use, distribution, and reproduction in any medium, provided the original author and source are credited.

Citation: Segal I, Galia Fisher RN, Merims D (2020) Transient camptocormia with citalopram treatment in a patient with mixed dementia—A case report. *Arch Gerontol Geriatr Res* 5(1): 040-042. DOI: <http://dx.doi.org/10.17352/aggr.000025>