

Murat Damar<sup>1\*</sup>, Aykut Erdem Dinc<sup>2</sup>, Sultan Sevik Elicora<sup>1</sup>, Sultan Biskin<sup>1</sup>, Ismail Serifoglu<sup>2</sup>, Duygu Erdem<sup>1</sup> and Ibrahim Ilker Oz<sup>2</sup>

<sup>1</sup>Department of Otorhinolaryngology Head and Neck Surgery, Bulent Ecevit University Faculty of Medicine, Zonguldak, Turkey

<sup>2</sup>Department of Radiology, Bulent Ecevit University Faculty of Medicine, Zonguldak, Turkey

**Dates:** Received: 13 October, 2015; Accepted: 07 November, 2015; Published: 10 November, 2015

**\*Corresponding author:** Dr. Murat Damar, Bulent Ecevit University Faculty of Medicine, Department of Otolaryngology, Kozlu / Zonguldak, 67600, Turkey, Tel: +90 (372) 2612835; +90 (506) 297 72 83; Fax: +90 (372) 2610264; E-mail: drmuratdamar@yahoo.com

[www.peertechz.com](http://www.peertechz.com)

ISSN: 2455-1759

**Keywords:** Pyriform aperture; Nasal septum; Midface; Maxilla; Facial height

## Research Article

# Midface Osseous Dimensions are not Affected by Uncorrected Nasal Septal Deviation

### Abstract

**Objective:** To investigate the effects of uncorrected nasal septal deviation on the pyriform aperture (PA) dimensions, the upper anterior face height (UAFH), and the anteroposterior length of the maxilla (LM) of adult patients.

**Methods:** The study included 150 patients (104 males, 46 females; 18-63 years) who had paranasal sinus CT. The study population consisted of 51 patients with anterior nasal septal deviation (NSD) (group I), 72 patients with posterior NSD (group II) and 27 patients with no NSD (group III). By using multiplanar reconstruction (MPR) technique, on coronal plane the width of PA (PAW), the right and left maxilla spinal length (RMSL and LMSL) and the angle of the septal deviation (ASD) and on sagittal plane the height of the PA (PAH), the UAFH and the LM were measured.

**Results:** There was no difference in PAW, PAH, right and left MSL, UAFH and LM among the groups. Using bivariate correlation, there was no correlation between ASD and PAH, AUFH, LM, RMSL, LMSL, ipsilateral MSL, and contralateral MSL. However, there was weak correlation between ASD and PAW ( $r = -0.182$ ,  $P = 0.044$ ).

**Conclusion:** The study suggest that nasal septal deviation does not affect PA dimensions, UAFH, and LM.

## Introduction

The adequate width and length of osseous structures in midface is important for nasal physiology and normal facial appearance. For the osseous and cartilage structures during the development process in midface interact with one another, structural changes caused by genetic, or trauma in these structures may affect the nasal physiology and development of the midface.

The nasal septum is a dynamic structure in the nasal cavity midline and consists of cartilage, bone, and fibrous tissue. All of these tissues have different physical and biological properties. These properties make the nasal septum important in the point of the development of midface. The effect of nasal septum on midface growth can be explained by a few theories. According to the nasal septal traction model, the nasal septal cartilage acts as a growth plate, placing tension on the premaxillary suture via septopremaxillary ligament, thus inducing an osteogenic response [1,2]. A second theory suggests that the importance of the nasal septal cartilage as a growth center intrinsic to the facial skeleton is growth center theory, as surgical resection of all or part of the nasal septum in a variety of animal models results in a deficiency in the anteroposterior dimensions of the maxilla and premaxillar [3].

Morphological abnormalities of the upper jaw can be seen more frequently in subjects suffering from nasal septal deformities [4]. These abnormalities in patients with nasal septal deviation (NSD) are not known to be a cause or a result of nasal septal deviations.

There are very few studies investigating the association between NSD and facial development in human being [5]. Most of the studies in literature have focused on the influence of nasal septum that has been operated on or traumatized in early age, leading to growth differences of the surrounding structures [6,7]. So far, the pyriform aperture dimensions have not been studied in patients with NSD. The aim of this study was to investigate the effects of uncorrected NSD on the pyriform aperture dimensions and the upper anterior face height, and the anteroposterior length of the maxilla.

## Materials and Methods

### Patients

Computed tomography (CT) images, demographic and clinical characteristics of the patients, from the archives of Bulent Ecevit University Faculty of Medicine, were obtained and analyzed for this retrospective study.

The exclusion criteria were accepted as follows; age <18 years, acute or chronic rhinosinusitis, previous nasal and/or paranasal surgery, S-shaped septum deviation, sinonasal tumor and congenital craniofacial anomalies.

From January 2013 to May 2015, 150 patients with computed tomography (CT) scans available were identified. The study group included 123 consecutive patients with nasal septal deviation who underwent endonasal and extracorporeal septoplasty, and divided into two groups. Fifty one patients who had more anteriorly placed

deviations in front of the inferior turbinate were accepted as the anterior septum deviation (group I), and 72 patients with deviation to right or left without any effect on the internal nasal valve were accepted as posterior deviation (group II). Twenty seven patients constituted the control group without any septum deviations and sinonasal morbidity who were investigated for cephalgia etiology (group III).

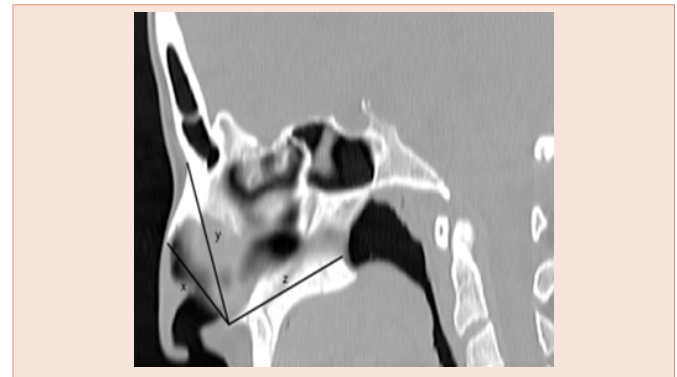
### CT imaging and measurements

CT examinations were performed by using an Activion 16 CT Scanner (Toshiba Medical Systems, 2008 Japan). The routine paranasal sinus CT protocol was used for all patients with 120 kVp; 100–150 mA; 1.0 mm axial slice thickness; 512 x 512 matrix size; 240 mm field of view. Osirix Imaging Software (Pixmeo, Geneva, Switzerland) on MacPro laptop (Apple) was used for the analysis. The measurements were performed using multiplanar reconstruction (MPR) technique. To resolve the asymmetry associated with positioning, the angle of reformatted image was adjusted until the basal turns of the cochlea were equally viewable in axial and coronal planes.

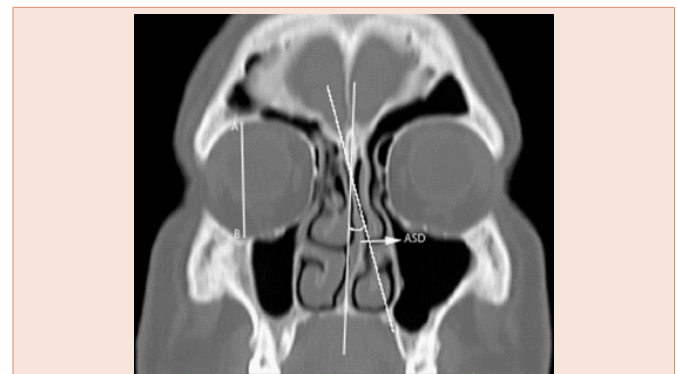
The width of the pyriform aperture (PAW) was defined as transvers distance between the right and the left frontal process of maxilla where it was the first appearance of inferior turbinate bone on the coronal planes. At the same section, the distance between the right and left frontal process of maxilla to anterior nasal spine was regarded as right maxillospinal length (RMSL) and left maxillospinal length (LMSL), respectively (Figure 1).

1. The following parameters on the midsagittal images were measured (Figure 2) The height of the pyriform aperture (PAH): the distance between the lowest point of the nasal bone and anterior nasal spine.
2. The upper anterior face height (UAFH): the distance between nasion and anterior nasal spine.
3. The anteroposterior length of the maxilla (LM): the distance between anterior and posterior nasal spine.

The angle of the septal deviation (ASD): the angle between a line drawn from the maxillary spine to the crista galli and another line



**Figure 2:** Sagittal CT image demonstrating the measurements; (x) The height of pyriform aperture (PAH), (y) The upper anterior face height (UAFH), (z) The anteroposterior length of the maxilla (LM).



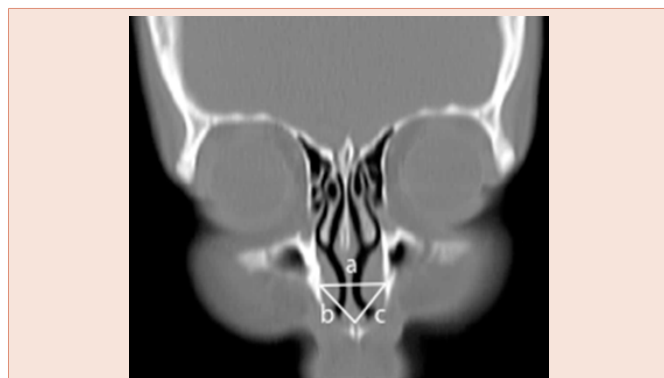
**Figure 3:** Shows the measurements of the angle of the septal deviation (ASD) and the maximal height of orbit (AB) on coronal CT image.

from the crista galli to the most deviated point of the nasal septum was accepted as the deviation angle on the coronal plane (Figure 3).

The maximal height of the orbit in the vertical plane was measured in each patient on the coronal plane (Figure 3). In order to eliminate the influence of individual variation, the ratio of maximal orbital height to the measured parameters were used for analysis. The calculated ratio values compared among the groups. Each measurement was performed two times by the first author, at different times. Because the measurement points were clearly described, measurements were consistent.

### Statistical analysis

Statistical analysis were performed with SPSS 19.0 software (SPSS Inc., Chicago, IL, USA). Continuous variables were expressed as mean ± std. deviation or median (min-max), categorical variables as frequency and percent. Mann-Whitney U test was used for the two groups' comparison and Kruskal-Wallis test was used to determine for differences between the all three groups. Bonferonni-corrected Mann-Whitney U test was performed for comparison of 2-subgroups. Spearman's correlation analysis was performed to determine the relationship between continuous variables. P value of less than 0.05 was considered statistically significant for all tests.



**Figure 1:** Coronal CT image demonstrating measurements; (a) The width of the pyriform aperture (PAW), (b) The right maxillospinal length (RMSL), (c) The left maxillospinal length (LMSL).

## Results

There were 104 males and 46 female patients with a mean age of  $34.67 \pm 11.54$  years, ranging from 18 to 63 years. The average age of the anterior septal deviation group (group I) with 43 (84.3 %) males and 8 (15.7 %) females was  $34.59 \pm 10.23$  years (min. 20–max. 60). The posterior septal deviation group (group II) with the average age of  $35.39 \pm 12.67$  years (min. 18–max. 63) included 44 (61.1 %) males and 28 (38.9 %) females. The control group (group III) included 17 (63 %) males and 10 (37 %) females with the average age  $32.93 \pm 10.90$  years (min. 18–max. 59). There was no statistically significant difference between the groups in terms of age ( $P = 0.747$ ). The gender difference was statistically significant between the groups, anterior septal deviation was higher in men ( $P = 0.017$ ).

The values on the **Table 1** show males' and females' mean age and the average of measured parameters ( $P > 0.05$  for all parameters and age). Deviation angles were determined to be  $12.56 \pm 3.28^\circ$  (min.  $5.75^\circ$ -max.  $20.9^\circ$ ) and  $11.21 \pm 3.86^\circ$  (min.  $5.04^\circ$ -max.  $25.98^\circ$ )

for groups I and II, respectively. There was statistically significant difference between group I and group II ( $P = 0.028$ ). The comparison of the studied parameters between the groups and correlation test results are demonstrated in **Tables 2-4**. No difference was found between the groups in terms of the studied parameters ( $P > 0.05$ ). There was no correlation between ASD and PAH, AUFH, LM, RMSL, LMSL, ipsilateral maxilla spinal length (IMSL), and contralateral maxilla spinal length (CMSL). However, there was weak correlation between ASD and PAW ( $r = -0.182$ ,  $P = 0.044$ ).

## Discussion

The effect of the nasal septum on midface growth is one the most enthusiastic phenomenon that researchers have long been focusing on to develop an explanatory theory. Growth of the nasal septal cartilage acts as an endochondral growth plate and propels all the facial bones, anteriorly and inferiorly from the cranial base. This force helps to separate the facial bones, and thus lead to cartilage apposition at sutural interfaces [2,8]. Cartilage nasal septum rapidly grows

**Table 1:** Shows mean age and the average of measured parameters in males and females.

	Males (N = 46) Mean ± Std. Dev	Females (N = 104) Mean ± Std. Dev.	Total (N = 150) Mean ± Std. Dev.	P value
Age	34 ± 11.33	36.20 ± 11.99	34.67 ± 11.54	0.278
PAH	1.13 ± 0.15	1.13 ± 0.13	1.13 ± 0.14	0.814
PAW	1.64 ± 0.16	1.59 ± 0.15	1.62 ± 0.16	0.123
AUFH	0.73 ± 0.06	0.73 ± 0.05	0.73 ± 0.05	0.507
LM	0.73 ± 0.06	0.72 ± 0.07	0.73 ± 0.06	0.220
RMSL	2.03 ± 0.22	2.03 ± 0.23	2.03 ± 0.22	0.990
LMSL	2.05 ± 0.25	1.97 ± 0.19	2.03 ± 0.23	0.051
ASD	11.90 ± 3.78	11.45 ± 3.46	11.77 ± 3.68	0.611

PAH = the height of the pyriform aperture; PAW = the width of the pyriform aperture; AUFH = the upper anterior face height; LM = the anteroposterior length of the maxilla; RMSL = the right maxillospinal length; LMSL = the left maxillospinal length; ASD = the angle of the septal deviation; Std. dev = standard deviation; N = the number of patients.

**Table 2:** The comparison of measured parameters among the groups.

Parameters	Groups	Mean	Std. dev	Median (Min. - max.)	P value
PAH	Group I	1.16	0.15	1.10 (0.92 – 1.39)	0,527
	Group II	1.12	0.14	1.11 (0.85 – 1.55)	
	Group III	1.12	0.11	1.13 (0.94 – 1.78)	
PAW	Group I	1.58	0.14	1.57 (1.30 – 2.02)	0,093
	Group II	1.64	0.15	1.64 (1.28 – 2.00)	
	Group III	1.66	0.19	1.69 (1.30 – 2.14)	
AUFH	Group I	0.73	0.05	0.73 (0.63 – 0.84)	0,934
	Group II	0.73	0.06	0.73 (0.56 – 0.84)	
	Group III	0.73	0.05	0.72 (0.61 – 0.82)	
LM	Group I	0.73	0.07	0.73 (0.61 – 0.90)	0,824
	Group II	0.73	0.06	0.72 (0.62 – 0.92)	
	Group III	0.73	0.07	0.71 (0.61 – 0.87)	
RMSL	Group I	2.03	0.20	2.07 (1.59 – 2.49)	0,893
	Group II	2.03	0.25	2.04 (1.50 – 2.76)	
	Group III	2.03	0.19	1.99 (1.78 – 2.48)	
LMSL	Group I	2.04	0.25	2.00 (1.54 – 2.74)	0,818
	Group II	2.01	0.22	1.99 (1.56 – 2.66)	
	Group III	2.04	0.23	2.06 (1.67 – 2.67)	

PAH = the height of the pyriform aperture; PAW = the width of the pyriform aperture; AUFH = the upper anterior face height; LM = the anteroposterior length of the maxilla; RMSL = the right maxillospinal length; LMSL = the left maxillospinal length; Std. dev = standard deviation; Min = minimum; Max = maximum.

**Table 3:** MSL values according to septal deviation side between group I and II.

Parameters	Group I		Group II		P value
	Mean ± Std. dev.	Median (Min. - Max.)	Mean ± Std. dev.	Median (Min. -Max.)	
IMSL	2.04 ± 0.24	2.05 (1.54 -2.74)	2.03 ± 0.24	2.01 (1.50 -2.76)	0.782
CMSL	2.03 ± 0.22	2.02 (1.59 -2.52)	2.01 ± 0.23	2.03 (1.56 -2.66)	0.908

IMSL = ipsilateral maxillospinal length; CMSL = contralateral maxillospinal length; Std. dev = standard deviation; Min = minimum; Max = maximum.

**Table 4:** The correlation between the angle of septal deviation and studied parameters.

Parameters		PAH	PAW	AUFH	LM	RMSL	LMSL	IMSL	CMSL
ASD	Spearman's correlation	0.143	-0.182	0.021	-0.021	-0.125	-0.119	-0.152	0.086
	P Value	0.116	0.044	0.822	0.818	0.170	0.190	0.093	0.343

PAH = the height of the pyriform aperture; PAW = the width of the pyriform aperture; AUFH = the upper anterior face height; LM = the anteroposterior length of the maxilla; RMSL = the right maxillospinal length; LMSL = the left maxillospinal length; IMSL = ipsilateral maxillospinal length; CMSL = contralateral maxillospinal length; ASD = the angle of the septal deviation.

during the first 2 years of life and completes its growth by the end of three years. Septal growth ceases to influence growth of the facial bones when the ethmoid and vomer fuse and stabilize the craniofacial complex, around age seven [9].

Prepubertal surgical septal manipulation, significant childhood septal trauma or childhood septal abscess can result in short, snubbed noses and under projected nasomaxillary spine. Two main theories to explain this issue have been employed. One of which is the nasal septal cartilage growth center theory suggesting that growth centers positioning in the septal cartilage contain groups of chondrocytes which multiply and produce cartilaginous extracellular matrix, expand the septal cartilage and so that can enlarge and project the rest of the nose and midface. The accurate locations of these growth centers are unknown, but it has been thought to be near the nasomaxillary crest and the posterior edge of the quadrangular cartilage [10]. Accordingly, surgical interventions on the nasal septum with removal or modification of the cartilage might destroy these growth centers. Another theory is that the cartilage has intrinsic tension and the removal of developing cartilage plate weakens intrinsic force in the cartilage. However, results of studies about septoplasty surgeries performed on children have shown no effect on midfacial development [6,11].

The effect of the nasal septum on nasal and midface growth still remains the object of intense debate and controversy in the current literature. Animal studies demonstrated that a variety of surgical operations performed on the nasal septum in young rabbits often resulted in a marked retardation of growth in the nose and upper jaw [10]. Grymer and Melsen [12], made a cephalometric analysis of 11 twins in which one sibling had an anterior septal deformity and the other had not. The anteroposterior length of the maxilla was found to be smaller in the twin with the anterior septal deformity. Another study conducted on twins with the severe nasal injury at the age 12 reported no effect on the development of the maxilla [13]. Brain and Rock [7], performed a retrospective study on the facial and nasal development in 29 adult patients who experienced a serious untreated injury to the nose during childhood. Measurement of lateral skull radiographs of these patients indicated reduced downward and forward growth in the maxilla, and altered angulations for certain planes in the middle and lower thirds of the face. In the present study conducted on adult patients, there was no significant difference between the groups in terms of LM ( $P = 0.824$ ).

Pirsing [13], stated that midfacial deficiency could also be explained by direct injury to the maxilla alone and not by a misdirected septal growth according to the results of 178 patients with nasal deformity due to trauma in childhood. In another study analyzing 98 children, age 7-12 years, with obligate mouth-breathing secondary to nasal septum deviation demonstrated increased upper anterior facial height and total facial height measured on lateral cephalometric radiographs [14]. The result of the present study, in terms of upper anterior facial height, was different from the results of the above mentioned study on pediatric patients. This discordance might be attributed to the age of study population that maxillofacial development might continue until the advanced age.

The width and shape of PA is considered to be a major factor that is effective in nasal breathing. The PAW rises 2 times from childhood to adulthood and is reported to continue developing even after 20 years old [15]. The shape and dimensions of PA vary in black and white races and between men and women [15,16]. Our initial hypothesis was expecting to determine reduced height and width of PA that affect the nasal septum on midface growth in anterior septal deviation group. However, there was no significant difference between the groups and men and women in terms of the height and width of the pyriform aperture. Similarly, no significant difference was determined in terms of RMSL and LMSL between the groups. The evaluation of MSL according to direction of the deviation revealed no significant difference in terms of ipsilateral (deviated side) and contralateral MSL between groups I and II.

### Conclusions

The results of the present study on adult population with anterior and posterior septal deviation revealed no difference when compared with control group, in terms of the pyriform aperture dimensions, the upper anterior face height and the anteroposterior length of the maxilla. Nevertheless, it should be kept in mind that the relationship between the midface development and growing nasal septum is more complex. The genetic mechanisms and molecular pathways involved in normal midface development are just beginning to be unraveled, and prospective long-term studies might shed some valuable light on the process of nasal and maxillary structure. Thus, further studies are required to achieve more accurate results.





## Acknowledgments

We would like to thank to Prof. MD. Mehmet Birol Uğur, from Gazi University Faculty of Medicine for his contributions to the study. We also thank to Lecturer Mustafa Çağatay Büyükuysal from Biostatistics department of Bülent Ecevit University Faculty of Medicine, who performed the statistical analysis of the study.

## References

1. Siegel MI, Mooney MO, Kimes KR, Todhunter J (1991) Developmental correlates of midfacial components in a normal and cleft lip and palate human fetal sample. *Cleft Palate Craniofac J* 28: 408-412.
2. Wealthall RJ, Herring SW (2006) Endochondral ossification of mouse nasal septum. *Anat Rec A Discov Mol Cell Evol Biol* 288: 1163-1172.
3. Wexler MR, Sarnat BG (1961) Rabbit snout growth. Effect of injury to the septo-vomer region. *Arch Otolaryngol* 74: 305-313.
4. Mladina R (1987) The role of maxillar morphology in the development of pathological septal deformities. *Rhinology* 25: 199-205.
5. Kim YM, Rha KS, Weissman JD, Hwang PH, Most SP (2011) Correlation of asymmetric facial growth with deviated nasal septum. *Laryngoscope* 121: 1144-1148.
6. El-Hakim H, Crysedale WS, Abdollel M, Farkas LG (2001) A study of anthropometric measures before and after external septoplasty in children: a preliminary study. *Arch Otolaryngol Head Neck Surg* 127: 1362-1366.
7. Brain DJ, Rock WP (1983) The influence of nasal trauma during childhood on growth of the facial skeleton. *J Laryngol Otol* 97: 917-923.
8. Rhys Evans PH and Brain DJ (1981) Effects of nasal surgery on the growth of the rabbit snout. *Rhinology* 19: 101-105.
9. Van Loosen J, Van Zanten GA, Howard CV, Verwoerd-Verhoef HL, Van Velzen D, et al. (1996) Growth characteristics of the human nasal septum. *Rhinology* 34: 78-82.
10. Wong KK, Filatov S, Kibblewhite DJ (2010) Septoplasty retards midfacial growth in a rabbit model. *Laryngoscope* 120: 450-453.
11. Tasca I, Compadretti GC (2011) Nasal growth after pediatric septoplasty at long-term follow-up. *Am J Rhinol Allergy* 25: 7-12.
12. Grymer LF, Melsen B (1989) The morphology of the nasal septum in identical twins. *Laryngoscope* 99: 642-646.
13. Pirsig W (1992) Growth of the deviated septum and its influence on midfacial development. *Facial Plast Surg* 8: 224-232.
14. D'Ascanio L, Lancione C, Pompa G, Rebuffini E, Mansi N, et al. (2010) Craniofacial growth in children with nasal septum deviation: a cephalometric comparative study. *Int J Pediatr Otorhinolaryngol* 74: 1180-1183.
15. Lopez MC, Galdames ICS, Matamala DAZ, Smith RL (2009) Sexual dimorphism determination by piriform aperture morphometric analysis in Brazilian human skulls. *Int J Morphol* 27: 327-331.
16. Yuzbasioglu N, Yilmaz MT, Cicekcibasi AE, Seker M, Sakarya ME (2014) The evaluation of morphometry of nasal bone and pyriform aperture using multidetector computed tomography. *J craniofac Surg* 25: 2214-2219.

**Copyright:** © 2015 Damar, et al. This is an open-access article distributed under the terms of the Creative Commons Attribution License, which permits unrestricted use, distribution, and reproduction in any medium, provided the original author and source are credited.

**Citation:** Damar M, Dinc AE, Elicora SS, Biskin S, Serifoglu I, et al. (2015) Midface Osseous Dimensions are not Affected by Uncorrected Nasal Septal Deviation. *Arch Otolaryngol Rhinol* 1(2): 047-051. DOI: 10.17352/2455-1759.000009