



Diallo M*, Diadie S, Diatta B.A, Ndiaye M, Diop A, Dieng M.T

Department of Dermatology, Aristide LeDantec University Hospital, Dakar, Senegal

Dates: Received: 26 July, 2017; Accepted: 22 August, 2017; Published: 23 August, 2017

***Corresponding author:** Dr Moussa DIALLO, Department of Dermatology, Teaching Hospital Aristide LeDantec, Dakar, Senegal, BP 6821, Dakar-Etoile, Senegal, Tel: 00 (221) 77 762 90 90; E-mail: moussante@hotmail.com

Keywords: Skin cancers; Squamous cell carcinoma; Face; Black African

<https://www.peertechz.com>

Research Article

Skin cancers of the face in an African Black population

Summary

Introduction: The aim of this study was to evaluate the frequency and clinico-anatomical features of facial skin cancers in an African Black population.

Patients and methods: It was a retrospective, descriptive study of all cases of skin cancer localized on the face, seen in our department over a 21-year period.

Results: We collected 253 cases of cutaneous cancers, among which 48 cases (19%) were localized on the face. The mean age of the patients was 50 years, with a sex ratio (M/F) of 1.19. Squamous cell carcinoma (SCC) was the most common (54.2%), followed by primary cutaneous lymphomas (18.75%), Basal Cell Carcinoma (BCC) (14, 6%) and Darier-Ferrand dermatofibrosarcoma (4.2%). Melanoma, rhabdomyosarcoma, adnexal carcinoma and angiosarcoma were each observed in 1 case respectively (2%).

Conclusion: In sub-Saharan Africa, the localization of skin cancer on the face is rare, dominated by SCC, which often occurs on precancerous skin lesions, especially actinic cheilitis and genodermatosis. The BCC and melanoma are exceptionally rare on the face.

Introduction

The localization of skin cancers on the face is a major concern for the dermatologist. Indeed, because of its intense solar exposure, about 80% of skin cancers sit selectively in this region, although it only represents 9% of the body surface area [1,2]. On the other hand, the management of cancers in this highly visible region requires a compromise between clinical and aesthetic results [3]. Despite their frequency, very few studies have focused on malignant tumors on the face throughout the world and, to our knowledge, none in sub-Saharan Africa [1,4,5]. The purpose of this study was, therefore, to report the frequency and -clinico-anatomical features of skin cancers on the face in a black African population.

Patients and Methods

We conducted a retrospective, descriptive study in Aristide LeDantec University Hospital in Dakar, Senegal, including patients from 1996-2016 (21 years). The medical records of patients with biopsy-proven facial skin cancer were checked. Kaposi's sarcoma was excluded.

Results

We collected 253 skin cancers, among which 48 cases (19%) were on the face, corresponding to a hospital prevalence of

0.6% and a frequency of 2.4 cases / year. The average age of a patient with facial skin cancer was 50 years [ranged from 4 to 85 years] and the majority (56.5%) were over 50 years of age. The sex ratio (M/F) was 1.19.

Facial cancers were dominated by Squamous Cell Carcinomas (SCC), observed in 26 cases (54.2%). It was followed respectively by Primary Cutaneous Lymphoma (PCL) (9 cases, 18.75%), Basal Cell Carcinoma (BCC) (7 cases, 14.6%), Darier Ferrand dermatofibrosarcoma (DFS) (2 cases, 4.2%). Rhabdomyosarcoma, adnexal carcinoma, melanoma and angiosarcoma were observed in 1 case each (2%) (Figure 1).

The localization of SCC on the face accounted for 21.3% of all localizations of this cancer (122 cases) during the same period. On the face, the SCC was localized on the cheek (38.5%), the lower lip (34.6%), the ears and the eyelids each in 11.8% of cases. The nose and upper lip were each involved in 5.7% of cases.

A precancerous skin lesion was found in 14 patients, including 7 genodermatoses and 7 acquired precancerous skin lesions. Genodermatoses were represented by 2 cases of albinism, 3 cases of epidermodysplasia verruciformis and 2 cases of xeroderma pigmentosum. Acquired precancerous skin lesions were represented by actinic cheilitis in 4 cases,

leukoplakia of the oral mucosa (due to prosthesis and mucosal lichen planus) in 2 cases and hydroquinone-induced exogenous ochronosis in one case (Figures 2,3).

A facial localization of a PCL was noted in 9 patients (%). They consist of NK/T-cell lymphoma, nasal type in 4 patients, Anaplastic CD30⁺ lymphoma in 3 cases and of mycosis fungoide in 2 cases (Figure 4).

We observed seven cases (14.6%) of BCC on the face (Figure 5). It was a nodular BCC in 5 cases and ulcerated BCC in 2 cases. The BCC was located on the nose and cheek in 3 cases each and on the lower eyelid in one case.

Two cases of DFS on the cheek were found, corresponding to 9.1% of the 22 cases of DFS observed during the same period. A case of eccrine adenocarcinoma, rhabdomyosarcoma, melanoma and a case of primary angiosarcoma were also observed (Figure 6).

Discussion

Studies on facial skin cancers are rare and date back to a long time [1,2,4]. Despite the limitations of our study, this is, to our knowledge, the first study on the characteristics of skin cancers on the face in a black population.

In contrast to the white population in which about 40% of skin cancers occur on the face, the localization in this region seems very rare in the Black African population [6-8]. Indeed, over a period of 21 years, we found 48 cases, representing only 19% of all localizations. In fact, in black African population,

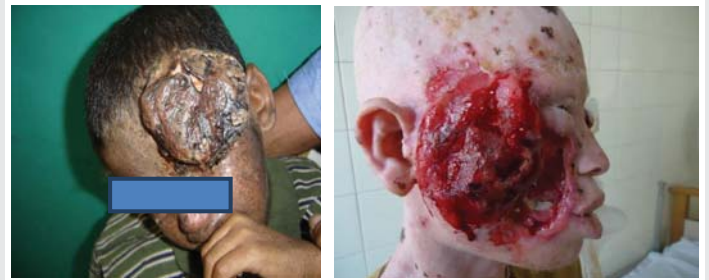

Figure 3: SCC occurring on genodermatoses (xeroderma pigmentosum and albinism).

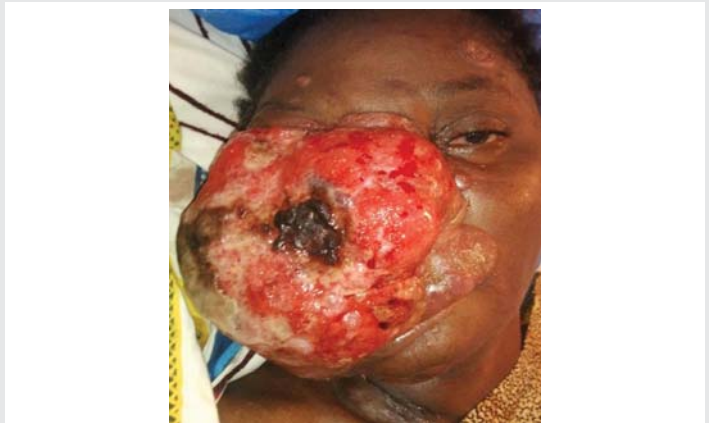

Figure 4: NK/T-cell lymphoma, nasal type.

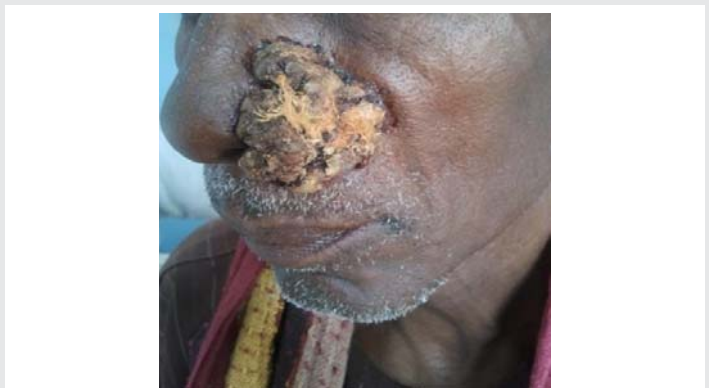

Figure 5: Basal cell carcinoma.

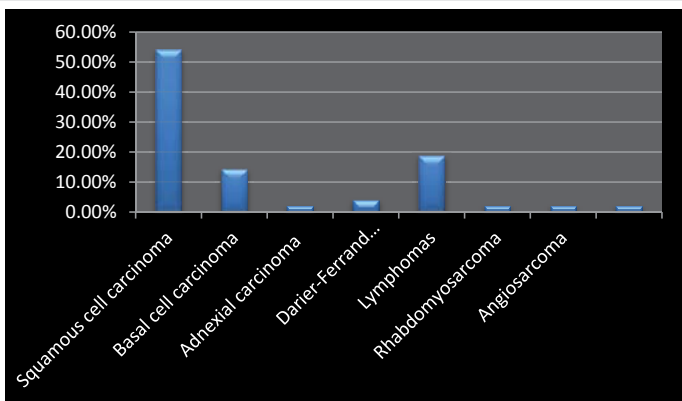


Figure 1: Distribution of different skin cancers on the face.

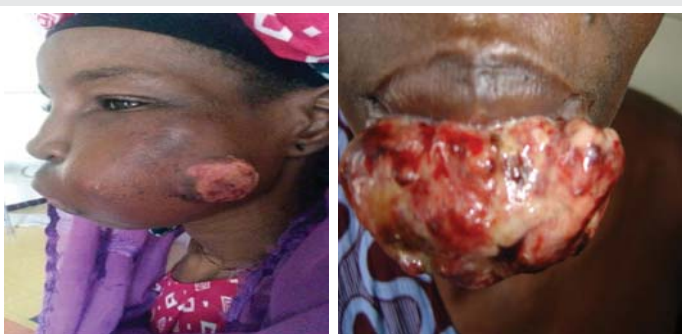

Figure 2: SCC occurring on acquired precancerous skin lesions (hydroquinone-induced exogenous ochronosis and actinic cheilitis respectively).

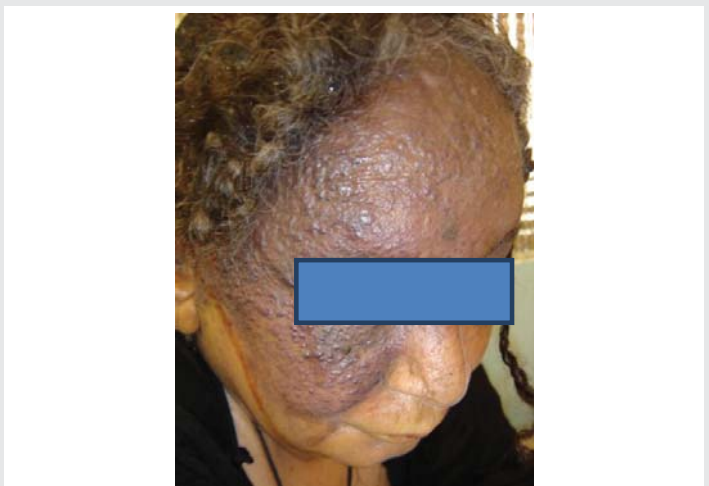

Figure 6: primary angiosarcoma of the face.

skin cancers are not often related to solar exposure, but rather to precancerous skin lesions (ulcers, burn scars) that sit rather selectively on the legs [7]. The SCC represents by far the most common skin cancer on black skin [8]. In our cohort of patients, there was a clear predominance of the SCC, which, alone, accounted for more than half (54.2%) of skin cancers in this region. Through this study, it can be said that in the black subject, the SCC seems to be the most frequent regardless of the topography. In contrast, in the white population, facial skin cancers are widely dominated by BCC [9]. The lower limb is the preferential localization of the SCC in Black African population [7]. Thus, in our study, facial involvement accounted for only 21.3% of cases. On the contrary, in fair-skinned subjects, the SCC predominates at the cephalic extremity [2,9]. On the other hand, in white population, the SCC of the face has a predilection for the nose and the ears, generally occurring on actinic keratosis lesions favored by solar exposure [1,6]. In our study, the SCC was mostly found on the lower lip (38.5%) and the cheeks (34.6%), promoted by the topography of the precancerous skin lesions, especially genodermatoses as well as actinic cheilitis, which is particularly frequent in black Africans.

Moreover, the occurrence of a SCC on lesions induced by skin bleaching, as observed in one of our patients, has been rarely reported in the medical literature [10].

Apart from the SCC, PCL was the most common facial cancer in our study (18.75%). Unlike in the white population, the PCL on the face, were dominated, in our cohort, by T-cell lymphoproliferations (mycosis fungoide and anaplastic CD30+ lymphoma), as well as NK/T-cell lymphoma, nasal type. This latter is rarely reported in Africa, despite the prevalence and precocity of the Epstein-Bar virus infection, unlike in Asia and South America [11].

In our study, only 7 cases of BCC (14.6%) were located on the face. This is merely related to the rarity of this tumor on black skin, in which its prevalence is estimated at 1 / 100,000 inhabitants [8,12,13].

It is the same with melanoma in black skin, because of its preferential localization on the feet. The occurrence of DFS on the face, as noted in our 2 patients is exceptionally rare [14]. The same is true for rhabdomyosarcoma. Contrariwise, the localization of angiosarcoma and adnexal tumors on the face is usual [15].

In addition, some skin cancers frequent on the face, such as Merkel cell carcinoma, have not been found in our study because of their rarity in the black population.

Conclusion

In the black African population, skin cancers rarely occur on the face. In this region, they are also still dominated by squamous cell carcinoma, which is frequently found on the lower lip and cheeks and favored by precancerous skin lesions,

notably actinic cheilitis and genodermatosis. The SCC was followed by cutaneous lymphomas mainly T and NK/T-cell nasal type, while BCC and melanoma are exceptionally rare on the face of black African skin.

References

- Chiscop I, Popescu E, Mihai C, Budacu C (2011) Cutaneous carcinoma of the face. Clinical and histopathological forms. Retrospective study of 308 cases. *Rev Med Chir Soc Med Nat Iasi* 115: 560-566. [Link: https://goo.gl/8Z6ugW](https://goo.gl/8Z6ugW)
- Pearl DK, Scott EL (1986) The Anatomical Distribution of Skin Cancers. *Int J Epidemiol* 15: 502-506. [Link: https://goo.gl/6af4XL](https://goo.gl/6af4XL)
- Schliephake H, Neukam FW, Schmelzeisen R, Reiche C (1994) Reconstruction of facial soft tissues after resection of skin tumors. *J Craniomaxillofac Surg* 22: 342-348. [Link: https://goo.gl/YqyfrS](https://goo.gl/YqyfrS)
- Hajdarbegovic E, Van Der Leest RJT, Munte K., Thio HB, Neumann HA (2009) Neoplasms of the facial skin. *Clin Plast Surg* 36: 319-334. [Link: https://goo.gl/3eaXye](https://goo.gl/3eaXye)
- Romeu M, Foletti JM, Chossegros C, Dales JP, Berbis P, et al. (2007) Malignant cutaneous adnexal neoplasms of the face and scalp: Diagnostic and therapeutic Update. *J Stomatol Oral Maxillofac Surg* 118: 95-102. [Link: https://goo.gl/TBYWhT](https://goo.gl/TBYWhT)
- Feller L, Khammissa RA, Kramer B, Altini M, Lemmer J (2016) Basal cell carcinoma, squamous cell carcinoma and melanoma of the head and face. *Head Face Med* 5: 12-11. [Link: https://goo.gl/SWUyqr](https://goo.gl/SWUyqr)
- Dieng MT, Diop NN, Dème A, Sy TN, Niang SO, et al. (2004) Squamous cell carcinoma in black patients: 80 cases. *Ann Dermatol Venerol* 131: 1055-1057. [Link: https://goo.gl/9gYDHZ](https://goo.gl/9gYDHZ)
- Gloster HM Jr, Neal K (2006) Skin cancer in skin of color. *J Am Acad Dermatol* 55: 741-760. [Link: https://goo.gl/aLRQWu](https://goo.gl/aLRQWu)
- Franceschi S, Levi F, Randimbison L, La Vecchia C (1996) Site distribution of different types of skin cancer: new aetiological clues. *Int J Cancer* 67: 24-28. [Link: https://goo.gl/pLhmpj](https://goo.gl/pLhmpj)
- Ly F, Kane A, Dème A, Ngom NF, Niang SO, et al. (2010) First cases of squamous cell carcinoma associated with cosmetic use of bleaching compounds. *Ann Dermatol Venerol* 137: 128-31. [Link: https://goo.gl/4YGhCs](https://goo.gl/4YGhCs)
- Mestiri S, Zeglaoui I, Sriha B, et al. (2008) Extra-nodal NK/T-cell lymphomas of the nasal cavities and sinuses. *Ann Otolaryngol Chir Cervicofac* 125: 188-192. [Link: https://goo.gl/M9GYR9](https://goo.gl/M9GYR9)
- Diepgen TL, Mahler V (2002) The epidemiology of skin cancer. *British J Dermatol* 146: 1-6. [Link: https://goo.gl/5Twa1s](https://goo.gl/5Twa1s)
- Norval M, Kellett P, Wright CY (2014) The incidence and body site of skin cancers in the population groups of South Africa. *Photodermatol Photoimmunol Photomed* 30: 262-265. [Link: https://goo.gl/R4CV7F](https://goo.gl/R4CV7F)
- Pérez GC, Arias C, Luna P, Sorín I, Mazzuocolo LD (2016) A Challenging Giant Dermatofibrosarcoma Protuberans on the Face. *Case Rep Dermatol Med* 2016: 5926307. [Link: https://goo.gl/StvnNv](https://goo.gl/StvnNv)
- Ito T, Uchi H, Nakahara T, Tsuji G, Oda Y, et al. (2016) Cutaneous angiosarcoma of the head and face: a single-center analysis of treatment outcomes in 43 patients in Japan. *J Cancer Res Clin Oncol* 142: 1387-1394. [Link: https://goo.gl/BmtWR1](https://goo.gl/BmtWR1)