



Raja Kummoona*

Emeritus professor of Maxillofacial Surgery, Iraqi Board for Medical Specializations, Baghdad, Iraq

Dates: Received: 15 June, 2016; Accepted: 22 August, 2017; Published: 24 August, 2017

*Corresponding author: Raja Kummoona, FDSRCS, FICD, Emeritus professor of Maxillofacial Surgery, Iraqi Board for Medical Specializations, Baghdad, Iraq, E-mail: dr_raja_kummoona@yahoo.com

Keywords: Chondro-Ossous graft; TMJ; Facial deformity; Reconstruction; Rabbit

<https://www.peertechz.com>

Research Article

Kummoona Chondro-Ossous graft good substitute to condylar growth center and fore correction of facial deformity in children

Abstract

Kummoona Chondro-Ossous graft is the most popular graft been used for reconstruction of the temporomandibular joint for restoring growth, repair and remodeling and fore correction of facial deformity in children with restoration of functional activity of the damaged temporomandibular joint (TMJ) and graft work as primary growth center. These graft been studied by experiment on Rabbits as an excellent animal model for viability of the graft. clinically 36 cases were reported, they were 25 children including 9 females and sixteen boys with history of ankyloses of the TMJ and ten children of 4 females and 6 boys suffering from milled hemi facial microsomia or first arch dysplasia syndrome and one female case with traumatic hypoplasia of the condyle.

Fellow up of the cases from 3-5 years and graft does not showed any ossification or chondrification beside its function for restoring growth, remodeling and repair on the long run.

Introduction

There are a lot of controversial views about the condyle as a growth center, the British pioneer and great scientist John Hunter [1] 1772-1773 who paid attention to the condyle as a growth center in his book the teeth and he mentioned in his book there is a strong relation between the teeth and temporomandibular joint (TMJ).

This theory was accepted by most of the scientist and clinician for many decades till Moss [2], 1962 came with new theory based on, the growth of the face occurred as a functional demand of the periosteal matrix of the facial skeleton and he think there is no growth center in the condyle controlling the growth of the mandible and most of the craniofacial and maxillofacial surgeons with orthodontist were supported Moss theory previously [2].

The author came with another idea and supported John Hunter theory [1], his thought was based on his experimental studies by using Rabbits as animal model for his experiments by excision the head of the Rabbit condyle of the mandible of a newly borne animal and three months later he noticed severe deformity of the mandible and mid face, and the mandible twisted to the effected side and also the author did replaced

the TMJ by two part chrome cobalt Kummoona prosthesis [3], for ankylosed joint of 6 year female patient, after three years he noticed this young girl showed excellent function of the mandible during mouth opening without difficulties during mastication but she had some deficiency in the growth of the mandible on the of joint replacement side by prosthesis.

The author believed, there is no single theory controlling the growth of the mandible and mid face but both theories working together for growth of the mandible and the face and the condyle work as growth center combined with the Moss theory of functional demand of the periosteal matrix of the facial skeleton [4,5].

During the last 4 decades there were a lot of researchers attempting to use an autologous tissue to replace the damage condyle and the temporomandibular joint (TMJ) by different technique applied clinically on human or experimentally on animal models, these attempts were failed to restore growth and function of the condyle and temporomandibular joint.

A number of different autologous tissues have been used in attempt to restore normal height and reconstruct the TMJ articulation with restoration of function. The attempts of Bardenheuer [6] and Gilles [7] both described the use of costochondral graft, this technique has been revised and

subjected to scientific scrutiny in the last 4 decades and the pioneers were Johan Kennet [8] and David poswillo 1974 [9,10].

In children the author proposed and advocates a new technique to substitute the costochondral graft with a Chondro-Ossous graft from iliac crest for restoration of growth, repair, remodeling, and height of midface and function of the TMJ.

Material and Methods

Thirty six cases were reported, there were 25 children including 9 female and 16 boys with history of ankyloses of the TMJ and ten children of four females and six boys with history of under developed mandible and milled hemi facial microsomia and one female with hypoplasia of the condyle due to trauma, their age ranged between 4 and 13 years (mean 8.5) and follow up of the cases ranged from 3-6 years. All these cases were treated in the Surgical Specialty hospital, Medical City and author private clinic (Figures 1 A,B, Figures 2 A-D).

The Chondro-Ossous grafts were used as bi cortical with a cartilage cap and osseous element of 4-5cm harvested from iliac crest of children in the following cases, Figure 3A.

1. Damaged TMJ in children with ankyloses
2. Hypoplasia of condyle and midface in cases with milled hemi facial macrosomia
3. Hypoplasia of the condyle due to trauma

Surgical access

By using a modified question mark full thickness of fascio-cutaneous Kummoona flap of pre auricular incision with temporal extension, the temporal extension designed to be behind the posterior fibers of the temporalis muscle. The dissection started in the temporal region down to the zygomatic root of temporal bone and capsule of the TMJ. Another incision was required in the submandibular region for detachment of the masseter and medial pterygoid muscles and for release of the pterygoid-mandibular slink and this incision was used as an access for insertion and fixation of Chondro-Ossous graft to the ascending ramus after approximating the graft to the glenoid fossa.

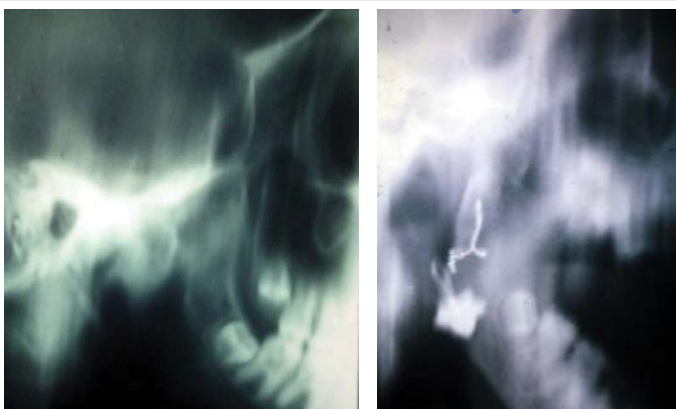


Figure 1: A) CT scan of 4 years female with ankylosed TMJ. B) Three years follow up of the same patient showing Chondro-Ossous graft in female patient of 4 years of age replacing the joint by graft and the graft act as condyle.

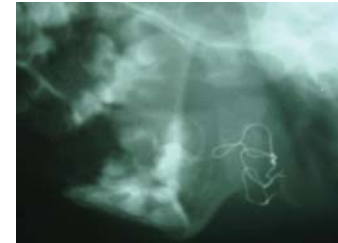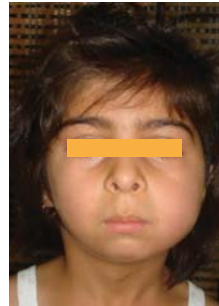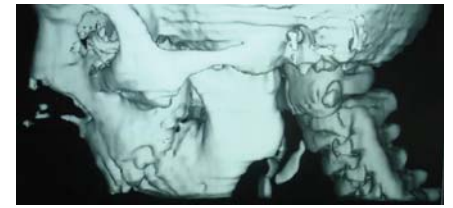


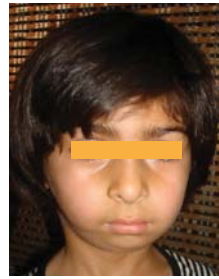Figure 2: A) Ankyloses of the left TMJ showing severe deformity of lower jaw and midface with un ability to open here mouth of 4 years girl. B) CT scan showing fusion of the TMJ with the skull. C) Post-operative view 3 months later with obvious growth in the mandible with less deformity of the face in a girl of 4 years. D) X-ray of the lower jaw showing Chondro-Ossous graft fixed to the lower jaw by stainless steel wire of 0.5mm and the graft fitting the glenoid fossa with obvious mineralization of the graft after 3 months.

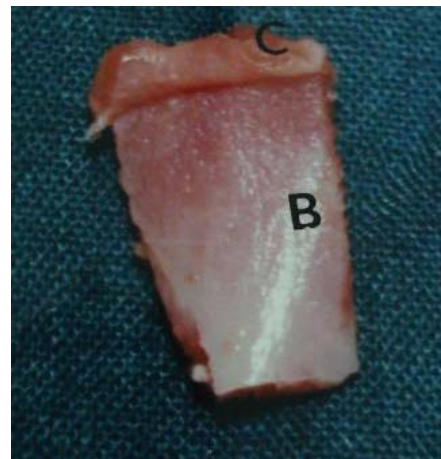


Figure 3A: This figure showing human Chondro-Ossous graft of 4-5 cm with cartilaginous cap and osseous part below.

Experimental studies on rabbits

1. First operation by excision the head of condyle and meniscus applied in 3 males and 3 females Rabbits to assess the condyle as growth center
2. Second experiment by (Kummoona & Al Mudaffer M) [11], were applied on 8 young Rabbits of three months of age with approximately of same weight of 1.5 kg to prove the viabilities of Chondro-Ossous graft, the rabbits were divided into 2 groups each group of 4 animals. The TMJ of each Rabbit subjected to unilateral condylactomy and meniscectomy, the surgical operation done via a curved incision extending from outer canthus of the eye to pre

auricular area, the temporal part of zygomatic bone was used as a land mark for localization of the TMJ Rabbits.

3. Apiece of full thickness of bi cortical iliac crest graft of about of 1.8 cm with a cap of cartilage excised from the Rabbit was fixed by stainless steel wire of 0.5mm and the graft inserted up to fit the glenoid fossa and to the ascending ramus after decortication of both graft and the outer face of the ascending ramus and fixed by stainless steel wire of 0.5mm (Figure 3B).
4. This surgical procedure were performed under (vetalar-Ketamiene HCL: Astra Pin Germany) of 50mg of body weight administered intramuscular with infiltration of the TMJ by local anesthesia of Lingo span (Lignocaine hydrochloride 2% with adrenaline 1/80000, St. Maur, France).

The result of the experiments

In the first experiment after excision of the head of condyle three months later, we noticed severe deformity of the mandible in the operated side and the mandible twisted to the effected side (Figure 4).

Postmortems macroscopic examination

the Chondro-Ossous grafts were nicely adapted to the new function of hard masticatory process, the union between the graft and the ascending ramus was excellent and there was no resorption in the head or in the shaft of the graft and the stainless steel used for fixation of the graft show no changes in color or presence of corrosive property and the graft formed a neck and condyle similar to normal condyle in the opposite side (Figure 5 A,B).

Microscopic examinations

The cytological features of the newly reconstructed Chondro-Ossous graft resemble the histology of non-operated condyle with 4 distinct zone layers. The staining by (H&E).

The first layer of thick fibrocartilage layer, the second layer consist of several layers of active round mesenchymal stem

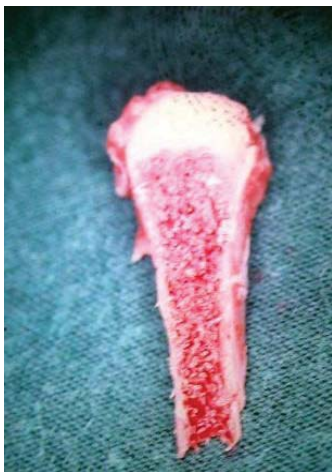

Figure 3B: This figure showing Chondro-Ossous graft of Rabbit consist of cartilage cap and an osseous shaft of 1.8cm.




Figure 4: Deformity of lower jaw of Rabbit after excision of the head of condyle

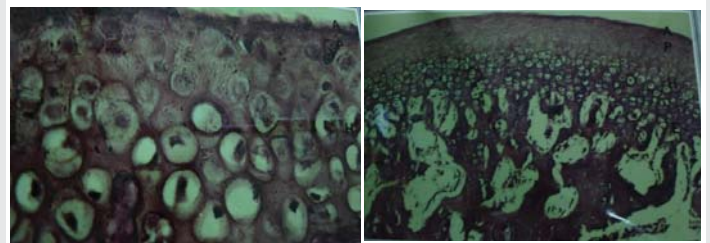

Figure 5: A) (E&H) staining showing Hyper trophic chondrocytes and differentiation of the cells. B) (E&H) staining section through the Chondro-Ossous graft showing all layers with specific attention to osteoid tissue and bone marrow in between bone trabecular.

cells and this layer represent the proliferative zone layer of the condyle, the third layer consist of cells of iliac crest layer converted from vertical columnar layer as in the iliac crest to multi directional layer as functional demand of masticatory process simulating normal condyle and the fourth layer showed endochondral ossification and the chondrocyte became swollen through a series of changes of endochondral cells conversion to osteoid tissue with hypertrophic cells similar to control group and in the fourth layer bone trabeculae observed and contain living osteoblast cells in bone marrow spaces arranged to the direction of the masticatory forces (Figures 6, Figure 7 A,B).

Clinical Results

Clinical cases were reported were thirty six cases, there were 25 children of 9 females and 16 boys with ankylosed joints and 10 children of 4 females and 6 boys with history of hemi facial microsomia and one female with hypoplasia of the condyle, their age ranged between 4-13 years (mean 8.5 years), these cases were subjected to surgical excision of ankylosed joints and coronoid and excision of remnant under developed condyle in traumatic type. Reconstruction of the hypoplasia of the TMJ in hemi facial macrosomia, these cases required before reconstruction of the TMJ, several surgical operations including comissureplasty with removal of ruminants tags and mackles cartilage in pre auricular region followed by reconstruction of the zygomatic temporal bone by bone graft and glenoid fossa by cartilage graft and also platysma muscle graft mobilized from the neck for reconstruction of atrophied masseter muscle before 6 months to make a bed to accommodate and investing the chondral- osseous graft. The fellow up of the cases between 3 to 5 years.




Figure 6: Microscopic feature of postmortem sections of Chondro-Ossous graft with (E&H) staining, showing thick articular layer due to hard food, Mesenchymal round stem cells as proliferative layer of the condyle and a third layer of chondrocytes were differentiation of the cells and the fourth layer an osteoid tissue with bone marrow in between bone trabecular.

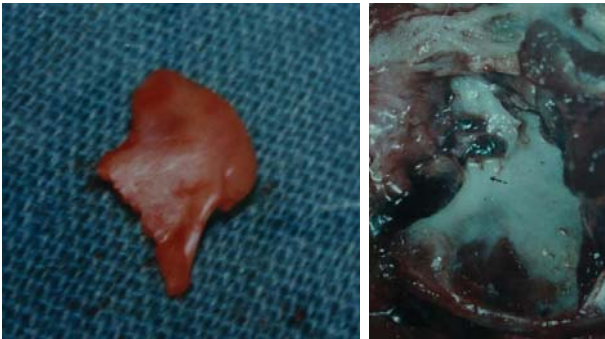


Figure 7: A) Specimen of excised Rabbit condyle. B) This showing postmortem view of macroscopic feature of the Chondro-Ossous graft with excellent union to the ramus of mandibular Rabbit.

Discussion

Reconstruction of the TMJ was a challenge to all maxillofacial, craniofacial, ENT surgeons and to plastic and reconstructive surgeons'. Many attempt was carried out in the past using a fibular head, Meta tarsal phalangeal and Sterno-clavicular joint, iliac crest and rib bone. These surgical procedures have been reported only a few times as surgical experiment that proved and provided a little information on their viability and function in the long time, however few researchers reported growth and reconstruction of TMJ by fibular head graft and the objection raised from difficulties encountered in adapting the articular surface of the large fibular head to fit the small glenoid fossa during surgery and no prove for viabilities and continuous growth in the fibular graft [10].

There are two successful biological techniques widely used now a day for reconstruction of the TMJ, the first by Costa-Chondral graft and the second by Kummoona Chondro-Ossous graft [4,12]. The studies that carried by David Poswillo on non-human primates have showed and stated that, costochondral graft that replaced the mandibular condyle can rapidly adapt to the adaptive functional demands of the site.

The author objection about the costochondral graft, the cap easily displaced from the rib and perforation of the pleura

might happened also an over growth of the graft might occur, this procedure required inter maxillary fixation for 6 weeks, these patients showed difficulties in opening the mouth after releasing the jaws from inter maxillary fixation after six weeks due to spasm of muscles of mastication while in application of Chondral-Osseous graft for reconstruction of TMJ, no long fixation required and active mobilization of the jaw started in the following days not only for restoration of function but for restoration of growth based on Moss theory of functional demand of periosteal matrix of the facial skeleton [2]. Recently this phenomena of an over growth of costochondral graft was reported after five years in a child previously treated for ankyloses of the TMJ, the growth pattern was unpredictable and more troublesome than the lack of growth [5].

In children the author proposed and advocates a new technique to substitute the Costo-Chondral graft by the use of Chondral-Osseous graft for restoration of function and growth and remodeling of the condyle and TMJ, the graft proved successful for reconstruction of TMJ ankyloses, hemi facial microsomia or first arch dysplasia and traumatic hypoplasia of the condyle.

The success of the results by using this technique was very optimistic in all diseases for restoration of function, growth and aesthetic of the mandible and mid face and the graft does not show any ossification or chondrofication in the long term and the graft has the ability to restore growth because of presence of intrinsic growth potential due to presence of mesenchymal stem cells to grow in multidirectional pattern through a stable Chondro-Ossous junction.

Recently researchers on connective tissue for cell differentiation found the value of chondro osseous junction of the graft to maintain growth, repair and remodeling of the graft due to intrinsic potential and the presence of mesenchyme stem cells during endo chondral bone formation in the Chondro-Ossous graft, chondrocyte cells undergoes differentiation towards hyper trophy before they replaced by bone and bone marrow [5].

In this study they did found that a G-protein coupled receptor (CXCR4) predominantly expressed in hypertrophic chondrocyte, while its ligand chemokine stromal cells derived factor (SDF-1) is expressed in the bone marrow adjacent to hypertrophic chondrocyte [3,5].

The Chondro-Osseous graft proved to be a good substitute to the Costo-Chondral graft and as condylar growth center through its clinical application and experimental studies for restoration of growth, remodeling and repair of the condyle and TMJ.

References

- Hunter J (1778) Natural history of human teeth. 2nd ed, London: Johnson.
- Moss ML (1968) The primary of functional matrices in orofacial growth. Dent Proc Dent Rec 19: 65-73. [Link: https://goo.gl/UTrH2o](https://goo.gl/UTrH2o)
- Kummoona R (2009) Temporomandibular joint reconstruction with 2 part chrome cobalt prosthesis, chondro osseous graft and sialastic, clinical and experimental studies. J Craniofac Surg 20: 2125-2135. [Link: https://goo.gl/8TL5o5](https://goo.gl/8TL5o5)

4. Kummoona R (2013) Biological reconstruction of the temporomandibular joint by Chondro-Ossous graft, clinical and experimental study. *J Craniofac Surg* 24: 792-796. [Link: https://goo.gl/86sjyt](https://goo.gl/86sjyt)
5. Kummoona R (2013) Role of mesenchyme stem cells of the Chondro-Ossous graft reconstruction of temporomandibular joint for continuous growth of the mandible and midface. *Annals of Oral Maxillofacial Surgery* 1: 2. [Link: https://goo.gl/dREJqZ](https://goo.gl/dREJqZ)
6. Binderheuer F (1909) Uber Gelenk transplantation (quoted by Lexer E). *Arch Clin Surg* 90: 236.
7. Gilles HD (1920) Present day plastic operation of the face. *Natl Dent Assoc J* 7: 3.
8. Kennett S (1973) Temporomandibular ankyloses the rational for grafting in the young patients. *J Oral Surg* 31: 744-748. [Link: https://goo.gl/eCetyZ](https://goo.gl/eCetyZ)
9. Poswillo DE (1974) Experimental reconstruction of mandibular joint. *Int J Oral Surg* 3: 400-411. [Link: https://goo.gl/kqQT81](https://goo.gl/kqQT81)
10. Poswillo DE (1987) Biological reconstruction of mandibular condyle. *Brit J Oral Maxillofacial Surg* 25: 100-104. [Link: https://goo.gl/FjSmGE](https://goo.gl/FjSmGE)
11. Kummoona R, AL Mudaffer M (2004) Reconstruction of mandibular condyle by Chondro-Ossous iliac graft (experimental study in rabbits). *IPMJ* 3: 98-102.
12. Kummoona R (1986) Chondro-Osseous iliac crest graft for one stage reconstruction of the ankylosed TMJ in children. *J Maxillofacial Surg* 14: 215-220. [Link: https://goo.gl/w7vcydes](https://goo.gl/w7vcydes)

Copyright: © 2017 Kummoona R. This is an open-access article distributed under the terms of the Creative Commons Attribution License, which permits unrestricted use, distribution, and reproduction in any medium, provided the original author and source are credited.