



Rancés Blanco<sup>1\*</sup>, Charles E Rengifo<sup>2</sup>,  
Elizabeth Domínguez<sup>3</sup>, Damián  
Blanco<sup>4</sup>, Mercedes Cedeño<sup>1</sup> and  
Enrique Rengifo<sup>1</sup>

<sup>1</sup>Laboratory of Recognition and Biological Activity Assays, Cuba

<sup>2</sup>Department of Pathology, Manuel Fajardo General Hospital, Zapata and D Street Vedado, Plaza de la Revolución, 10400 Havana, Cuba

<sup>3</sup>Laboratory of Biochemistry, Center of Molecular Immunology, 216 Street and 15 Avenue, Atabey, Playa, PO Box 16040, 11600 Havana, Cuba

<sup>4</sup>Department of Cell Biology and Tissues Banking, National Institute of Oncology and Radiobiology, 10400 Havana, Cuba

**Dates:** Received: 18 February, 2017; Accepted: 19 April, 2017; Published: 20 April, 2017

**\*Corresponding author:** Rancés Blanco Santana, PhD, Laboratory of Recognition and Biological Activity Assays, Center of Molecular Immunology, 216 Street and 15 Avenue, Atabey, Playa, PO Box 16040, Havana 11600, Cuba, Tel: (537) 2717933-3464; Fax: (537) 2720644; E-mail: rances@cim.sld.cu

**Keywords:** Non-small cell lung cancer; Clinic-pathological features; Mucin production; Epidermal growth factor receptor; Epidermal growth factor

<https://www.peertechz.com>

## Research Article

# Mucin Production Correlates with Dual Expression of Epidermal Growth Factor Receptor and Its Ligand the Epidermal Growth Factor in Non-Small Cell Lung Cancer

## Abstract

**Introduction:** Mucoproduction plays an important role in the processes of tumor progression, invasion and metastasis. In non-small cell lung cancer (NSCLC), mucins hypersecretion has been associated with alterations in the epidermal growth factor receptor (EGFR) expression. However, the relation of mucins with EGFR in these tumors is not completely clarified.

**Aims:** To evaluate the relation between mucoproduction, the expression of EGFR and its ligand the epidermal growth factor (EGF) in NSCLC samples.

**Materials and Methods:** A number of 71 routinely processed formalin-fixed and paraffin-embedded archival samples with diagnosis of NSCLC were used. Mucoproduction was considered when periodic acid-Schiff reaction (PAS) positive and/or alcian blue positive substances were observed. The immunolocalization of EGFR and EGF molecules were detected by mean of immunohistochemical methods. Chi-square test was applied to compare two or three different parameters. In all cases, the criterion for statistical significance was  $p < 0.05$ .

**Results:** The production of mucins was related with the occurrence of metastasis ( $p = 0.0151$ ) as well as, with a more advanced stage of NSCLC disease ( $p = 0.0409$ ). The presence of mucin was statistically significant associated to histology ( $p < 0.0001$ ) and degree of cytological atypia ( $p = 0.0325$ ). The expression of EGFR was associated with mucin hyperproduction ( $p = 0.0205$ ). The levels of mucin production was statistical significant increase in NSCLC samples displaying double expression of EGFR and EGF ( $p = 0.0297$ ) when compared with EGFR-/EGF+ and EGFR-/EGF-.

**Conclusions:** The results obtained in the present work could support the role of uncontrolled EGFR system activation mediated by the ligand EGF in NSCLC mucins hyperproduction as well as its relation with tumor progression and metastasis processes.

## Abbreviations

AB: Alcian Blue Stain; ABC: Avidin Biotin Complex; BAC: Bronchioloalveolar Carcinoma; DAB: 3,3-Diaminobenzidine; EGF: Epidermal Growth Factor; EGFR: Epidermal Growth Factor Receptor; HE: Hematoxylin And Eosin Staining; HRP: Horse-Radish Peroxidase; Mab: Monoclonal Antibody; MAPK: Mitogen-Activated Protein Kinase; L MUC: Mucin; NSCLC: Non-Small-Cell Lung Cancer; PAS: Periodic Acid-Schiff Stain; SCLC: Small-Cell Lung Cancer

## Introduction

Lung cancer remains one of the leading causes of death from cancer worldwide [1]. There are two main variant of the disease, non-small-cell lung cancer (NSCLC) and small-cell lung cancer (SCLC), but, NSCLC constitute about 80-85% cases of all lung carcinomas [2,3]. Most of NSCLC patients have a poor prognosis because most of them present with advanced or metastatic disease at the time of diagnosis. It has been estimated that only 10-15% of the patients will ultimately be cured [4].

Mucins constitute a heterogeneous group of highly O-glycosylated macromolecules synthesized by epithelial cells [5]. Airway mucins are major components of the soluble layer and/or viscoelastic gel that comprise lung mucus in healthy airways and contribute to the mucociliary defense system that protects the lungs against pathogens and environmental toxins [6]. Particularly, increased hyperproduction of secretory mucins usually occurs in lung tumors [5,7]. Nevertheless, their cellular localization and variations along the respiratory tract or occurring in respiratory diseases have received little attention.

Mucoproduction plays an important role in the processes of tumor progression, invasion and metastasis. In addition, mucins are engaged in malignant cells survival and protection against the host immune response [8], contributing to the aggressive potential of tumors. Airway obstruction from mucus accumulation is one of the major pathological changes in NSCLC [9]. In line with this, chronic mucus hypersecretion has been considered a significant predictor of death from these tumors [10]. However, further investigations in order to elucidate the biological significance of mucins in carcinomas have been suggested [11].

Previously, the epidermal growth factor receptor (EGFR) mutation was considered a critical event in the pathogenesis of nonmucinous bronchioloalveolar carcinoma (BAC) [12] while, invasive mucinous pattern and extracellular mucin have been associated with KRAS mutation in lung adenocarcinoma [13]. Moreover, the lepidic-predominant group was associated with EGFR mutation compared with nonlepidic-predominant tumors [13]. Furthermore, one preliminary study demonstrated a significant correlation between nonmucinous BAC histology and EGFR expression [14]. Nevertheless, the relation of mucins with EGFR expression in lung cancer is not complete clarified [7].

In this study, it was evaluated the relation between mucoproduction and the expression of EGFR in NSCLC patients. Additionally, it was assessed the role of the double expression of EGFR and its ligand the EGF in mucins hyperproduction.

## Materials and Methods

**Tissue specimens.** A number of 71 routinely processed formalin-fixed and paraffin-embedded archival samples with diagnosis of NSCLC were received from the pathology department of both Hermanos Ameijeiras General Hospital and the National Institute of Oncology and Radiobiology, after approved consent by the institutional ethical committees. Five micrometer serial sections from each block were obtained in a micrometer (Leitz 1512) and they were mounted on plus slides (Dako S2024). All sections were attached to the slide by heating in a 60°C oven for 1h. Afterwards, the slides were dewaxed in xylene and rehydrated in graded ethanol series in the usual way. The samples were maintained in tap water until they were stained.

**Pathological features.** The evaluation of some pathological features was performed for each tumor tissues using the hematoxylin and eosin (HE) staining. Morphologic parameters

such as histopathological classification and degree of histologic differentiation were evaluated. In addition, some cytomorphologic characteristics such as cell and nuclear size, cellular shape, chromatin pattern, nucleoli, and amount of cytoplasm were assessed. This measured was considered as the degree of cytological atypia and it was subjectively expressed as low, moderate and high.

**Mucoproduction detection.** The Alcian blue pH 2.5-P.A.S. acc. Mowry kit (DiaPath 010209) according to the manufacturer instructions was used. Briefly, the slides were stained with Alcian Blue (pH 2.5) for 30 minutes at room temperature. The samples were drained and treated with a saturated solution of sodium tetraborate for 10 minutes. After two rinse in running tap and distilled water, the tissues were oxidized for 5 minutes in 1% periodic acid solution. Then, the slides were rinsed in several changes of distilled water and immersed in Schiff reagent acc. Hotchkiss-McManus for 30 minutes. Afterward, sections were dipped in a solution containing 90 mL of distilled water and 10 drops of metabisolite potassium acc. Hotchkiss-McManus and 10 drops of 10% hydrochloric acid for 10 minutes. The sections were washed for 1 minute in distilled water. Finally, the tissues were counterstained with Mayer Hematoxylin, dehydrated in ethanol, cleared in xylene and mounted with a synthetic medium.

**Immunohistochemical staining.** The immunolocalization of the epidermal growth factor receptor (EGFR) and its ligand the epidermal growth factor (EGF) was performed as it was previously described in [15]. Briefly, the slides were pre-treated with 0.4% pepsin in 0.1N hydrochloric acid solution at 37°C for 30 minutes. Afterward, the tissues were incubated with ior egf/r3 Mab (anti-EGFR) and CB-EGF1 (anti-EGF ligand) in a humid chamber for 1h at room temperature followed by a rabbit anti-mouse biotinylated secondary antibody (Dako E0354) and ABC/HRP (Dako E0355) both for 30 minutes at room temperature dilution 1:100. The enzymatic activity was visualized with DAB substrate chromogenic solution (Dako K3465) and the tissues were counterstained with Mayer's Hematoxylin (Dako S2020). Finally, the samples were dehydrated in ethanol, cleared in xylene and mounted with a synthetic medium.

**Histochemical and immunohistochemical evaluation.** The Alcian blue pH 2.5-PAS acc. Mowry kit supplies reagents for Alcian blue (pH 2.5) and periodic acid-Schiff stains (AB-PAS) to identify on the same histological section acid and neutral mucins, glycogen and glycoprotein. In this study, the appearance of blue-turquoise and/or purple staining in both extra and intra-cellular locations was considered as histochemical detection of mucins.

Concerning to the immunohistochemistry, the tissue expression of the EGFR and EGF was evaluated for percentage of positive cells (0-100%) and the intensity of reaction (0-3+). The final results were considered according with two observers agreement (ChER and RB). Afterward, the H-score was calculated for each specimen by multiplication of the intensity of reaction and the grade of positive cells, resulting in a score ranging from 0 to 300. Subsequently, these scores

were grouped as follow: low expression (scores < 150) and high expression (scores  $\geq$  150) as it was previously described in [16] (Table 1).

Statistical analysis. PopTools version 3.0.5 software (Available on: <http://www.cse.csiro.au/poptools>) was used for data analysis. Chi-square test was applied to compare two or three different parameters. In all cases, the criterion for statistical significance was  $p < 0.05$ .

## Results

**Patients characteristics.** Table 1 shows a summary of patient characteristics and some pathological features. In general, the gender ratio was to 2:1 in favor of males, with a mean age of  $57.2 \pm 10.3$  years. In addition, mostly patients in stages I-II (78.9%) and samples showing histological features of well and moderately differentiated tumors (67.6%) were included.

Mucins expression is associated with both occurrence of distant metastasis and advanced disease. In general, the mucin expression was observed in 35/71 (49.3%) of NSCLC. The mucoproduction was mainly detected in acinar structures formed by many tumor cells; although vacuoles in the interior of individual epithelial cells were also visualized. The production of mucins was significantly increased in patients displaying distant metastasis 7/7 (100%) when compared with no metastatic disease 28/64 (43.7%) ( $p = 0.0151$ , Chi-Square test). Similarity, the presence of mucoproduction was mostly evidenced in advanced stages of NSCLC disease 11/15 (73.3%) when compared with early stages 24/56 (42.9%) ( $p = 0.0409$ , Chi-Square test).

Mucins expression is also related with histology and degree of cytological atypia. The distribution of mucin production according to the histopathological classification of NSCLC is shown in Table 2. The presence of mucin was statistically significant increased in adenocarcinomas and other minor represented subtypes when compared with the rest of histological subtypes of NSCLC ( $p < 0.0001$ , Chi-Square test). In addition, the mucoproduction was significantly increased in samples with higher degree of cytological atypia ( $p = 0.0325$ , Chi-Square test) (Figure 1). No association between mucin hyperproduction and the rest of clinicopathological characteristics of patients were evidenced.

Mucin hyperproduction is related with EGFR expression. The expression of EGFR was detected in 42/71 (59.1%) of NSCLC samples no taking into account the histological classification of tumors. Regarding the histological classification of tumors, the EGFR expression was evidenced in 10/21 (47.6%) of squamous carcinoma, 18/27 (66.7%) of adenocarcinoma, 4/10 (40.0%) of large cell carcinoma, 5/8 (62.5%) of carcinoid tumor and 5/5 (100%) of other histological subtypes minor represented. No association between EGFR expression and histological subtype of tumors were detected. Of interest, the mucin production was evidenced in 26/42 (61.9%) of these EGFR positive cases Table 3. Consequently, the expression of EGFR was associated with mucin hyperproduction ( $p = 0.0205$ , Chi-Square test) (Figure 2).

**Table 1:** Clinicopathological characteristics of NSCLC patients.

Features	No. of cases (%) (n = 71)
Gender	
Female	25 (35.2)
Male	46 (64.8)
Age (years)	
< 60	46 (64.8)
$\geq$ 60	25 (35.2)
Tumor size (cms)	
< 3	23 (32.4)
$\geq$ 3	48 (67.6)
Regional lymph node metastasis	
No	48 (67.6)
Yes	23 (32.4)
Distant metastasis	
No	64 (90.1)
Yes	7 (9.9)
Tumor stage	
I	43 (60.6)
II	13 (18.3)
III	9 (12.7)
IV	6 (8.4)
Histology	
Squamous carcinoma	21 (29.6)
Adenocarcinoma	27 (38.0)
Large cell carcinoma	10 (14.1)
Carcinoid tumor	8 (11.3)
Other histological subtypes*	5 (7.0)
Degree of histological differentiation	
Well	21 (29.6)
Moderate	27 (38.0)
Poor/ Undifferentiated	23 (32.4)
Degree of cytological atypia	
Low	36 (50.7)
Moderate	23 (32.4)
High	12 (16.9)

Legend: No, number; %, percentages; cm, centimeters; \* 2 adenosquamous carcinoma, 1 pleomorphic carcinoma, 2 mucoepidermoid carcinoma.

**Table 2:** Mucin production according to histopathological characteristic of tumors.

Pathological features	Mucin production		Positive/total (%)	p value
	Negative	Positive		
Histological classification				
Squamous cell carcinoma	20	1	4.8	< 0.0001
Adenocarcinoma	4	23	85.2	
Large cell carcinoma	6	4	40.0	
Carcinoid tumor	5	3	37.5	
Other histological subtypes*	1	4	80.0	
Degree of histological differentiation				
Well	4	8	66.7	ns
Moderate	18	13	41.9	
Poor	14	14	50.0	
Degree of cytological atypia				
Low	20	16	44.4	0.0325
Moderate	14	9	39.1	
High	2	10	83.3	

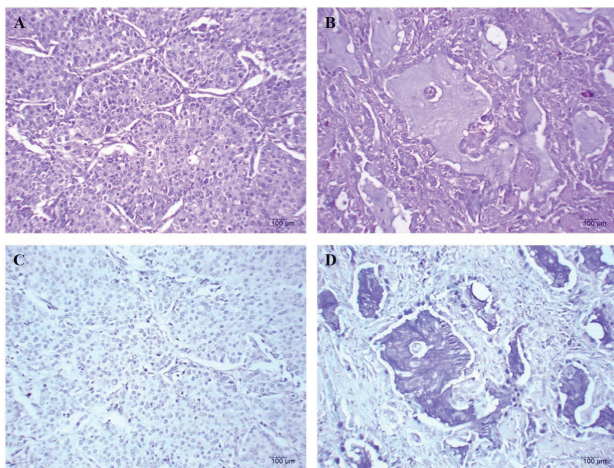
Legend: %, percentages; \* 2 adenosquamous carcinoma, 1 pleomorphic carcinoma, 2 mucoepidermoid carcinoma.

Mucoproduction is more accentuated in EGFR<sup>+</sup>/EGF<sup>+</sup> immunophenotype. On the other hand, the tissue expression EGF ligand was evidenced in 61/71 (85.9%) of NSCLC while, the presence of this molecule was detected in 42/42 (100%) of EGFR positive tissues. The simple expression of EGF was no related with mucoproduction. The mucin production was evidenced in

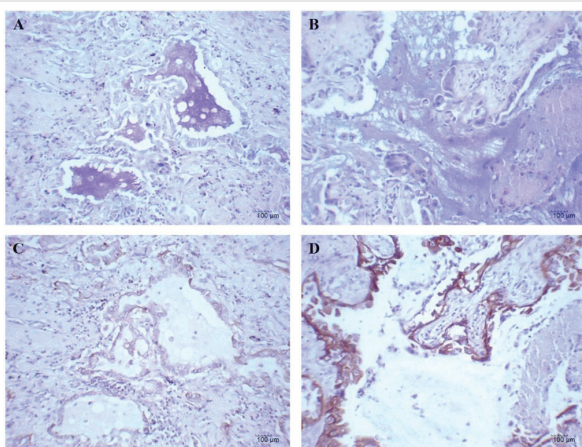
**Table 3:** Mucin production according to EGFR and EGF expression.

Variables	Mucin production		Positive/total (%)	p value
	Negative	Positive		
EGFR				
Negative	20	9	31.0	0.0205
Positive	16	26	61.9	
EGF				
Negative	6	4	40.0	ns
Positive	30	31	50.8	
Immunophenotype				
EGFR/EGF <sup>-</sup>	6	4	40.0	0.0297
EGFR/EGF <sup>+</sup>	14	5	26.3	
EGFR <sup>+</sup> /EGF <sup>+</sup>	16	26	61.9	

Legend: No, number; %, percentages; ns, no significant.



**Figure 1:** Histochemical detection of mucin in non-small cell lung cancer. A and B: hematoxylin and eosin staining of large cell carcinoma and adenocarcinoma, respectively. Observe the lack of staining in large cell carcinoma (C) and the hyperproduction of mucin in adenocarcinoma (D) (dark blue). Black bar = 100  $\mu$ m.



**Figure 2:** Mucin production and EGFR expression in lung adenocarcinomas. A: presence of mucin hyperproduction (dark blue). B: Observe a moderate expression of EGFR in the plasmatic membrane of malignant cells (brown color). C: Mucoproduction in lung adenocarcinoma (not the same as the sample shown in Fig. 2A). D: Intense expression of EGFR in malignant cells. Counterstaining with Mayers hematoxylin. Black bar = 100  $\mu$ m.

26/42 (61.9%) of EGFR<sup>+</sup>/EGF<sup>+</sup>, 5/19 (26.3%) of EGFR<sup>-</sup>/EGF<sup>+</sup> and 4/10 (40.0%) of EGFR<sup>-</sup>/EGF<sup>-</sup> samples Table 3. Consequently, the levels of mucin production was statistical significant increased in NSCLC samples displaying double expression of EGFR and its ligand the EGF ( $p = 0.0297$ , Chi-Square test) (Figure 3).

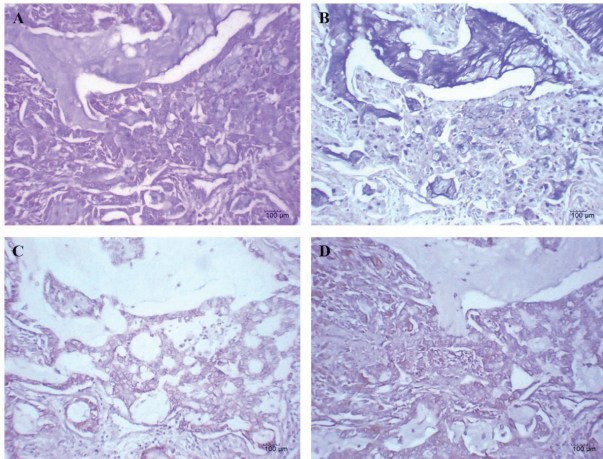
## Discussion

Mucins have been implicated in the pathogenesis of epithelial cell malignancies [17]. Alterations of the expression pattern of mucins have been described in carcinomas as well as in their precursor lesions [18,19]. Airway obstruction from mucus accumulation or from a tumor projecting into a bronchus is one of the major pathological changes in lung cancer [9]. Specifically, chronic mucus hypersecretion has been considered a significant predictor of death from lung cancer [10]. Mucinous carcinoma has been known to have a propensity for higher incidence of lymph node metastasis, venous and lymphatic invasions, local recurrence and distant metastasis compared with nonmucinous tumors [20].

The detection of certain type of mucins (MUC) by means of immunohistochemical methods has been reported to be associated with the progression of lung adenocarcinoma [21]. In a previous work, our group demonstrated that PAS-positive substances correlated with the appearance of distant metastasis in NSCLC patients [22]. Here, the occurrence of mucin production was related with the appearance of distant metastasis but also with a more advanced disease. In line with this, Yu et al., reported that MUC5B and MUC5AC overexpressing tumors tended to increase the risk of distant metastasis and decrease overall survival from lung cancer, compared with nonexpressing tumors [23]. Moreover, aberrant MUC1 expression was associated with disease progression [24] and with a poor prognosis [25,26] while, up-regulation of MUC6 expression was related with tumor size in NSCLC patients [21].

In the present study, the mucin production was mostly evidenced in adenocarcinomas as compared with the rest of lung tumors, similar to previous reports [22,27,28]. Interestingly, the presence of mucin was significantly higher in NSCLC samples displaying increased degree of cytological atypia. Previously, it was published that transmembrane mucins (e.g MUC1 and MUC4), can signal the disruption of tight junctions and adherens junctions affecting polarity as well as both cell-cell and cell-extracellular matrix interactions [19,29]. It have been also reported that overexpression of MUC1 in cancer cells alter the function of  $\beta$ -catenin/E-cadherin pathway in adherens junctions [30] inducing actin cytoskeleton alterations [31]. In this sense, the loss of polarity and cell-cell interactions could alter the cell morphology allowing to an increased cell pleomorfism and also favors the development of metastasis [32].

EGFR cascade is involved in mucin production as well as in the repair of damaged airway epithelium by a wide variety of stimuli [33]. Changes that occur during lung carcinogenesis usually conduce to dys-regulation of both mucin and EGFR expressions [5,34]. In this study, the expression of EGFR was



**Figure 3:** Mucin production in a lung adenocarcinoma displaying the EGFR+/EGF+ immunophenotype. A: hematoxylin and eosin staining. B: mucin production (dark blue). C and D: overexpression of EGFR and EGF, respectively (brown color). Observe the high expression of EGFR in the plasmatic membrane of malignant cells, while the presence of EGF ligand was mainly detected in the cytoplasm of these cells. Counterstaining with Mayers hematoxylin. Black bar = 100  $\mu$ m.

associated with mucoproduction measured by means of AB-PAS histochemical technique in NSCLC samples. Mao et al., reported a positive correlation between the expression of EGFR and MUC5AC in patients with chronic obstructive pulmonary disease [35]. However, in previous studies the EGFR mutation was related with nonmucinous bronchioloalveolar carcinoma [12,14] as well as with the lepidic-predominant form of this tumor [13].

On the other hand, the contribution of EGFR and its ligands in mucin production in normal airway epithelium using AB-PAS reaction was previously reported [36]. Co-expression of EGFR and its ligands results in activation of an autocrine system leading to dysregulated EGFR action and uncontrolled both tumor growth [37] and secretion [38]. It is known that mucins expression (e.g. MUC2 and MUC5AC) is controlled by EGF family and mitogen-activated protein kinase (MAPK) cascade [38]. Moreover, it has been reported that upregulated expression of mucins, such as MUC2 and MUC5AC, bind with EGFR and activate the Ras/Raf pathway [38,39]. In line with this, our group previously reported that the dual expression of EGFR and its ligand the EGF is related with increased cell proliferation and with a more aggressive behavior of NSCLC [16].

Interestingly, using selective inhibitors of EGFR tyrosine kinase phosphorylation, it was reported that EGFR ligand induced mucin MUC5AC synthesis is dependent on EGFR activation [36]. In this work, NSCLC samples displaying the phenotype EGFR+/EGF+ were associated with a more accentuated production of mucins as compared with EGFR+/EGF- and EGFR-/EGF- tumors. In line with this, EGFR phosphorylation upon binding to EGF and TGF- $\alpha$  resulted in a remarkable increase of MUC2 and MUC5AC mRNAs levels, promoter activity, and apomucin expression in the mucoepidermoid NCI-H292 lung cancer cell line [38]. In this sense, our results could support the role of uncontrolled EGFR system activation mediated by the ligand EGF in NSCLC mucins hyperproduction.

In view of that, it was suggested that disrupting the EGFR cascade that leads to mucus production is beneficial in airway hypersecretory diseases [40]. Interestingly, there are two different immunotherapeutic approaches registered in Cuba targeting the EGFR/EGF system. The first one is a molecular vaccine that induces anti-EGF antibodies neutralizing endogenous EGF (CIMAvaX-EGF) [41]. The other one is a humanized monoclonal antibody that directly binds the extracellular domain of the EGFR (nimotuzumab) [42]. Interestingly, promising results in advanced NSCLC patients treated with CIMAvaX-EGF [43,44] or nimotuzumab [45,46] has been obtained. In this way, the evaluation of mucin production in NSCLC patients after CIMAvaX-EGF or nimotuzumab treatment seems to be of utmost importance.

## Conclusions

The association between mucin hyperproduction and a more advanced state of NSCLC disease was demonstrated. Interestingly, mucoproduction was also related with the EGFR as well as with the double expression of EGFR and its ligand the EGF. Our results could suggest the role of mucins production mediated by EGFR/EGF stimulation in the aggressiveness of NSCLC. However, to confirm the results obtained in the present work, further studies eliminating differences in the proportion of histological subtypes and disease stages are needed. Remarkably, promising results were obtained in unresectable stage III NSCLC patients treated with an anti-MUC1 immunotherapeutic [47]. In this sense, our data permit to consider that immunotherapeutic strategies targeting EGFR and/or EGF could be a useful tools in the treatment of hypersecretory NSCLC.

## Acknowledgments

Financial support was provided by the Center of Molecular Immunology.

## Authors' contribution

Rancés Blanco and Charles E. Rengifo authors contributed equally to this work.

## References

1. Ferlay J, Soerjomataram I, Dikshit R, Eser S, Mathers C, et al. (2015) Cancer incidence and mortality worldwide: sources, methods and major patterns in GLOBOCAN 2012. *Int J Cancer* 136: E359-386. [Link: https://goo.gl/X2KoFI](https://goo.gl/X2KoFI)
2. Giaccone G, Zucali PA (2008) Src as a potential therapeutic target in non-small-cell lung cancer. *Ann Oncol* 19: 1219-1223. [Link: https://goo.gl/femwYy](https://goo.gl/femwYy)
3. Barzi A, Pennell NA (2010) Targeting angiogenesis in non-small cell lung cancer: agents in practice and clinical development. *EJCMO* 2: 31-42. [Link: https://goo.gl/SZueDo](https://goo.gl/SZueDo)
4. Berghmans T, Paesmans M, Sculier JP (2011) Prognostic factors in stage III non-small cell lung cancer: a review of conventional, metabolic and new biological variables. *Ther Adv Med Oncol* 3: 127-138. [Link: https://goo.gl/jacdNv](https://goo.gl/jacdNv)
5. Copin MC, Devisme L, Buisine MP, Marquette CH, Wurtz A, et al. (2000) From normal respiratory mucosa to epidermoid carcinoma: expression of human mucin genes. *Int J Cancer* 86:162-168. [Link: https://goo.gl/n2jmtG](https://goo.gl/n2jmtG)

6. Rose MC, Voynow JA (2006) Respiratory tract mucin genes and mucin glycoproteins in health and disease. *Physiol Rev* 86: 245-278. [Link: https://goo.gl/6L89UT](https://goo.gl/6L89UT)
7. Lakshmanan I, Ponnusamy MP, Macha MA, Haridas D, Majhi PD, et al. (2015) Mucins in lung cancer: diagnostic, prognostic, and therapeutic implications. *J Thorac Oncol* 10: 19-27. [Link: https://goo.gl/uQmS68](https://goo.gl/uQmS68)
8. Komatsu M, Yee L, Carraway KL (1999) Overexpression of sialomucin complex, a rat homologue of MUC4, inhibits tumor killing by lymphokine-activated killer cells. *Cancer Res* 59: 2229-2236. [Link: https://goo.gl/whzKjP](https://goo.gl/whzKjP)
9. Des Jardins T, Burton GG (2016) Cancer of the Lung. In *Clinical Manifestations and Assessment of Respiratory Disease*. 7th edition. St. Louis, Mo: Mosby, 374-394. [Link: https://goo.gl/w7yoKi](https://goo.gl/w7yoKi)
10. Lange P, Nyboe J, Appleyard M, Jensen G, Schnohr P (1990) Ventilatory function and chronic mucus hypersecretion as predictors of death from lung cancer. *Am Rev Respir Dis* 141: 613-617. [Link: https://goo.gl/sJM3rM](https://goo.gl/sJM3rM)
11. Usman Ali, Nagi AH, Naseem N, Ullah E (2012) Mucin Histochemistry in Tumours of Colon, Ovaries and Lung. *J Cytol Histol* 3:163. [Link: https://goo.gl/esVnhf](https://goo.gl/esVnhf)
12. Sakuma Y, Matsukuma S, Yoshihara M, Nakamura Y, Noda K, et al. (2007) Distinctive Evaluation of Nonmucinous and Mucinous Subtypes of Bronchioloalveolar Carcinomas in EGFR and K-ras Gene-Mutation Analyses for Japanese Lung Adenocarcinomas. *Am J Clin Pathol* 128: 100-108. [Link: https://goo.gl/IJxB3p](https://goo.gl/IJxB3p)
13. Kadota K, Yeh YC, D'Angelo SP, Moreira AL, Kuk D, et al. (2014) Associations between mutations and histologic patterns of mucin in lung adenocarcinoma: invasive mucinous pattern and extracellular mucin are associated with KRAS mutation. *Am J Surg Pathol* 38: 1118-1127. [Link: https://goo.gl/bZpznS](https://goo.gl/bZpznS)
14. Franklin WA, Gumerlock PH, Crowley J, Chansky K, West HJ, et al. (2003) EGFR, HER2 and ERB-B pathway activation in bronchioloalveolar carcinoma (BAC): Analysis of SWOG 9417 and lung SPORE tissue samples. *Proc Am Soc Clin Oncol* 22: 620.
15. Rengifo CE, Blanco R, Blanco D, Cedeño M, Frómata M, et al. (2013) Immunohistochemical Characterization of Three Monoclonal Antibodies Raised against the Epidermal Growth Factor and Its Receptor in Non-Small-Cell Lung Cancer: Their Potential Use in the Selection of Patients for Immunotherapy. *J Biomark* 2013: 627845. [Link: https://goo.gl/8TqqZF](https://goo.gl/8TqqZF)
16. Blanco R, Domínguez E, Morales O, Blanco D, Martínez D, et al. (2015) Prognostic significance of N-Glycolyl GM3 ganglioside expression in non-small cell lung carcinoma patients: new evidences. *Patholog Res Int* 2015: 132326. [Link: https://goo.gl/BNIRht](https://goo.gl/BNIRht)
17. Hollingsworth MA, Swanson BJ (2004) Mucins in cancer: protection and control of the cell surface. *Nat Rev Cancer* 4: 45-60. [Link: https://goo.gl/Bc5YL3](https://goo.gl/Bc5YL3)
18. Singh AP, Moniaux N, Chauhan SC, Meza JL, Batra SK (2004) Inhibition of MUC4 expression suppresses pancreatic tumor cell growth and metastasis. *Cancer Res* 64: 622-630. [Link: https://goo.gl/KBsEjD](https://goo.gl/KBsEjD)
19. Kufe DW (2009) Mucins in cancer: function, prognosis and therapy. *Nat Rev Cancer* 9: 874-885. [Link: https://goo.gl/1NOZTd](https://goo.gl/1NOZTd)
20. Yamamoto S, Mochizuki H, Hase K (1993) Assessment of clinicopathologic features of colorectal mucinous adenocarcinoma. *Am J Surg* 166: 257-261. [Link: https://goo.gl/J4f8ba](https://goo.gl/J4f8ba)
21. Awaya H, Takeshima Y, Yamasaki M, Inai K (2004) Expression of MUC1, MUC2, MUC5AC, and MUC6 in Atypical Adenomatous Hyperplasia, Bronchioloalveolar Carcinoma, Adenocarcinoma With Mixed Subtypes, and Mucinous Bronchioloalveolar Carcinoma of the Lung. *Am J Clin Pathol* 121: 644-653. [Link: https://goo.gl/ReKXRK](https://goo.gl/ReKXRK)
22. Blanco R, Rengifo ChE, Cedeño M, Reyes K, Frómata M, et al. (2015) Histochemical detection of carbohydrates in non-small cell carcinoma sections: its association with some clinic-pathological features. *JOBARI* 3: 9-17. [Link: https://goo.gl/UZbQgZ](https://goo.gl/UZbQgZ)
23. Yu CJ, Shih JY, Lee YC, Shun CT, Yuan A, et al (2005) Sialyl Lewis antigens: association with MUC5AC protein and correlation with post-operative recurrence of non-small cell lung cancer. *Lung Cancer* 47: 59-67. [Link: https://goo.gl/ECuJJJ](https://goo.gl/ECuJJJ)
24. Demirag F, Cakir E, Bayiz H, Yazici UE. (2013) MUC1 and bcl-2 expression in preinvasive lesions and adenocarcinoma of the lung. *Acta Chir Belg* 113: 19-24. [Link: https://goo.gl/yod1YP](https://goo.gl/yod1YP)
25. Nagai S, Takenaka K, Sonobe M, Ogawa E, Wada H, et al. (2006) A novel classification of MUC1 expression is correlated with tumor differentiation and postoperative prognosis in non-small cell lung cancer. *J Thorac Oncol* 1: 46-51. [Link: https://goo.gl/bd2u19](https://goo.gl/bd2u19)
26. Situ D, Wang J, Ma Y, Zhu Z, Hu Y, et al. (2011) Expression and prognostic relevance of MUC1 in stage IB non-small cell lung cancer. *Med Oncol* 28: 596-604. [Link: https://goo.gl/aEFSOX](https://goo.gl/aEFSOX)
27. Ocque R, Tochigi N, Ohori NP, Dacic S (2011) Usefulness of Immunohistochemical and Histochemical Studies in the Classification of Lung Adenocarcinoma and Squamous Cell Carcinoma in Cytologic Specimens. *Am J Clin Pathol* 136: 81-87. [Link: https://goo.gl/3zux6s](https://goo.gl/3zux6s)
28. Dubinski W, Leigh NB, Tsao MS, Hwang DM (2012) Ancillary Testing in Lung Cancer Diagnosis. *Pulm Med* 2012: 249082. [Link: https://goo.gl/9uTa3O](https://goo.gl/9uTa3O)
29. Komatsu M, Carraway C, Fregien NL, Carraway KL (1997) Reversible disruption of cell-matrix and cell-cell interactions by overexpression of sialomucin complex. *J Biol Chem* 272: 33245-3354. [Link: https://goo.gl/33liiq](https://goo.gl/33liiq)
30. Yamamoto M, Bharti A, Li Y, Kufe D (1997) Interaction of the DF3/MUC1 breast carcinoma-associated antigen and  $\beta$ -catenin in cell adhesion. *J Biol Chem* 272: 12492-12494. [Link: https://goo.gl/uL9Xz0](https://goo.gl/uL9Xz0)
31. Nelson WJ (2008) Regulation of cell-cell adhesion by the cadherin-catenin complex. *Biochem Soc Trans* 36: 149-155. [Link: https://goo.gl/eHkeHU](https://goo.gl/eHkeHU)
32. Komatsu M, Tatum L, Altman NH, Carothers Carraway CA, Carraway KL (2000) Potentiation of metastasis by cell surface sialomucin complex (rat MUC4), a multifunctional anti-adhesive glycoprotein. *Int J Cancer* 87: 480-486. [Link: https://goo.gl/D7RuH8](https://goo.gl/D7RuH8)
33. Puddicombe SM, Polosa R, Richter A, Krishna MT, Howarth PH, et al. (2000) Involvement of the epidermal growth factor receptor in epithelial repair in asthma. *FASEB J* 14: 1362-1374. [Link: https://goo.gl/EGAC8v](https://goo.gl/EGAC8v)
34. Piythilake CJ, Frost AR, Manne U, Weiss H, Bell WC, et al. (2002) Differential expression of growth factors in squamous cell carcinoma and precancerous lesions of the lung. *Clin Cancer Res* 8: 734-744. [Link: https://goo.gl/OHp93D](https://goo.gl/OHp93D)
35. Mao L, Bai CX, Zhang M, Wang YH, Chen J (2004) Expression of epidermal growth factor receptor and MUC5AC on human airway with chronic obstructive pulmonary disease. *Chinese journal of tuberculosis and respiratory diseases* 27: 585-588. [Link: https://goo.gl/U6nEzB](https://goo.gl/U6nEzB)
36. Takeyama K, Dabbagh K, Lee HM, Agustí C, Lausier JA, et al. (1999) Epidermal growth factor system regulates mucin production in airways. *Proc Natl Acad Sci USA* 96: 3081-3086. [Link: https://goo.gl/DdCk0h](https://goo.gl/DdCk0h)
37. Arteaga CL (2002) Epidermal Growth Factor Receptor Dependence in Human Tumors: More Than Just Expression? *Oncologist* 7: 31-39. [Link: https://goo.gl/mXujXl](https://goo.gl/mXujXl)
38. Perraiss M, Pigny P, Copin MC, Aubert JP, Van Seuninghen I (2002) Induction of MUC2 and MUC5AC mucins by factors of the epidermal growth factor (EGF) family is mediated by EGF receptor/Ras/Raf/extracellular signal-regulated kinase cascade and Sp1. *J Biol Chem* 277: 32258-32267. [Link: https://goo.gl/M2orKH](https://goo.gl/M2orKH)

39. Kim S, Lewis C, Nadel JA (2011) CCL20/CCR6 feedback exaggerates epidermal growth factor receptor-dependent MUC5AC mucin production in human airway epithelial (NCI-H292) cells. *J Immunol* 186: 3392-3400. [Link: https://goo.gl/mr7AKV](https://goo.gl/mr7AKV)
40. Burgel PR, Nadel JA (2004) Roles of epidermal growth factor receptor activation in epithelial cell repair and mucin production in airway epithelium. *Thorax* 59: 992-996. [Link: https://goo.gl/fcVt3E](https://goo.gl/fcVt3E)
41. Gonzalez G, Crombet T, Catala M, Mirabal V, Hernandez JG, et al. (1998) A novel cancer vaccine composed of human-recombinant epidermal growth factor linked to a carrier protein: Report of a pilot clinical trial. *Ann Oncol* 9: 431-435. [Link: https://goo.gl/EHy6NQ](https://goo.gl/EHy6NQ)
42. Crombet-Ramos T, Rak J, Perez R, Vilorio-Petit A (2002) Antiproliferative, antiangiogenic and proapoptotic activity of h-R3: A humanized anti-EGFR antibody. *Int J Cancer* 101: 567-575. <https://goo.gl/D0L9SN>
43. García B, Neningen E, de la Torre A, Leonard I, Martínez R, et al. (2008) Effective inhibition of the epidermal growth factor/epidermal growth factor receptor binding by anti-epidermal growth factor antibodies is related to better survival in advanced non-small-cell lung cancer patients treated with the epidermal growth factor cancer vaccine. *Clin Cancer Res* 14: 840-846. [Link: https://goo.gl/XRYSjV](https://goo.gl/XRYSjV)
44. Neningen Vinageras E, de la Torre A, Osorio Rodríguez M, Catalá Ferrer M, Bravo I, et al. (2008) Phase II randomized controlled trial of an epidermal growth factor vaccine in advanced non-small-cell lung cancer. *J Clin Oncol* 26: 1452-1458. [Link: https://goo.gl/7Ock7i](https://goo.gl/7Ock7i)
45. Choi HJ, Sohn JH, Lee CG, Shim HS, Lee IJ, et al. (2010) A phase I study of nimotuzumab in combination with radiotherapy in stages IIB-IV non-small cell lung cancer unsuitable for radical therapy: Korean results. *Lung Cancer* 71: 55-59. [Link: https://goo.gl/qyhdm](https://goo.gl/qyhdm)
46. Wang HQ, Ren Y, Qian ZZ, Fu K, Zhang HL, et al. (2012) Nimotuzumab combined with gemcitabine and cisplatin as second-line chemotherapy for advanced non-small-cell lung cancer. *Thoracic Cancer* 3: 72-78. [Link: https://goo.gl/SDX0Li](https://goo.gl/SDX0Li)
47. Mitchell P, Thatcher N, Socinski MA, Wasilewska-Tesluk E, Horwood K, et al. (2015) Tecemotide in unresectable stage III non-small-cell lung cancer in the phase III START study: updated overall survival and biomarker analyses. *Ann Oncol* 26: 1134-114. [Link: https://goo.gl/kVxfIC](https://goo.gl/kVxfIC)