



CLINICAL GROUP

Terence E McManus^{1,2*}, Carole A Cooke³, John Wilson⁴ and Ken F Whyte²

¹Department of Respiratory Medicine, South West Acute Hospital, Enniskillen, Northern Ireland, BT74 6DN. UK

²Department of Respiratory Medicine, Auckland City Hospital, Auckland, New Zealand

³Department of Ophthalmology, South West Acute Hospital, Enniskillen, Northern Ireland, BT74 6DN, UK

⁴Department of Neuroradiology, Auckland City Hospital, Auckland, New Zealand

Dates: Received: 28 September, 2017; Accepted: 23 October, 2017; Published: 24 October, 2017

***Corresponding author:** Terence E McManus, Department of Respiratory Medicine, South West Acute Hospital, Enniskillen, Northern Ireland, BT74 6DN, and, Auckland City Hospital, Auckland, New Zealand, Tel: + (44) 2866382000; Fax: + (44) 2866382657; E-Mail: Terence.McManus@westerntrust.hscni.net

Keywords: Syringomyelia; Nystagmus; Vocal cord palsy; Sleep apnea; Hiccups

<https://www.peertechz.com>

Case Report

Syringomyelia Presenting As Obstructive Sleep Aponea

Summary

The authors describe a case of syringomyelia associated with Chiari malformation Type I in a patient who was referred to a respiratory service with features of obstructive sleep apnoea. The patient exhibited clinical features of scoliosis, hoarseness, sensory and motor neurological deficit and vertical upbeat jerk nystagmus. The authors review the various factors in the pathogenesis of this unusual constellation of symptoms, signs and radiological findings.

Otorhinolaryngology examination there were findings of a right recurrent laryngeal nerve palsy with no identifiable cause.

Chest x-ray demonstrated a scoliosis but was otherwise normal (Figure S1). CT scan of chest and neck showed subtle deviation of the left vocal cord medially, suggestive of a left vocal cord palsy (Figure S2). There were no masses along the expected tract of the left recurrent laryngeal nerve. No significant cervical lymphadenopathy and no abnormal masses were visualized within the neck. MRI of the spine demonstrated a Chiari I malformation (Figure 1). Although it did not appear to cause compression of the medulla or upper cord there was an associated thin but extensive syrinx throughout the cervical and upper thoracic regions (Figure 2). Multichannel polysomnography demonstrated frequent obstructive apnoeas (Figure S3), but a significant number of central or "mixed" apnoeas were also seen (Figure S4). The total arousal Index was 15.2/hr, associated with respiratory events. The Apnoea

Case Report

Clinical history and examination

A 19 year old man was referred to the sleep service with a two year history of loud snoring and daytime hypersomnolence. He had lost approximately 20kg in weight over the previous eighteen months with no appreciable symptomatic change. He described short sleep latency, unrefreshing sleep however he did have good sleep hygiene, Epworth score was 14/24. He also described a two year history of hoarseness which initially developed following a three week episode of persistent hiccups. He had sung on a regular basis prior to this episode but was unable to subsequently. There was no past medical history of note and he was not taking any regular medication.

On examination he was of muscular build, weight 84.4Kg, BMI 29.6 KgM⁻². Cardio-respiratory examination was normal as was examination of the oropharynx. He was also noted to have vertical upbeat jerk nystagmus in the primary position persisting in all directions of gaze. Further neurological examination revealed bilateral weakness on finger and thumb abduction (grade 4/5) with brisk knee and ankle reflexes. Sensation mapping demonstrated a deficit in pain and temperature around the hairline of the face, back of neck, both shoulders and along the entire right arm. On subsequent

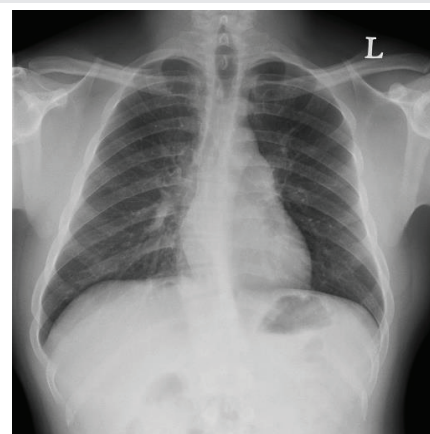


Figure S1:

and Hypopnea Index was 28/hr. Flow volume loop (Figure S5) demonstrated flattening of the inspiratory loop in keeping with the vocal cord palsy. The patient was assessed by the neurosurgical service and boarded for a craniocervical decompressive procedure.

Discussion

Syringomyelia is the development of a fluid-filled cavity or syrinx within the spinal cord. The most common type of syringomyelia is due to blockage of cerebrospinal fluid (CSF) circulation.[1] Obstruction of CSF circulation from the basal posterior fossa to the caudal space may cause syringomyelia

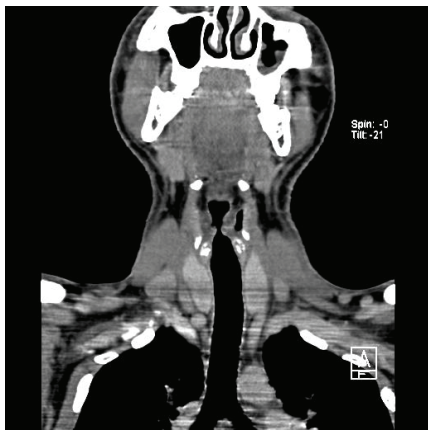

Figure S2:

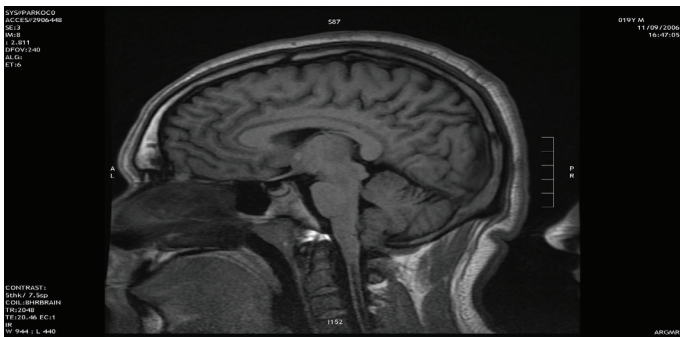


Figure 1:

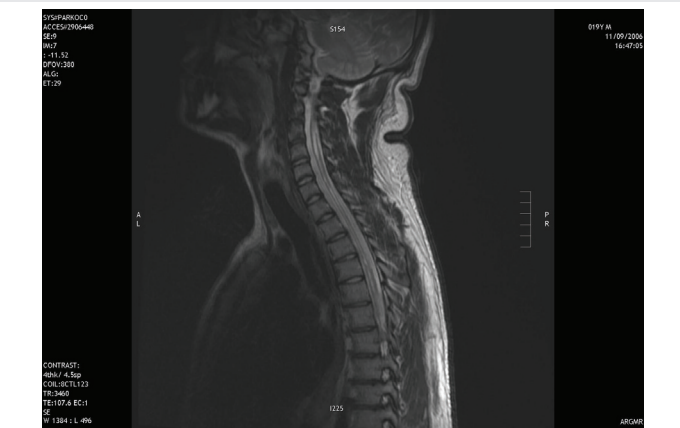

Figure 2:

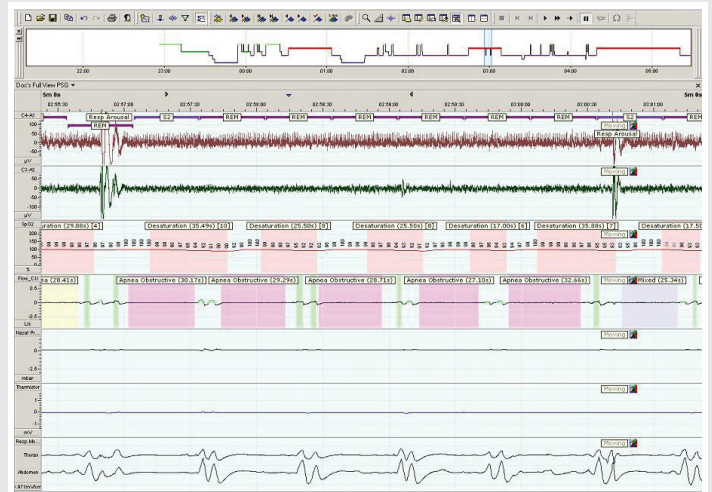


Figure S3:

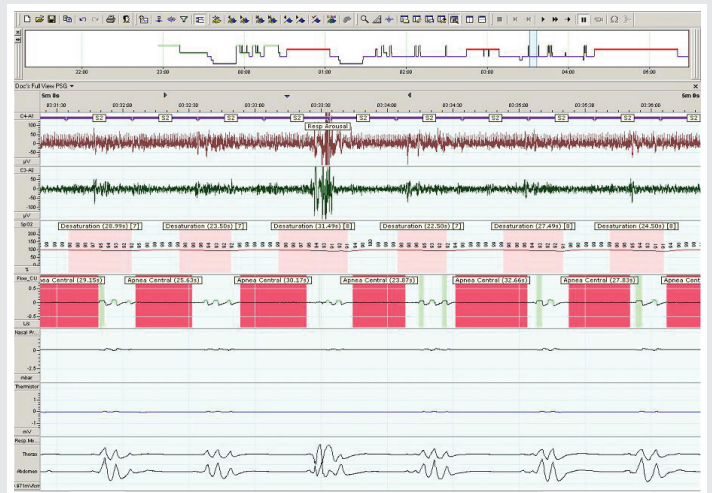


Figure S4:

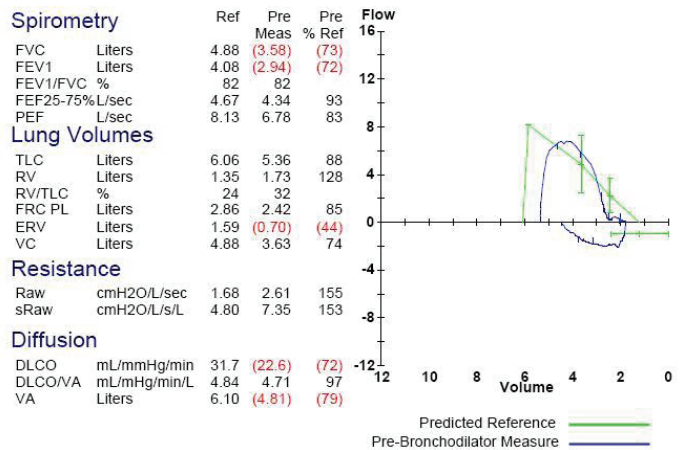


Figure S5:

of this type, the most common example being the Arnold-Chiari malformation. Although many mechanisms for syrinx formation have been postulated, the exact pathogenesis is still unknown. Frequently cited theories in cases with Arnold-Chiari malformation are those of William, and Oldfield [1].

Signs and symptoms of neurological dysfunction that appear with distension of the syrinx are due to compression of long tracts, neurons, and microcirculation. Symptoms referable to raised intramedullary pressure are potentially reversible by syrinx decompression. Syringomyelia usually involves the cervical area, symptomatic presentation depends primarily on the location of the lesion within the neuraxis.

Examination of the clinical manifestations and relation to their pathogenesis in this case follows;

Syrinx interrupts the decussating spinothalamic fibers that mediate pain and temperature sensibility, resulting in loss of these sensations (dissociated sensory loss). Pain and temperature sensation may be impaired in either or both arms, or in a shawl-like distribution across the shoulders and upper torso anteriorly and posteriorly.

Syrinx extension into the anterior horns of the spinal cord damages motor neurons (lower motor neuron) and causes diffuse muscle atrophy that begins in the hands and progresses proximally to include the forearms and shoulder girdles. Lower limb spasticity, which may be asymmetrical, appears with other long-tract signs such as paraparesis, hyperreflexia, and extensor plantar responses.

Syringomyelia is a recognized etiological factor in the development of Charcot's joints. Neuropathic joint disease or Charcot joints are a chronic form of a degenerative arthropathy that is associated with decreased sensory innervation of the involved joints [2]. Neurogenic arthropathies may affect the shoulder, elbow, or wrist, scoliosis is seen sometimes in association with this process as in this case [3].

Patients with craniocervical disorders show a wide variety of symptoms and signs suggesting cerebellar and/or high cervical lesion. The anatomic localization of respiratory centers and their possible injury may explain the presence of respiratory disturbances in these diseases [4]. Botelho *et al.* described the polysomnographic findings in a group of patients with craniocervical disorders. Ninety percent of these patients complained of sleep problems (snoring, choking, and witnessed apneas) and 72% presented hypersomnolence (ESS >9) [4].

Observations of obstructive sleep apnoea in patients with ischaemic pontomedullary lesions, syringobulbia, syringomyelia, olivo-ponto-cerebellar atrophy or disseminated encephalopathy have indicated that it is due to impairment of inspiration-synchronous activation [5].

Brainstem signs are common in syringomyelia associated with Chiari malformations. In addition to the well-recognised sign of downbeat nystagmus, classically associated with foramen magnum abnormalities, a number of other ophthalmic features can be identified [6]. Symptoms include diplopia, oscillopsia, tunnel vision and difficulty in lateral gaze. Signs include nystagmus (downbeat, horizontal, rotatory, and

combinations), strabismus, disc pallor, anisocoria, ptosis and field defect. In most cases nystagmus will improve or resolve following treatment [7].

Syringomyelia and Chiari type 1 malformation have previously been described in association with bilateral vocal cord paralysis and obstructive sleep apnoea syndrome [8]. A further case report describes bilateral abductor vocal cord paralysis and sleep apnoea developing precipitously following general anesthesia. Subsequent investigation demonstrated a type-I Chiari malformation with syringomyelia. The authors conclude that brainstem abnormalities such as Chiari malformation with secondary tenth cranial nerve deficits should be considered in previously healthy patients with signs and symptoms of upper airway obstruction and apnoea [9]. Flattening of the inspiratory loop on the flow-volume curve was found on pulmonary function testing, suggesting a variable extra-thoracic obstruction due to a laryngeal lesion [8].

Approximately 20 to 50% of patients with syringomyelia associated with Chiari malformations exhibit cranial nerve or cerebellar symptoms. However, hiccups represent a rare clinical manifestation of this disorder. In this case it is postulated that the initial presentation of intractable hiccups for 3 weeks heralded the early development of syringomyelia secondary to an Arnold-Chiari malformation.

Conclusion

Clinicians should consider Chiari malformation as a cause of sleep disturbed breathing and posterior fossa decompression as a potential treatment.

Acknowledgements

Nimi Sharma and Shannon Young, sleep technologists, sleep service, Auckland city Hospital. Ewan Morris, respiratory physiologist, Greenlane clinical centre, Auckland.

References

1. Di Lorenzo N, Cacciola F (2005) Adult syringomyelia. Classification, pathogenesis and therapeutic approaches. *J Neurosurg Sci* 49: 65-72. [Link: https://goo.gl/U6MMa5](https://goo.gl/U6MMa5)
2. Gupta R (1993) A short history of neuropathic arthropathy. *Clin Orthop Relat Res* 296: 43-49. [Link: https://goo.gl/Lq5PQj](https://goo.gl/Lq5PQj)
3. Spiegel DA; Flynn JM; Stasikelis PJ; Dormans, JP; Drummond DS; et al. (2003) Scoliotic curve patterns in patients with Chiari I malformation and/or syringomyelia. *Spine* 28: 2139-2146. [Link: https://goo.gl/pTM1Tt](https://goo.gl/pTM1Tt)
4. Botelho RV, Bittencourt LR, Rotta JM, Tufik S (2000) Polysomnographic respiratory findings in patients with Arnold-Chiari type I malformation and basilar invagination, with or without syringomyelia: preliminary report of a series of cases. *Neurosurg Rev* 23: 151-155. [Link: https://goo.gl/ASjRp9](https://goo.gl/ASjRp9)
5. Schlegel J, Urban PP (1999) Electrophysiological brain-stem diagnosis in patients with a pronounced obstructive sleep apnea syndrome. *Dtsch Med Wochenschr* 124: 613-617. [Link: https://goo.gl/BNUKAK](https://goo.gl/BNUKAK)
6. Rowlands A, Sgouros S, Williams B (2000) Ocular manifestations of hindbrain-related syringomyelia and outcome following craniocervical decompression. *Eye* 14: 884-888. [Link: https://goo.gl/TNwgSC](https://goo.gl/TNwgSC)

7. Dones J, De Jesus O, Colen CB, Maria MT, Mariel D, et al. (2003) Clinical outcomes in patients with Chiari I malformation: a review of 27 cases. *Surg Neurol* 60: 142-147. [Link: https://goo.gl/Wz7SZi](https://goo.gl/Wz7SZi)
8. Fernandez Sanchez LJ, Guasch AE, Perez GR, Gilsanz, RF, Revista EA; et al. (2005) Syringomyelia and Chiari type 1 malformation with associated bilateral vocal cord paralysis and obstructive sleep apnea syndrome. *Rev Esp Anesthesiol Reanim* 52: 639-641. [Link: https://goo.gl/QcL8mm](https://goo.gl/QcL8mm)
9. Ruff ME, Oakes WJ, Fisher SR, Alexander S (1987) Sleep apnea and vocal cord paralysis secondary to type I Chiari malformation. *Pediatrics* 80: 231-234. [Link: https://goo.gl/CmqGmV](https://goo.gl/CmqGmV)

Copyright: © 2017 McManus TE, et al. This is an open-access article distributed under the terms of the Creative Commons Attribution License, which permits unrestricted use, distribution, and reproduction in any medium, provided the original author and source are credited.