

Sho Dohzono^{1*}, Sadahiko Konishi²,
Hidetomi Terai¹, Hiromitsu Toyoda¹,
Akinobu Suzuki¹ and Hiroaki
Nakamura¹

¹Department of Orthopaedic Surgery, Osaka City
University Graduate School of Medicine, Osaka, Japan

²Department of Orthopaedic Surgery, JR Osaka
railway hospital, 1-2-22 Matsuzakicho Abeno-ku,
Osaka 545-0021, Japan

Dates: Received: 25 April, 2014; Accepted: 21
June, 2014; Published: 23 June, 2014

***Corresponding author:** Sho Dohzono, MD,
Department of Orthopaedic Surgery, Osaka City
University Graduate School of Medicine, 1-4-3
Asahimachi, Abeno-ku, Osaka, Osaka, Japan, 545-
8585, Tel: +81-6-6645-3851; Fax: +81-6-6646-6260;
E-mail: s.dohzono@med.osaka-cu.ac.jp

www.peertechz.com

ISSN: 2455-5282

Keywords: Adjacent segment disease;
Cervical laminoplasty; Cervico-thoracic junction;
Anterolisthesis

Case Report

Compression Myelopathy Caused by Anterolisthesis and Hypertrophic Ligamentumflavum in the Adjacent Segment 11 years after Cervical Laminoplasty-A Case Report and Review of the Literature

Abstract

Introduction: Symptomatic adjacent segment disease after anterior cervical decompression and fusion has been well described, but there have been few reports of symptomatic adjacent segment disease after cervical laminoplasty.

Case report: The authors report on a 69-year-old female gradually developed gait disturbance due to C7 anterolisthesis and ligamentumflavum thickening with an onset 11 years after conventional C3-7 laminoplasty. The patient underwent laminectomy from C6 to T1 and was able to return to ambulation. However, she experienced further deterioration in her ambulatory status four years after the second surgery, due to further anterior slippage of C7. Finally, she underwent posterior decompression and fusion from C5 to T3. The patient was able to return to ambulation with the assistance of a cane despite some level of spasticity.

Conclusion: Compression myelopathy may occur as a late effect adjacent segment disease that produces a deteriorated condition after conventional cervical laminoplasty. Anterolisthesis with thickened ligamentumflavum at the cervico-thoracic junction needs to be fused and instrumented.

Abbreviations

ROM: Range of Motion

Introduction

Cervical laminoplasty was first reported by Hirabayashi in 1983 [1]. This method has become the gold standard for cervical myelopathy surgical interventions, particularly when there is multilevel involvement. Good long term surgical outcomes have been reported with this procedure [2-6].

However, anterior cervical fusion is still a widely used procedure for cases having a lesion at one or two levels.

Several studies compared the surgical outcomes and complications for these two procedures [7-15]. There appeared to be no difference in clinical outcome, but a de-novo lesion has been reported as an adjacent segment disease with long-term follow up after anterior fusion.

Recently we experienced a rare case of cervico-thoracic spondylolisthesis with hypertrophy of the ligamentumflavum as an adjacent segment disease 11 years after conventional C3-C7

laminoplasty. The purpose of this paper is to describe the details of this rare case and review the literature.

Case Presentation

A 69-year-old woman was admitted to our department due to gradual onset of difficulty in walking. She had undergone a spinous process-splitting laminoplasty from C3 to C7 11 years ago. The surgical results were uneventful, and she had been free from the preoperative symptoms for ten years.

She presented with a twelve month history of bilateral lower extremity numbness and muscle weakness. Though the symptoms were getting worse, she had not previously had a medical examination. She was subsequently transferred to the emergency room due to lower extremity paresis.

She was not able to stand up or ambulate at the time of admission. Physical examination revealed significant motor weakness in both lower extremities. Sensory disturbance was observed on her trunk and both lower extremities.

Plain X-ray of the cervical spine three years after laminoplasty showed facet joint osteoarthritis at C7-T1 that was not observed at

the previous surgery (Figure 1). ROM of the cervical spine measured by the tangential line of the posterior vertebral body between C2 and C7 decreased from 43 degrees before laminoplasty to 22 degrees 11 years after the original laminoplasty. Magnetic resonance images demonstrated spinal cord compression at C7-T1 with anterior slippage of C7 and ligamentumflavum hypertrophy that was not observed one month after laminoplasty (Figure 2).

The operative treatment was performed due to the deterioration in neurological findings. The hydroxyapatite spacers on the spinous process at C6 and C7 were removed, and laminectomy from C6 to T1 was performed. Intraoperative findings revealed that the yellow ligament was thickened between C7 and T1, which adhered to and compressed the dural sac. Histological examination showed marked fibrous and degenerative change of this ligament (Figure 3).

Her numbness improved immediately after the surgery and lower extremity muscle strength gradually increased. She was discharged 40 days after surgery and was able to ambulate independently at the time of discharge. Plain radiography one year after laminectomy revealed that the C7 slippage had progressed slightly, but did not increase in the flexed position when compared with the extended position. Magnetic resonance imaging demonstrated adequate decompression of the spinal cord at the C7-T1 level (Figure 4).

Four years after laminectomy, her ambulatory status declined after a fall. Her neurological function deteriorated and she again became wheelchair dependent. Magnetic resonance images revealed progression of the C7 anterior slippage and cord compression was apparent at C7-T1. CT imaging revealed a 60% anterior slippage of C7 on T1. The patient underwent decompression between C6 and T1 with an instrumented fusion from C5 to T3 using lateral mass screws and pedicle screws (Figure 5). The patient had gradual improvement in neurological function after surgery and was able to ambulate with a walker.

The patient continues to ambulate with a walker despite some residual spasticity at six months after the latest surgical intervention. Magnetic resonance images demonstrated adequate decompression

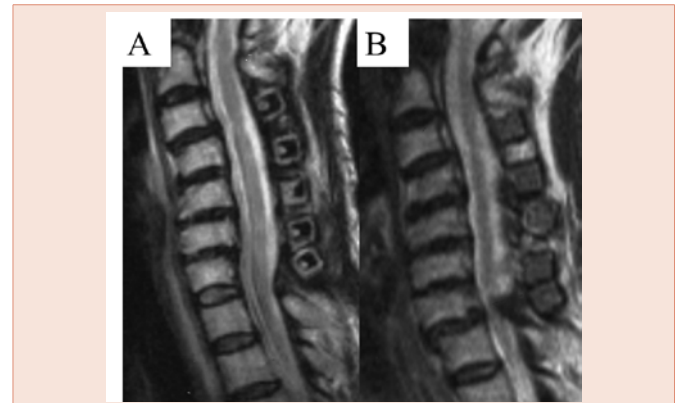


Figure 2: MRI T2-weighted sagittal image one month (A) and 11years (B) after C3-7 laminoplasty (original surgery).

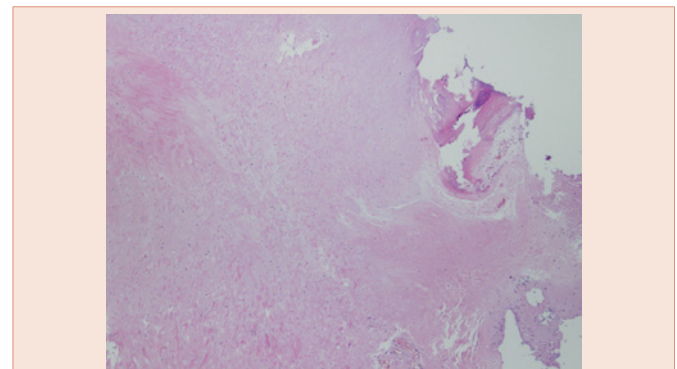


Figure 3: Low power photomicrograph of yellow ligament (ligamentumflavum) taken at the second surgery between C7 and T1 (x4).

of the spinal cord at C7-T1, and computed tomography revealed fusion of the C7-T1 vertebra (Figure 6).

Discussion

Adjacent segment disease is well described after anterior cervical decompression and fusion. Hilbrand et al. [16] reported the rate of symptomatic adjacent disc disease was 2.9% per patient per year. Survivor analysis predicted that 25% of all patients would develop adjacent segment degeneration in a series of 374 patients treated with anterior cervical fusion. Katuura et al. [17] found that 50% of patients treated with anterior cervical fusion developed adjacent-segment disease and 19% required reoperation. Ishihara et al. [18] reported the development of symptomatic adjacent-segment disease in 19 of 112 patients (19%). These adjacent segment disease states appear to be caused by the loss of motion in the fused segment.

However, cervical laminoplasty has been indicated when the patient has a narrow spinal canal or multilevel compressive lesions. The cervical laminoplasty is a motion preservation procedure. Therefore, no focal concentration of the mechanical stress would occur after this surgical procedure.

However, several articles reported loss of segmental motion after

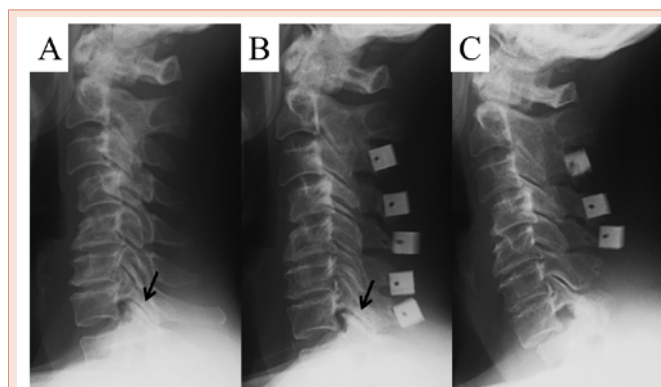


Figure 1: Plain radiography before laminoplasty (A), three years after laminoplasty (B) and seven days after second surgery. (C). This view shows facet joint osteoarthritis at C7-T1 three years after laminoplasty, which was not present preoperatively (arrow). The hydroxyapatite spacers on the spinous process at C6 and C7 were removed, and laminectomy from C6 to T1 was performed.

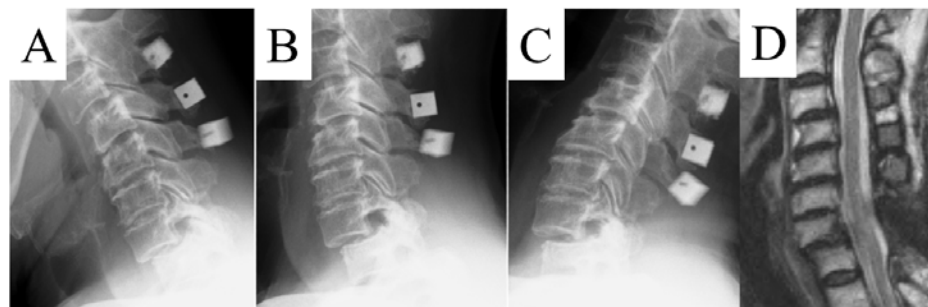


Figure 4: Plain radiography one year after laminectomy (the second surgery) from C6 to T1 in flexion (A), neutral (B) and extension (C) positions. MRI T2-weighted sagittal image one year after laminectomy (the second surgery) (D).

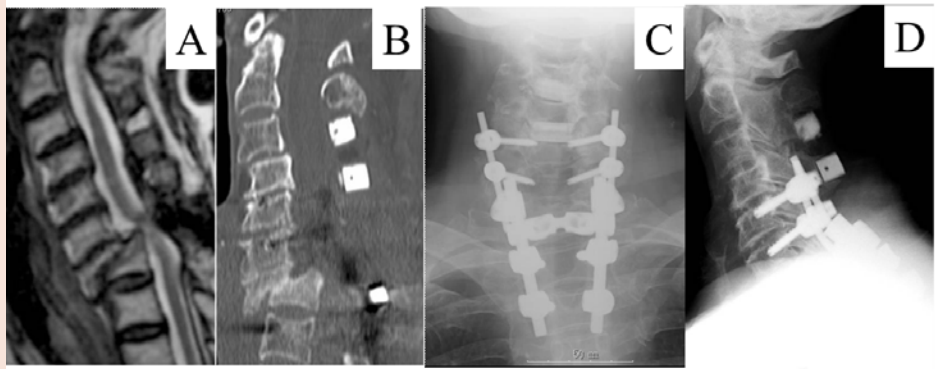


Figure 5: MRI T2-weighted sagittal image (A) and CT four years after laminectomy (the second surgery) revealed severe C7 anterolisthesis and cord compression at C7-T1. Plain radiography after decompression and fusion from C5 to T3 (C, D).

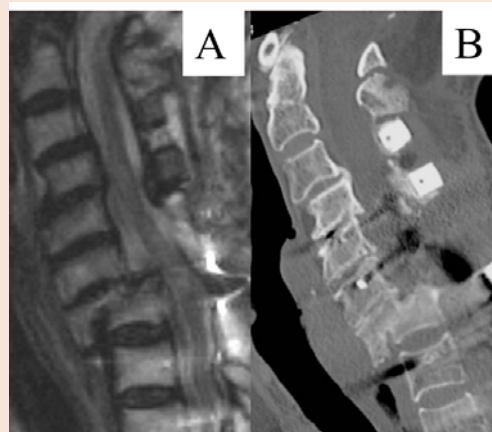


Figure 6: MRI T2-weighted sagittal image (A) and CT (B) six months after the latest surgical treatment.

laminoplasty [19-24]. Wada et al. [7] reported more than 30% ROM reduction after cervical laminoplasty. This may be the result of laminar elevation or unintended fusions caused by drilling of bone around facet joints. Iizuka et al. [19] reported postoperative interlaminar bony fusion occurred in 53% of patients after laminoplasty, reducing postoperative cervical spine sagittal ROM. Therefore, adjacent

segment diseases can develop gradually in the areas surrounding the laminoplasty.

There have been a few published reports of adjacent segment disease after cervical laminoplasty [25-27]. Takagi et al. [25] reported a case of symptomatic T1-2 ligamentumflavum hypertrophy and abrupt onset of disc herniation with an onset 11 years after a successful

C3-C7 laminoplasty. T1-2 laminectomy with disc fragment excision was performed at that level. They concluded that mechanical stresses had directly affected the T1-2 intervertebral disc after laminoplasty and caused disc herniation. Wang et al. [25] described a case of symptomatic disc degeneration and spinal cord compression at T1-2 level after C3-7 laminoplasty with partial laminectomies at C2 and T1. In that case, laminectomy with posterior instrumentation and fusion between C5 and T3 was performed.

The cervical spine flexion range of motion decreased from 43 to 22 degrees after the first laminoplasty in the current case. Therefore, long-term mechanical stress at the cervico-thoracic junction from the stiffened cervical spine articulating with the generally less mobile thoracic spine may cause the degeneration at that level. The thickened yellow ligament with C7 anterior slippage seemed to be the main component compressing the spinal cord. Therefore, careful observation is necessary for long-term follow up of cases with conventional cervical laminoplasty. There is no established surgical treatment for the cervico-thoracic spondylolisthesis. Few reports studied the progression of anterolisthesis after multilevel cervical laminectomy. Some studies reported no significant difference between the pre-and postoperative measurements of anteroposterior mobility after multilevel laminectomies [28-30]. However, Kurz [31] suggested that the presence of preoperative spondylolisthesis was indicative of segmental instability making fusion mandatory. Guigui [32] reported that preoperative spondylolisthesis with hypermobility in the sagittal plane must be fused and instrumented.

In the current case hypermobility at the cervico-thoracic junction, C7 anterior slip and hypertrophy of ligamentum flavum caused the compression myelopathy 11 years after the index surgery. The thickening of the ligamentum flavum and the anterolisthesis indicate that some component of instability existed. Therefore, laminectomy without fusion and instrumentation increased the postoperative destabilization.

Her ambulation status was improved after laminectomy the first year, but unfortunately, progression of the C7 anterolisthesis and spinal cord compression recurred four years later. Anterolisthesis with a hypertrophic ligamentum flavum at the cervico-thoracic junction needs to be fused and instrumented.

Conclusion

Adjacent segment disease is one of the complications after cervical laminoplasty. Therefore careful long-term observation for an adjacent segment lesion is necessary after conventional cervical laminoplasty. Preoperative anterolisthesis with thickened ligamentum flavum at the cervico-thoracic junction needs to be fused and instrumented.

Conflict of Interest

The authors report no conflict of interest concerning the materials or methods used in this paper.

References

1. Hirabayashi K, Watanabe K, Wakano K, Suzuki N, Satomi K, et al. (1983) Expansive open-door laminoplasty for cervical spinal stenotic myelopathy. *Spine* 8: 693-699.

2. Chiba K, Ogawa Y, Ishii K, Nakamura M, Maruiwa H, et al. (2006) Long-term results of expansive open-door laminoplasty for cervical myelopathy--average 14-year follow-up study. *Spine* 31: 2998-3005.
3. Hale JJ, Gruson KI, Spivak JM (2006) Laminoplasty: a review of its role in compressive cervical myelopathy. *Spine* J 6: 289S-298S.
4. Seichi A, Takeshita K, Ohishi I, Kawaguchi H, Akune T, et al. (2001) Long-term results of double-door laminoplasty for cervical stenotic myelopathy. *Spine* 26: 479-487.
5. Kimura A, Seichi A, Inoue H, Hoshino Y (2011) Long-term results of double-door laminoplasty using hydroxyapatite spacers in patients with compressive cervical myelopathy. *Eur Spine J* 20: 1560-1566.
6. Motosuneya T, Maruyama T, Yamada H, Tsuzuki N, Sakai H (2011) Long-term results of tension-band laminoplasty for cervical stenotic myelopathy: a ten-year follow-up. *J Bone Joint Surg Br* 93: 68-72.
7. Wada E, Suzuki S, Kanazawa A, Matsuoka T, Miyamoto S, et al. (2001) Subtotal corpectomy versus laminoplasty for multilevel cervical spondylotic myelopathy: a long-term follow-up study over 10 years. *Spine* 26: 1443-1447; discussion 1448.
8. Gandhoke G, Wu JC, Rowland NC, Meyer SA, Gupta C, et al. (2011) Anterior corpectomy versus posterior laminoplasty: is the risk of postoperative C-5 palsy different? *Neurosurgical Focus* 31: E12.
9. Liu XY, Yuan SM, Tian YH, Zheng YP, Li JM (2011) Expansive open-door laminoplasty and selective anterior cervical decompression and fusion for treatment of multilevel cervical spondylotic myelopathy. *Orthopaedic surgery* 3: 161-166.
10. Sakai K, Okawa A, Takahashi M, Arai Y, Kawabata S, et al. (2012) Five-year follow-up evaluation of surgical treatment for cervical myelopathy caused by ossification of the posterior longitudinal ligament: a prospective comparative study of anterior decompression and fusion with floating method versus laminoplasty. *Spine (Phila Pa 1976)* 37: 367-376.
11. Hirai T, Okawa A, Arai Y, Takahashi M, Kawabata S, et al. (2011) Middle-term results of a prospective comparative study of anterior decompression with fusion and posterior decompression with laminoplasty for the treatment of cervical spondylotic myelopathy. *Spine (Phila Pa 1976)* 36: 1940-1947.
12. Liu T, Yang HL, Xu YZ, Qi RF, Guan HQ (2011) ACDF with the PCB cage-plate system versus laminoplasty for multilevel cervical spondylotic myelopathy. *J Spinal Disord Tech* 24: 213-220.
13. Koakutsu T, Morozumi N, Ishii Y, Kasama F, Sato T, et al. (2010) Anterior decompression and fusion versus laminoplasty for cervical myelopathy caused by soft disc herniation: a prospective multicenter study. *J Orthop Sci* 15: 71-78.
14. Masaki Y, Yamazaki M, Okawa A, Aramomi M, Hashimoto M, et al. (2007) An analysis of factors causing poor surgical outcome in patients with cervical myelopathy due to ossification of the posterior longitudinal ligament: anterior decompression with spinal fusion versus laminoplasty. *J Spinal Disord Tech* 20: 7-13.
15. Sakaura H, Hosono N, Mukai Y, Ishii T, Iwasaki M, et al. (2005) Long-term outcome of laminoplasty for cervical myelopathy due to disc herniation: a comparative study of laminoplasty and anterior spinal fusion. *Spine (Phila Pa 1976)* 30: 756-759.
16. Hilibrand AS, Carlson GD, Palumbo MA, Jones PK, Bohlman HH (1999) Radiculopathy and myelopathy at segments adjacent to the site of a previous anterior cervical arthrodesis. *J Bone Joint Surg Am* 81: 519-528.
17. Katsuura A, Hukuda S, Saruhashi Y, Mori K (2001) Kyphotic malalignment after anterior cervical fusion is one of the factors promoting the degenerative process in adjacent intervertebral levels. *Eur Spine J* 10: 320-324.
18. Ishihara H, Kanamori M, Kawaguchi Y, Nakamura H, Kimura T (2004) Adjacent segment disease after anterior cervical interbody fusion. *Spine J* 4: 624-628.
19. Iizuka H, Iizuka Y, Nakagawa Y, Nakajima T, Toda N, et al. (2006) Interlaminar



- bony fusion after cervical laminoplasty: its characteristics and relationship with clinical results. *Spine (Phila Pa 1976)* 31: 644-647.
20. Ratliff JK, Cooper PR (2003) Cervical laminoplasty: a critical review. *J Neurosurg* 98: 230-238.
21. Maeda T, Arizono T, Saito T, Iwamoto Y (2002) Cervical alignment, range of motion, and instability after cervical laminoplasty. *Clin Orthop Relat Res* 132-138.
22. Morio Y, Yamamoto K, Teshima R, Nagashima H, Hagino H (2000) Clinicoradiologic study of cervical laminoplasty with posterolateral fusion or bone graft. *Spine* 25: 190-196.
23. Baba H, Maezawa Y, Furusawa N, Imura S, Tomita K (1995) Flexibility and alignment of the cervical spine after laminoplasty for spondylotic myelopathy. A radiographic study. *Int Orthop* 19: 116-121.
24. Suk KS, Kim KT, Lee JH, Lee SH, Lim YJ, et al. (2007) Sagittal alignment of the cervical spine after the laminoplasty. *Spine (Phila Pa 1976)* 32: E656-660.
25. Wang MY, Green BA, Vitarbo E, Levi AD (2003) Adjacent segment disease: an uncommon complication after cervical expansile laminoplasty: case report. *Neurosurgery* 53: 770-772.
26. Takagi H, Kawaguchi Y, Kanamori M, Abe Y, Kimura T (2002) T1-2 disc herniation following an en bloc cervical laminoplasty. *J Orthop Sci* 7: 495-497.
27. Liu G, Buchowski JM, Bunmaprasert T, Yeom JS, Shen H, et al. (2009) Revision surgery following cervical laminoplasty: etiology and treatment strategies. *Spine (Phila Pa 1976)* 34: 2760-2768.
28. Ishida Y, Suzuki K, Ohmori K, Kikata Y, Hattori Y (1989) Critical analysis of extensive cervical laminectomy. *Neurosurgery* 24: 215-222.
29. Mikawa Y, Shikata J, Yamamuro T (1987) Spinal deformity and instability after multilevel cervical laminectomy. *Spine (Phila Pa 1976)* 12: 6-11.
30. Katsumi Y, Honma T, Nakamura T (1989) Analysis of cervical instability resulting from laminectomies for removal of spinal cord tumor. *Spine (Phila Pa 1976)* 14: 1171-1176.
31. Kurz LT, Herkowitz HN (1992) Surgical management of myelopathy. *The Orthopedic clinics of North America* 23: 495-504.
32. Guigui P, Benoist M, Deburge A (1998) Spinal deformity and instability after multilevel cervical laminectomy for spondylotic myelopathy. *Spine (Phila Pa 1976)* 23: 440-447.

Copyright: © 2014 Dohzono S, et al. This is an open-access article distributed under the terms of the Creative Commons Attribution License, which permits unrestricted use, distribution, and reproduction in any medium, provided the original author and source are credited.

Citation: Dohzono S, Konishi S, Terai H, Toyoda H, Suzuki A, et al. (2014) Compression Myelopathy Caused by Anterolisthesis and Hypertrophic Ligamentum flavum in the Adjacent Segment 11 years after Cervical Laminoplasty-A Case Report and Review of the Literature. *Global J Med Clin Case Reports* 1(1): 005-009. DOI: 10.17352/2455-5282.000002