

Krishna Sundeep A^{1*}, Durga Hari Prasad D¹, Varun P¹, Lalith Kumar P² and Ramakrishna Rao M³

¹Resident, Department of General Medicine, Rajah Muthiah Medical College, Annamalai, University, India

²Lecturer, Department of General Medicine, Rajah Muthiah Medical College, Annamalai, University, India

³Profesor, Department of General Medicine, Rajah Muthiah Medical College, Annamalai, University, India

Dates: Received: 22 June, 2014; Accepted: 26 August, 2014; Published: 28 August, 2014

*Corresponding author: Krishna Sundeep A, Resident, Department of General Medicine, Rajah Muthiah Medical College, Annamalai, University, India, E-mail: krishna.alap@yahoo.com

www.peertechz.com

ISSN: 2455-5282

Keywords: Chorea; Hyperglycaemia; Diabetes mellitus; Ischemia

Case Report

Chorea: Secondary to Non-Ketotic Hyperglycemia: A Case Report

Abstract

Chorea associated with non-ketotic hyperglycaemia is an uncommon dyskinetic syndrome in uncontrolled or undiagnosed diabetes. Various theories are postulated but the underlying mechanism remains poorly understood. We report a 70-year-old man suffering from sudden choreodystonic movements and undiagnosed hyperglycemia. It always marks the importance of screening for diabetes as a cause of acute onset of hyperkinetic disorders.

Urine ketones were negative and urine glucose 3+. Complete blood picture showing Total WBC count 10,700/cmm. Serum Osmolarity was 326 mosmol/kg. A non contrast CT Brain showed no evidence of any pathology.

The patient was diagnosed with non-ketotic hyperosmolar hyperglycemia secondary to previously undiagnosed diabetes mellitus, and he was admitted to the hospital for further management and work-up of dyskinesia. Patient was started on intermediate acting post-prandial insulin, along with short-acting pre-prandial insulin coverage. Random Blood sugar level improved to less than 200 mg/dL by hospital day two and corresponding improvement in dyskinetic movement. During the period of his stay in the hospital over 4 days, neurological symptoms had nearly resolved. The patient was transitioned to oral hypoglycemic agents without recurrence of choreic symptoms.

Discussion

Chorea (irregular, unpredictable, brief jerky involuntary movements) and hemballismus (ballistic flinging movements) could result from the number of causes namely, central nervous system infections, neoplasm, intracranial haemorrhage, neurodegenerative disorders, drugs, toxins, systemic disorders and metabolic imbalance

Introduction

Chorea associated with hyperglycemia is a rare dyskinetic syndrome usually characterised by unilateral involuntary movements in uncontrolled or undiagnosed diabetes. Hyperosmolar hyperglycemic non-ketotic (HHNK) syndrome is a clinical syndrome of severe hyperglycemia, hyperosmolarity, and intracellular dehydration without ketoacidosis [1]. "Chorea is mostly seen in elderly patients with type 2 diabetes and has a better resolution of symptoms after glycaemia control, although persistent symptoms have been reported [2]".

Case Report

70 year old gentleman without any significant past medical history, presented to our emergency department with chief complaints of involuntary left arm and leg movement with associated slurring of speech for 5 days. The movements started suddenly, remitted during sleep, but were otherwise constant and progressively worsening. Upon review of his physical condition, the patient also noted the recent onset of polyuria and polydipsia. He denied significant past medical history, and denied a family history of Huntington's chorea or other neurological disorder. Neurological examination revealed oculogyric crisis, orofacial dyskinesia, asymmetric axial and limbs left choreic movements with superimposed dystonic left-posturing of the neck muscle tone and strength. Deep tendon reflexes and sensation are intact and mental status within normal limits.

In the emergency department, serum glucose was elevated at 405 mg/dL. Glycosylated hemoglobin A1C was significantly elevated at 12.7%. FBS > 140 and PPBS > 200 in the initial period which gradually decreased to FBS < 110 and PPBS < 160 on Insulin therapy over a period of 4 days. An Arterial blood gas showing pH 7.45 and HCO₃ 18mmol/L. BUN was 32mg/dL. Serum was negative for ketone bodies.

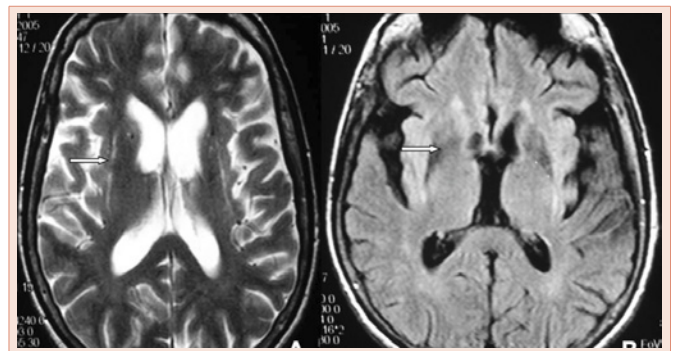


Figure 1: MRI revealed A) T1 hyperintense signal abnormality and minimal enhancement of the Right putamen. B) Hypointensity in the same region was demonstrated on FLAIR and T2-weighted.

[3]. Hyperglycaemic state associated chorea was first described by Bedwell in 1960 [3]. An exact mechanism behind the described phenomenon remains unclear, although a small number of theories have been proposed. It has been suggested that the presence of serum hyperosmolarity and hyperglycemia induces mild ischemia in the putamen via hypoperfusion. This theory is supported by a case series reporting caudate and putamen hypoperfusion on SPECT imaging in ten patients with hyperglycemia induced chorea [4]. Hyperglycemia creates an energy state at the cellular level favoring anaerobic metabolism, which in turn depletes gamma-aminobutyric acid (GABA), due to the fact that acetoacetate, a GABA substrate, is quickly depleted in the anaerobic state [5]. It is plausible that depletion of GABA can contribute to the development of chorea via its interaction with dopamine. GABA acts to inhibit dopaminergic neurons in the nigrostriatal system, therefore the hyperglycemia-induced inhibition of GABA may create a hyperactive dopaminergic state, giving rise to the onset of choreic movements.

Conclusion

Hyperglycemia is an uncommon but reversible treatable cause

of chorea. "Checking blood glucose is necessary whenever an elderly patient presents with the new onset hyperkinesias as fluid management and Blood sugar level monitoring can lead to rapid and complete recovery".

References

1. Qi X, Yan Y, Gao Y, Zheng Z, Chang Y (2012) Hemichorea associated with non-ketotic hyperglycaemia: a case report. *Diabetes Res Clin Pract* 95: e1-e3.
2. Oh SH1, Lee KY, Im JH, Lee MS (2002) Chorea associated with non-ketotic hyperglycemia and hyperintense basal ganglia lesion on T1-weighted brain MRI study: a meta-analysis of 53 cases including four present cases. *J Neurol Sci* 2013: 57-62.
3. Bedwell S (1960) Some observations on Hemiballismus. *Neurology* 2013: 619-622.
4. Nagai C, Kato T, Katagiri T, Sasaki H (1995) Hyperintense putamen on T1-weighted MR images in a case of chorea with hyperglycemia. *AJNR Am J Neuroradiol* 16: 1243-1246.
5. Lin J, Chang MK (1994) Hemiballismus-hemichorea and non-ketotic hyperglycaemia. *J Neurol Neurosurg Psychiatry* 57: 748-750.

Copyright: © 2014 Krishna Sundeep A, et al. This is an open-access article distributed under the terms of the Creative Commons Attribution License, which permits unrestricted use, distribution, and reproduction in any medium, provided the original author and source are credited.

Citation: Krishna Sundeep A, Durga Hari Prasad D, Varun P, Lalith Kumar P, Ramakrishna Rao M (2014) Chorea: Secondary to Non-Ketotic Hyperglycemia: A Case Report. *Global J Med Clin Case Reports* 2(1): 025-026. DOI: 10.17352/2455-5282.000008