

Chatzistamatyoy EI<sup>1\*</sup>, Moustakas GN<sup>2</sup>,  
Avgeropoulou C<sup>1</sup>, Androulakis A<sup>1</sup>,  
Tousoulis D<sup>3</sup> and Kallikazaros IE<sup>1</sup>

<sup>1</sup>Cardiology Department, Hippocraton Hospital,  
Athens, Greece

<sup>2</sup>Cardiology Clinic, Sismanoglo Hospital, Athens,  
Greece

<sup>3</sup>First Cardiology Clinic, University of Athens,  
Hippocraton Hospital, Athens, Greece

**Dates:** Received: 20 July, 2015; Accepted: 12  
October, 2015; Published: 16 October, 2015

\*Corresponding author: Evangelos I  
Chatzistamatyoy, Kaisareias street, Nr. 6,  
Ampelokipoi, P.B: 11527, Athens Greece, Tel:  
+306937433637; E-mail: vagelisdoc@hotmail.com

[www.peertechz.com](http://www.peertechz.com)

ISSN: 2455-5282

## Case Report

# Middle Aortic Syndrome: A Case Report and Review of the Literature

The patient had a positive familial history for hypertension by both parents. She reported normal birth weight, but her's mother age at the time of delivery was only 13 years old. Her personal medical history was negative for sleep disturbances or intake of any substances and medications that increase BP levels. Moreover, she was never smoker, with reported three abortions at a young age, low salt consumption and physically active (intense aerobic exercise at a regular basis).

The physical examination demonstrated that the patient was in good condition with normal body adiposity (BMI 22.5 kg/m<sup>2</sup>, waist circumference 76 cm). Both the office systolic and diastolic blood pressures and heart rate were in the normal range in both arms (mean 125/75 mmHg, 65 bpm). Complete clinical evaluation was negative for signs and symptoms suggestive of secondary forms of hypertension, except slightly diminished and delayed femoral pulses.

Twelve-lead resting ECG revealed sinus rhythm at 70 bpm, normal electrical axis at 75°, without signs of atrial enlargement, LV hypertrophy or ST-T wave abnormalities (Sokolow-Lyon index: 2.2 mV). Blood and 24hour urine collection tests were negative for endocrine hypertension. Fasting plasma glucose was 96 mg/dl, LDL-Cholesterol: 120 mg/dl, HDL-Cholesterol: 67 mg/dl, triglycerides: 76 mg/dl, eGFR: 91.5 ml/min/ 1.73m<sup>2</sup> and Albumin to Creatinine ratio: 4.41 mg/gr.

Despite that 24hour ambulatory blood pressure monitoring presented normal BP values during the day (128/69 mmHg) and night (104/56 mmHg), serial home BP measurements during several weeks were abnormal (morning 140/75 mmHg, evening 150/80 mmHg), setting the diagnosis of masked essential hypertension stage 1.

Fundoscopy examination revealed beading of the middle and distal portion of the retinal veins, without clear evidence of hypertensive signs (Figure 1). Symptom-limited maximal treadmill exercise test with Bruce protocol was negative for ischemia. The duration of exercise was 8'30'' (10 METS), BP and heart rate rose to 200/90 mmHg and 164 bpm, respectively. Conventional and Tissue Doppler echocardiographic study was normal: Ascending thoracic aorta was 3.2 cm, Left atrial volume index was 19 cm<sup>3</sup>/m<sup>2</sup>, and Left ventricular mass index was 60.7 gr/m<sup>2</sup>, Ejection fraction=65%, Transmitral E/A=1.42, TDI basal lateral E'=11 cm/sec and A'=7 cm/sec.

Central aortic stiffness was evaluated by Sphygmocor device using intersecting tangent algorithm and substructed path length method. Both indices, carotid-femoral Pulse Wave Velocity and Augmentation Index were normal (6.5 m/sec and 36%, respectively). Carotid ultrasound, unexpectedly, revealed diffusely increased Intima Media Thickness of the carotid artery wall (bilaterally mean 1.1-1.2 mm) and presence of two discrete isoechogenic plaques

## Introduction

Coarctation of the aorta is a relatively common defect that accounts for 5-8% of all congenital heart defects and is characterized by discrete medial thickening with superimposed neointimal tissue, leading to aortic lumen narrowing of different degrees.

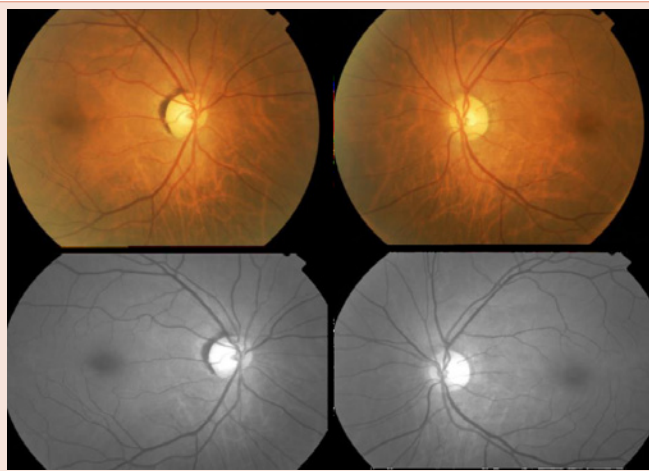
Today's knowledge is that the majority of lesions are juxtaductal, with the classic coarctation located in the thoracic aorta distal to the origin of the left subclavian artery at about the level of the ductal structure [1]. However, a coarcted segment may be present in the distal descending thoracic or abdominal aorta and is referred as Middle Aortic Syndrome (MAS). This entity is extremely rare, representing only 0.5-2% of all aortic coarctation cases [2], with total number of published patients not exceeding three hundred. Congenital, acquired, inflammatory, and infectious etiologies have been proposed.

Regardless of the location, long lasting coarctation increases significantly wall stress of the left ventricle and arterial tree proximal to stenosis, leading to ventricular hypertrophy, heart failure, reactive vascular hypertrophy and premature atherosclerosis. Moreover, hypoperfusion distal to stenosis may lead to renal, visceral and lower limb ischemia [3].

We present a case of a middle aged woman with asymptomatic congenital thoraco-abdominal aortic dysplasia, newly discovered mild hypertension and premature carotid atherosclerosis.

## Case report

A 55-year old white female, civil servant, postmenopausal the last 5 years, without hormone replacement therapy was admitted to our antihypertensive unit with a three month history of newly discovered, stage 1, systemic hypertension. In the coming weeks systematically monitored the values of BP and found that morning measurements ranged to 140/75 mmHg and evening measurements to 145-150/75 mmHg. She has occasionally complained of headache and dizziness.



**Figure 1:** Fundoscopic examination reveals beading of the middle and distal portion of the retinal veins, without clear evidence of hypertensive signs.

at the level of right and left bulb, causing 30% and 15% stenosis, respectively (Figure 2). Moreover, lower extremity arterial circulation as assessed both with a handheld continuous Doppler device and duplex ultrasound, revealed that both legs presented impaired Ankle Brachial Index values (right 0.74 and left 0.70), despite that imaging of the arterial wall exhibited normal IMT and complete absence of plaques. However, Doppler interrogation of the right and left iliac and femoral arteries revealed monophasic velocity patterns (Parvus et Tardus), consistent with hemodynamically significant stenosis proximal to the level of measurement (Figure 3).

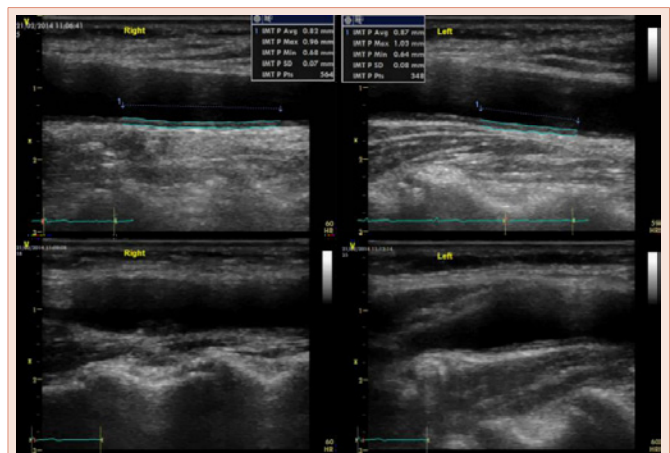
Ultrasonographic examination of abdominal aorta and its main branches was performed in order to evaluate the aforementioned stenosis. Abdominal aorta presented two parallel lumens, with reduced diameters (anterior lumen 0.8 cm and posterior lumen 0.5 cm in diameter), and monophasic velocity patterns. We were unable to ultrasonographically determine the origin of the renal arteries from the two abdominal aortic lumens. However, both kidneys presented normal dimensions and normal sonographic morphology. Intrarenal Doppler velocity waveforms exhibited slightly impaired profile, with disappearance of early peak systolic velocity and increased acceleration time, while intrarenal resistive indexes were bilaterally equal and normal: 0.6 (Figure 4). At the epigastrium we have recorded an increased peak systolic velocity (2 m/sec), but further sonographic assessment of the descending thoracic aorta was impossible due to rib cage limitations. So the patient was referred to Magnetic Resonance Aortography (MRA), which revealed that the descending thoracic aorta, at the level of pillars of diaphragm, presented an elongated stenosis, 2.9 cm, with the lumen diameter not exceeding 0.90 cm. At the level of aortic hiatus emerged left renal artery, which following a tortuous course entered to the left kidney. Just distal to this stenosis abdominal aorta was divided in two secondary branches, the anterior one with a diameter 0.5 cm and the posterior one with a diameter 0.35 cm. From the anterior branch emerged right renal, celiac and superior mesenteric arteries. The posterior branch progressively increased its diameter reaching 1.3 cm immediately before the abdominal aorta bifurcation. From the distal part of posterior branch emerged a

supernumerary left renal artery and another arterial branch, which following an ascending course, ended to mesentery (Figure 5).

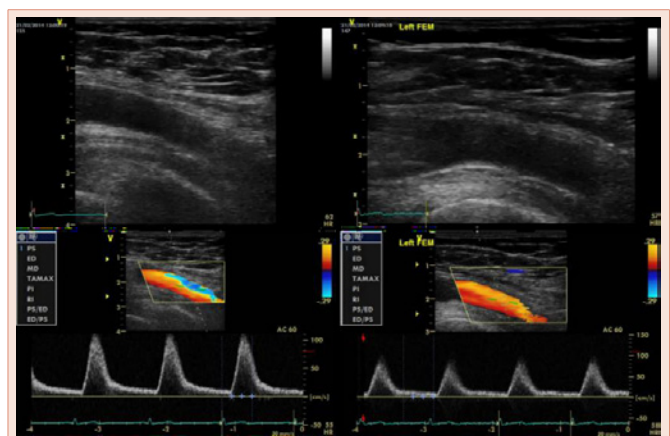
Moreover, MRA of intracranial vessels revealed supply of the left posterior cerebral artery by left posterior communicating artery, hypoplasia of the right posterior communicating artery and asymmetry of posterior inferior cerebellar arteries.

The patients was treated initially with manidipine 20 mg once a day. Because of poor blood pressure control we considered appropriate to switch to a fixed double combination with valsartan 160 mg and amlodipine 5 mg once a day, with normalization of upper arm blood pressure and without deterioration of renal function. Moreover, considering the carotid findings and despite that the patient had a low cardiovascular risk profile, with a calculated HeartScore of 0%, we felt appropriate to initiate atorvastatin at a dose of 10 mg once a day, with the purpose to reduce further her actual cardiovascular risk.

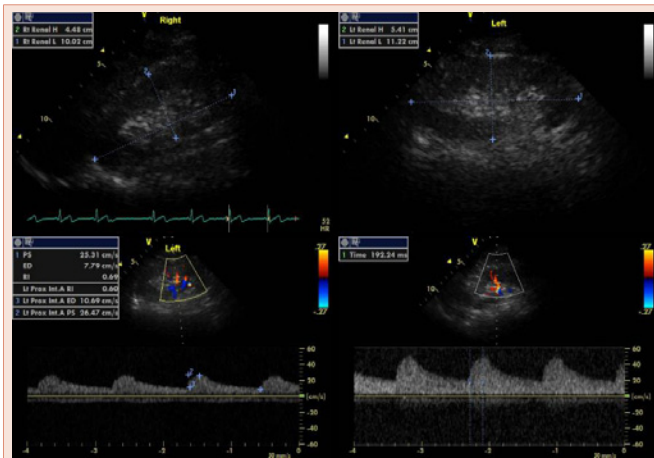
### Discussion



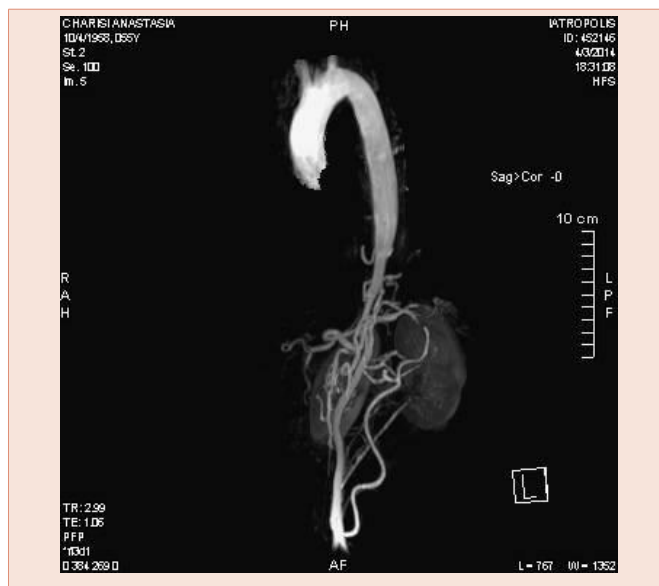
**Figure 2:** Carotid ultrasound showing IMT thickening and presence of carotid plaques.



**Figure 3:** Femoral ultrasound showing normal IMT and absence of plaques despite monophasic flow velocity profile.



**Figure 4:** Renal ultrasound showing normal 2D appearance and slightly impaired intrarenal Doppler profile, with disappearance of early peak systolic velocity and increased acceleration time.



**Figure 5:** MR Aortography showing dysplasia of the thoraco-abdominal aortic segment.

Middle aortic syndrome (MAS) refers to segmental narrowing of the descending thoracic and/or abdominal aorta. The first descriptions of severely hypoplastic descending thoracic and abdominal aorta made by Schlessinger in 1835 and Quain in 1847, respectively [4,5]. Until 2005 only 200 cases have been reported in the literature [6,7].

MAS may be congenital or acquired. Congenital coarctation of the thoraco-abdominal aorta is a nonhereditary luminal narrowing, spanning several centimeters in length or as a sharp, web-like constriction, affecting men two to three times as often as women. The etiology of this condition is unknown. Response mechanisms to inflammation or infection during early fetal life, such as infection of the mother by rubella virus, can interfere with cell growth and development of aorta [8]. Embryologically, the two dorsal aortas

are partly fused in the human embryo about the fourth week of fetal life. Shortly after this, they fuse completely, forming a single blood channel. Incomplete fusion can result in an aorta which is divided longitudinally into two channels (with obliteration and loss of one of them), while over fusion can result in a severely narrowed single aorta [9]. The double-channel aorta we found in our patient provide evidence of this theory. So far, only a few patients with double-channel aorta and less than 20 patients with involvement both of the thoracic and abdominal parts have been reported [10-13].

Thoraco-abdominal congenital aortic coarctation may occur as a sole structural anomaly, but in up to 75% of cases is associated with other defects, including a patent ductus arteriosus, bicuspid aortic valve, atrial or ventricular septal defects, cerebral aneurysms or variations of the circle of Willis, and stenosis of renal and visceral arteries.

Acquired coarctation of the thoraco-abdominal aorta can be associated with arteritides (Takayasu, giant cell, temporal), mucopolysaccharidosis, retroperitoneal fibrosis or atherosclerosis [14]. However little evidence exists of an inflammatory process in most cases. Absence of any obvious inflammatory or atherosclerotic changes favor a developmental defect.

Natural bypass of the aortic constriction is accomplished by development of collateral network from branches of the subclavian, internal mammary, intercostals, superior mesenteric and axillary arteries, to the inferior mesenteric, lower intercostal and lumbar arteries, the inferior epigastric branches of the femoral arteries and the superior hemorrhoidal pathways via the marginal artery of Drummond and arc of Riolan [15].

MAS according to the location - extent of aortic stenosis and its involved branches, is classified in four subtypes: a) suprarenal, b) inter-renal, c) infrarenal and d) diffuse type, with/without renal artery involvement and with/without post-stenotic aneurysm [16-19]. According to one of the largest reported series with abdominal aortic coarctation (119 patients), the most frequent location was inter-renal (52%), followed by infrarenal (25%), diffuse (12%) and suprarenal (11%), while renal and visceral arteries involvement was observed in 80% and 22%, respectively [20].

Timing and severity of clinical manifestations depends on the grade of aortic stenosis, extent of branches involved and developed collateral circulation by-passing aortic stenosis. Congenital MAS cause symptoms usually in early adulthood, although it can be manifested at any age, as in the case of our middle-aged patient. Symptoms and complications derive from hemodynamic disturbances both proximal and distal to coarctation. The cardinal finding of upper body arterial hypertension is a result of mechanical obstruction to flow, maladaptive arterial remodeling and altered renal glomerular perfusion. Specifically, in bilateral renal artery involvement, as in the case of suprarenal coarctation, intravascular volume increases via the effect of aldosterone on sodium and water retention, such that hypertension is maintained by volume expansion, while renin secretion is turned off via negative feedback [21,22]. However, in the case of infrarenal aortic stenosis renal glomerular hypertension leads to systemic hypertension via activation of renin angiotensin system.

Patients typically presents with uncontrolled hypertension in the upper half of the body with hypotension in the lower extremities,

visceral ischemia or intermittent claudication in the first decades of life and are at increased risk for coronary, aortic and cerebrovascular events. Longstanding uncontrolled hypertension may cause headache that is often localized to the occipital region and is worse when the patient wakes in the morning and subsides later in the day, dizziness, palpitations, fatigability, epistaxis and blurred vision [23].

In severe long-lasting MAS the lower extremities are notably underdeveloped with markedly delayed pulses. Physical signs include cardiac murmurs, mid systolic abdominal bruits, continuous bruits from the collateral vessels auscultated in the left loin, the back, and the thorax, and palpable collateral arteries in the intercostal spaces, the axilla, and the interscapular area.

Anatomic configuration and aortic narrowing can be visualized with proper imaging techniques. Doppler ultrasonography represents an excellent diagnostic tool which may reveal not only the localized aortic stenosis, but even so its hemodynamic consequences, proximal and distal to stenosis, as it was presented in our case.

Aortography has been the diagnostic test of choice in the past. In recent years multidetector CT angiography (CTA) and magnetic resonance angiography (MRA) have become the primary tools for the evaluation of patients with suspected aortic abnormalities.

Abdominal coarctation needs to be surgically corrected when associated with aneurysmal degeneration, aortoiliac occlusive disease or severe hypertension. Endovascular treatment is a less invasive alternative to open surgical repair for selected patients. The operation must be individualized on the basis of the location of narrowing and associated renal or visceral artery involvement. In case of long hypoplastic segments, bypass grafting around the narrowed segment is the most appropriate alternative [24]. Average age of death was reported 30 years in patients who were managed medically [25]. Cohen et al reported that most patients with abdominal aortic coarctation died by age 35 as a result of complications [26]. However in our case mild hypertension without any sign of occlusive disease or aneurysmal dilatation was treated conservatively.

In conclusion, any young patient, even with mild hypertension should be evaluated for aortic coarctation. This condition can be strongly suspected on the basis of careful physical examination. Upper and lower extremities blood pressure measurement must be a part of initial physical examination in all hypertensive patients. Imaging modalities and especially ultrasonography are very accurate in localizing aortic coarctation and altered proximal and distal arterial circulation [27].

## References

- Brickner ME, Hillis LD, Lange RA (2000) Congenital heart disease in adults. First of two parts. *N Engl J Med* 342: 256-263.
- Connolly J, Wilson SE, Lawrence PL, Fujitani RM (2002) Middle aortic syndrome: distal thoracic and abdominal coarctation, a disorder with multiple etiologies. *J Am Coll Surg* 194: 774-781.
- Campbell M (1970) Natural history of coarctation of the aorta. *Br Heart J* 32: 633-640.
- Schlessinger W (1835) Merkwürdige verschkiessung der aorta. *Wenscher ges. Helikund* 31: 849-850.
- Quain R (1847) Partial contraction of the abdominal aorta. *Trans Path Soc London* 1: 244-246.
- Delis KT, Gloviczki P (2005) Middle aortic syndrome: from presentation to contemporary open surgical and endovascular treatment. *Perspect Vasc Surg Endovasc Ther* 17: 187-203.
- Matsuno Y, Mori Y, Umeda Y, Imaizumi M, Takiya H (2009) A successful case of ascending aorta--abdominal aorta bypass for middle aortic syndrome. *Vasc Endovascular Surg* 43: 96-99.
- Siassi B, Kylman G, Emmanouilides GC (1970) Hypoplasia of the abdominal aorta associated with rubella syndrome. *Am J Dis Child* 120: 476-479.
- Arnot RS, Louw JH (1973) The anatomy of the posterior wall of the abdominal aorta. Its significance with regard to hypoplasia of the distal aorta. *S Afr Med J* 47: 899-902.
- Calhoun TR, Thumwood RG, Tennyson KB, Wright RM, Kitten CM, et al. (1983) Coarctation of the abdominal aorta. *Texas Heart Inst J* 10: 269-273.
- Patel J, Facquet J (1953) Essais de cure des sténoses ectopiques de l'aorte. *Presse Med* 61: 743-744.
- Mickley V, Fleiter T (1998) Coarctations of descending and abdominal aorta: long-term results of surgical therapy. *J Vasc Surg* 28: 206-214.
- Bergamini TM, Bernard JD, Mavroudis C, Backer CL, Muster AJ, et al. (1995) Coarctation of the abdominal aorta. *Ann Vasc Surg* 9: 352-356.
- Taketani T, Miyata T, Morota T, et al. (2005) Surgical treatment of atypical aortic coarctation complicating Takayasu's arteritis: experience with 33 cases over 44 years. *J Vasc Surg* 41: 597-601.
- Koksal C, Demirci S, Koksal GM, Zengin M (2005) An infrarenal abdominal aortic coarctation. *Surg Radiol Anat* 27: 71-73.
- Graham LKM, Zelenock GB, Erlandson EE, et al. (1979) Abdominal aortic coarctation and segmental hypoplasia. *Surgery* 86: S19-529.
- Hallett JW Jr, Brewster DC, Darling RC, et al. (1980) Coarctation of the abdominal aorta: current options in surgical management. *Ann Surg* 191: 430-437.
- Mickley V, Fleiter T (1998) Coarctations of descending and abdominal aorta: long-term results of surgical therapy. *J Vasc Surg* 28: 206-214.
- Robicsek F, Daugherty HK, Cook JW, Cafoncelli A (1980) Coarctation of the abdominal aorta with stricture of the major vessels. *Surgery* 87: 545-548.
- Graham LM, Zelenock GB, Erlandson EE, Coran AG, Lindenauer SM, et al. (1979) Abdominal aortic coarctation and segmental hypoplasia. *Surgery* 86: 519-529.
- Mickley V, Fleiter T (1998) Coarctations of descending and abdominal aorta: long-term results of surgical therapy. *J Vasc Surg* 28: 206-214.
- Seddon M, Saw J (2011) Atherosclerotic renal artery stenosis: review of pathophysiology, clinical trial evidence, and management strategies. *Can J Cardio* 27: 468-480.
- Ilica AT, Bilici A, Ilhan A, Kara M, Gür S (2007) Thoracoabdominal aorta coarctation with bilateral renal artery involvement: diagnosis with multidetector CT angiography (MDCTA). *Int J Cardiovasc Imaging* 23: 645-648.
- Terramani TT, Salim A, Hood DB, Rowe VL, Weaver FA (2002) Hypoplasia of the descending thoracic and abdominal aorta: a report of two cases and review of the literature. *J VascSurg* 36: 844-848.
- Bjork VO, Intonti F (1964) Coarctation of the abdominal aorta with right renal artery stenosis. *Ann Surg* 160: 54-60.
- Cohen JR, Birnbaum E (1998) Coarctation of the abdominal aorta. *J VascSurg* 8: 160-164.
- Baykan A, Argun M, Ozyurt A, Pamukçu O, Uzüm K, et al. (2013) Hypertension associated with coarctation of the aorta revisited: case-based update from experience of three children. *Case Rep Pediatr* 2013: 716438.

**Copyright:** © 2015 Chatzistamatoy EI, et al. This is an open-access article distributed under the terms of the Creative Commons Attribution License, which permits unrestricted use, distribution, and reproduction in any medium, provided the original author and source are credited.

**Citation:** Chatzistamatoy EI, Moustakas GN, Avgeropoulou C, Androulakis A, Tousoulis D, et al. (2015) Middle Aortic Syndrome: A Case Report and Review of the Literature. *Global J Med Clin Case Reports* 2(1): 013-016. DOI: 10.17352/2455-5282.000019