

Nandini Chatterjee¹ and Chandan Chatterjee^{2*}

¹Department of General Medicine. IPGMER and SSKM Hospital, Kolkata-700020, India

²Department of Pharmacology. ESI Medical College and Hospital, Joka, Kolkata 700104, India

Received: 06 December, 2018

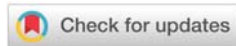
Accepted: 17 December, 2018

Published: 18 December, 2018

***Corresponding author:** Chandan Chatterjee, Department of Pharmacology, 358, N S C Bose Road, Surjasarathi Apartment, Kolkata 700047, India, Tel: 9830271671; E-mail: rivuc2006@gmail.com

Keywords: Essential hypertension; Adenoma; Parathyroid

<https://www.peertechz.com>



Case Report

Parathyroid adenoma—An incidental diagnosis

Abstract

A 50 year old man was referred to us with inadequate control of blood pressure for last few years. He was being treated as a case of essential hypertension on a four drug regime. Subsequent work up led to the diagnosis of primary hyperparathyroidism due to left sided parathyroid adenoma.

11 mg/dl, 3.3 mg/dl and 3.8 mg/dl respectively. 24 hour urinary calcium was 480 mg/day (normal < 300mg/day) Immediately serum parathyroid level was sent for and it came out to be 234.2 pg/ml (15–65 pg/ml). Tc 99m sestamibi subtraction scan showed focal uptake of radiotracer just distal to the inferior pole of the left lobe of thyroid gland consistent with a left inferior parathyroid adenoma. He underwent surgical excision after which he is doing well on one drug.

Discussion

The patient presented at the fifth decade— thus secondary hypertension was not thought of at the beginning. For years his antihypertensive doses were escalated without much result. The detection of renal calcifications were a pointer to diagnosis. Metastatic calcifications are due to deposition of calcium salts in normal tissues. Common sites involved are walls of blood vessels, peri-articular areas, skin, soft tissues and viscera notably lung, heart, kidney, intestine and brain.

Essentially a disbalance of calcium and phosphate homeostasis plays the key role in pathogenesis of this state [2]. The increased calcium-phosphate product has been proposed as the determining factor. In primary hyperparathyroidism though phosphate is initially low, progressive renal impairment may later contribute to raise calcium phosphate product metabolism [2,3].

It has been documented that serum phosphate > 8–9mg/dl and / or calcium phosphate product >70 mg/dl, local tissue injury, increased parathormone level - all contribute to heterotopic calcification [2,4].

The mechanism of high BP in hyperparathyroidism is controversial. Plasma cortisol and plasma renin activity were found to be higher in hypercalcemic states but plasma cortisol

Introduction

Parathyroid related disorders have a whole gamut of clinical presentations.

56–80% of cases have increased blood pressure as well as target organ damage. However, primary hyperparathyroidism is an uncommon endocrine cause of hypertension, prevalence being less than 0.01% [1].

Case Report

A 50 year old man presented with hypertension for the last ten years. The patient was on medication but had inadequate control of blood pressure .He was otherwise asymptomatic except some vague complaints of body ache and occasional abdominal pain that was largely overlooked so far. On examination, he had average build, weight- 55kg there was absence of pallor, jaundice, edema, cyanosis or clubbing. B P was 150/90 mm Hg. Examination of respiratory, neurological, and gastrointestinal systems were essentially normal.

Investigations revealed a normal complete hemogram, blood urea 34 mg/dl creatinine 1.5 mg/dl, fasting blood sugar 87 mg/dl, serum sodium 139 meq/l, potassium 3.8 meq/l. USG KUB showed calcifications in the pyramids of both kidneys. Kidney size and cortical echo pattern as well as thickness were normal. The detection of renal calcifications prompted us to perform serum calcium, phosphate and magnesium. The results were

and catecholamines were found to be normal [1]. Endothelial dysfunction with decreased NO, stiffness of great arteries, and increased responsiveness to vasoconstrictors and TGF B1 have been put forward as hypotheses [5-7].

However it has been documented that simple surgery of adenoma leads to control of BP which was also demonstrated in our case.

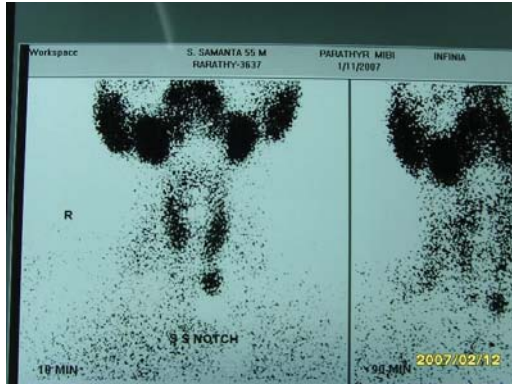


Figure 1: Photograph shows Tc99m sestamibi subtraction scan revealing focal increased uptake just distal to the inferior pole of the left lobe of thyroid gland consistent with an inferior parathyroid adenoma.

References

- Rossi GP (2011) Hyperparathyroidism, arterial hypertension and aortic stiffness: A possible bidirectional link between the adrenal cortex and the parathyroid glands that causes vascular damage? *Hypertension Research* 34: 286–288. [Link: https://goo.gl/6c5LUu](https://goo.gl/6c5LUu)
- Chakrabarti N, Chattopadhyay C (2010) Dysparathyroidism: A clinical window. *Ann Saudi Med* 30: 497-498. [Link: https://goo.gl/Co83Jc](https://goo.gl/Co83Jc)
- Valdivielso P, Lopez J, Garrido A, Sanchez Carrillo JJ (2006) Metastatic calcification and severe hypercalcemia in a case of parathyroid carcinoma. *J Endocrinol Invest* 29: 641-644.
- Martin KJ, Gonzalez EA, Slatopolsky E (2004) *Renal Osteodystrophy*, Ed Brenner B M. 7th edition, Saunders 2255-2304.
- Martina V, Bruno GA, Brancaloni V, Zumpano E, Tagliabue M, et al. (1998) Calcium blood level modulates endogenous nitric oxide action: effects of parathyroidectomy in patients with hyperparathyroidism. *J Endocrinol* 156: 231–235. [Link: https://goo.gl/Y2qM8g](https://goo.gl/Y2qM8g)
- Tordjman KM, Yaron M, Izhakov E, Osher E, Sherkerman G, et al. (2010) Cardiovascular risk factors and arterial rigidity are similar in asymptomatic normocalcemic and hypercalcemic primary hyperparathyroidism. *Eur J Endocrinol* 162: 925–933. [Link: https://goo.gl/wt1x26](https://goo.gl/wt1x26)
- Chhokar VS, Sun Y, Bhattacharya SK, Ahokas RA, Myers LK (2005) Hyperparathyroidism and the calcium paradox of aldosteronism. *Circulation* 111: 871–878. [Link: https://goo.gl/Rj3Wt8](https://goo.gl/Rj3Wt8)